DOI: 10.2478/v10249-011-0031-y

Risk of a second cutaneous primary melanoma and basal cell carcinoma in patients with a previous primary diagnosis of melanoma: true impact of dermoscopy follow-up in the identification of high-risk persons

Irdina DRLJEVIĆ*, Faruk ALENDAR

Clinic of Dermatology and Venereology, University of Sarajevo, Clinical Center of Sarajevo, Bosnia and Herzegovina
*Correspondence: Irdina DRLJEVIĆ, E-mail: anida1@bih.net.ba

UDC 616.5-006.8-076:004.7

VERSITA

Abstract

In clinical practice, positive personal history is considered to be as an indication of increased melanoma risk. The thickness of melanoma (Breslow Index) is the most important independent predicting factor of survival for stage I patients. We present a case of a second primary melanoma and basal cell carcinoma in a 48-year-old female patient with personal history of a superficial spreading melanoma located at the dorsal trunk with Breslow's thickness of 0,5 mm and Clark's II (stage IA) excised a year before, and a family background of melanoma. We would like to emphasize the benefits of digital dermatoscopy as well as teledermoscopy, and new teledermatology web services, in the follow-up of high-risk patients.

Key words

Melanoma; Neoplasms, Second Primary; Dermoscopy; Lymph Nodes; Carcinoma, Basal Cell; Telemedicine; Follow-up Studies

Telemedicine, or distance medicine, represents a rapidly growing sector in clinical medicine. It is the process of using audio and video communications to convey or exchange medical for information the purpose of consulting and sometimes for remote medical procedures or examinations. Telemedicine is practiced on the basis of two concepts: real time (videoconferences) and store-and-forward, that is synchronous and asynchronous telemedicine (1). In teledermatology the second concept is mainly used because it is less time-consuming and has lower costs (2).

Dermoscopy (also known as epiluminescence microscopy, dermatoscopy, and amplified surface microscopy) is an *in-vivo* diagnostic procedure used for visualization of skin structures that cannot be seen by the naked eye and for classification of lesions as melanocytic or non-melanocytic (3). The main role of dermoscopy is early detection of melanoma, vital for its proper treatment (4,5).

Case report

We present a 48-year-old female patient with personal history of superficial spreading melanoma located at the dorsal trunk with Breslow thickness of 0,5 mm and Clark level II (stage IA) excised a year before, and a family background of melanoma. The patient was admitted due to a new pigmented lesion on the left thigh detected six months before. The patient noticed a progressive increase in size and changes in color.

Clinical examination revealed skin type I, without increase in the number of moles (< 25), but some solar lentigo in exposed areas, especially on the upper back. The scar of the previous surgery of the primary melanoma and lymph node areas were normal.

© 2009 The Serbian Association of Dermatovenereologists

The tumor was 10.5x12 mm in maximal diameter and more palpable in the center. The lesion exhibited light brown, dark brown to black, and gray colors (Figure 1).

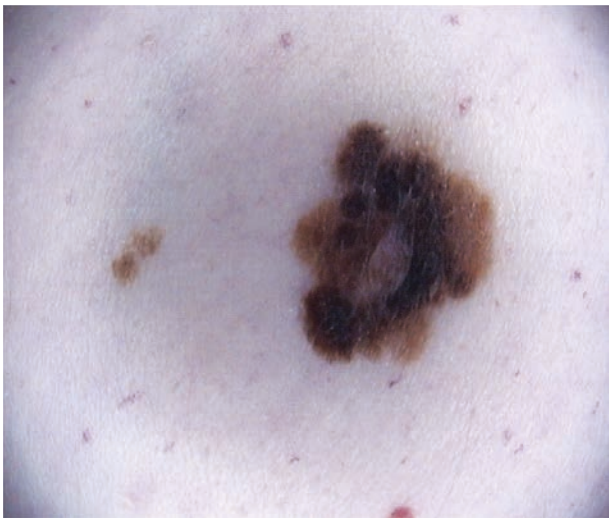

Figure 1. Superficial spreading melanoma on the left thigh

Dermoscopy of the lesion showed a melanocytic lesion with the following features: atypical pigmented network, irregular streaks, globules/dots, and blotches, and a homogeneous hypopigmented center (Figure 2).

The second tumor was 1.5x0.9 mm in maximal diameter, and it was located on the right scapular region (Figure 3). A solitary flat lesion was slightly palpable, light-brown to reddish in color.

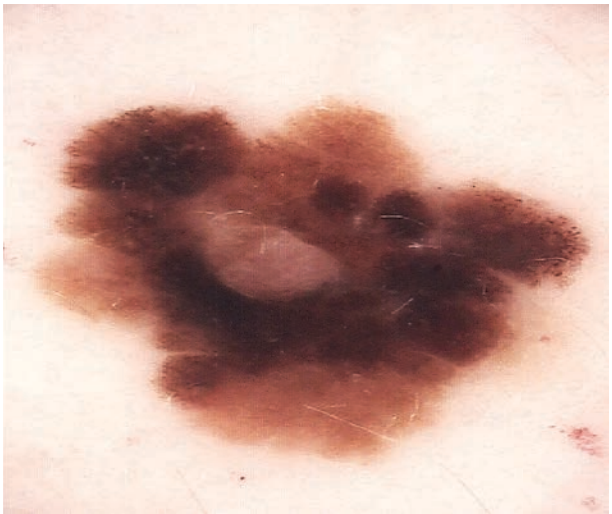

Figure 2. Dermoscopy of superficial spreading melanoma on the left thigh

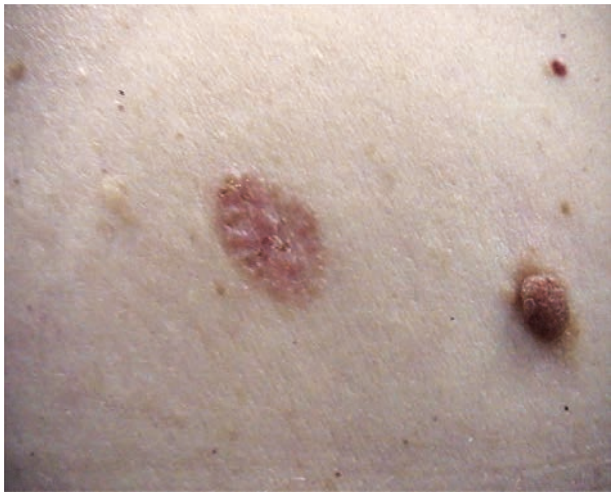

Figure 3. Basal cell carcinoma in the right scapular region

Dermoscopy revealed a negative pigment network with thin arborizing vessels in the center of the lesion, and a few small ulcers covered by light brown crusts (Figure 4).



Figure 4. Dermoscopy of basal cell carcinoma in the right scapular region

Management

A full surgical removal of the tumor, with 2 mm margins, under local anesthesia was performed to evaluate the tumor histologically. A superficial spreading melanoma (SSM), Breslow 1 mm, Clark level III, without ulcerations and abundant lymphocytic inflammatory infiltrate with five mitoses/10 High

© 2009 The Serbian Association of Dermatovenereologists

Power Fields (HPF) was reported. Reexcision was done with 10 mm margins (6), and sentinel lymph node biopsy revealed a negative sentinel node on the left thigh without micro-metastases. The patient was staged IA, based on the American Joint Committee on Cancer (AJCC) staging system (7). A follow-up with clinical examination (skin and lymph nodes), including digital dermoscopy, was recommended with 3 to 6 months between each visit.

A surgical excision under local anesthesia was also performed for the second lesion to evaluate the tumor histologically. A basal cell carcinoma - pT1 (Stage I, primary tumor) 2cm or less in diameter, according to the TNM Classification of Malignant Tumors (available at www.uicc.org/index.php?id=508.) located at the scapular region was reported.

Discussion

Melanoma is a malignant tumor of melanocytes, and it affects all age groups. It is most common in Australia, but the mortality rate for melanoma is quite low compared to other countries (8). Early detection of melanoma followed by appropriate treatment, has led to a significant reduction in melanoma mortality (9). However, patients with a prior melanoma are at an increased risk for developing a second primary melanoma (10).

Since the patient in our report had a history of a previous superficial spreading melanoma located at the dorsal trunk, the case was posted to the International Dermoscopy Society (IDS) discussion forum, for other experts to give their opinions whether it was a second primary skin melanoma, or a potential skin metastasis (http://www.dermoscopy-ids.org). Most participants in the discussion thought that most likely it was a second, or a secondary skin melanoma (11). Since histopathology analysis revealed a SSM, this finding actually confirmed that the tumor was a primary skin melanoma.

Melanoma risk is highest in lower latitude areas, where levels of ultra-violet light are high. However, apart from genetics, environment and lifestyle may also contribute to one's chances of developing melanoma. In our case, the patient had a few severe sunburns from childhood and teenage years, skin type I, as well as family and personal history of melanoma.

Unfortunately, in our country there are no precise data on the morbidity and mortality rates. Nevertheless, from day to day, our practitioners see more and more melanomas. Since we use digital dermoscopy, micro-invasive melanomas are more often reported (12).

Nowadays there are many e-dermatology sites, including those focused on teleconsultations: telederm.org, dermoscopy-ids.org, eMedicine; DermIS.net; dermatlas.org etc. Their help and support is invaluable whenever a physician needs a second opinion i.e. expert opinion.

On the other hand, basal cell carcinoma is the most common type of non-melanoma skin cancer, seen mostly in elderly people. Sun exposure is responsible for over 90% of skin cancers (13,14).

In conclusion, the emphasis should be upon early and proper assessment of all high-risk patients. Total body skin examination (TBSE) is strongly recommended at the time of the first consultation. It should include clinical examination, palpation and self-examination. Patients with family or/and personal history of melanoma, or with one or more other risk factors (phototypes I and II, five moles larger than 6 millimeters in diameter vs. dysplastic nevi, or more than 25 common nevi, changes in the existing moles etc.), should be included in the follow-up program by digital dermoscopy. Early treatment of melanoma is crucial.

References

1. Watson JA, Bergman H, Kvedar JC. Teledermatology: eMedicine Dermatology; 2007 [cited 2011 Jan 10]. Available from http://www.emedicine.medscape.com/article/1130654-overview.
2. Massone C, Wurm MT, Hofmann-Wellenhof R, Lozzi GP, Soyer HP. Teledermatology. In: Soyer HP, et al. Colour atlas of melanocytic lesions of the skin. Berlin: Springer-Verlag; 2007. p. 57-60.
3. Soyer HP, Smolle J, Hodl S, Pachernegg H, Kerl H. Surface microscopy: a new approach to the diagnosis of cutaneous pigmented tumors. Am J Dermatopathol 1989;11:1-11.
4. Marghoob AA, Braun RP, Kopf AW. Atlas of dermoscopy. New York: Taylor Francis; 2004.
5. Braun RP, Robinovitz HS, Oliviero M, Kost AW, Saurat JH. Dermoscopy of pigmented skin lesions. J Am Acad Dermatol 2005;52(1):109-21.
6. Eedy DJ. Surgical treatment of melanoma. Br J Dermatol 2003;149:2-12.
7. Sober AJ. Cutaneous melanoma: practical usefulness of the American Joint Committee on cancer staging system. Dermatol Ther 2005;18:407-11.
8. Kitchener S. Epidemioology of melanoma. In: Soyer HP, et al. Colour atlas of melanocytic lesions of the skin. Berlin: Springer-Verlag; 2007. p. 185-95.

© 2009 The Serbian Association of Dermatovenereologists

9. Giles GG, Armstrong BK, Burton RC, et al. Has mortality from melanoma stopped rising in Australia? Analysis of trends between 1931 and 1994. Br Med J 1996;312:1121-5.
10. Goggins WB, Tsao H. A population based analysis of risk factors for a second primary cutaneous melanoma among melanoma survivors. Cancer 2003;97:639-43.
11. Bono R, Giampetruzzi AR, Cocolino F, Puddu P, Scoppola A, Sera F, et al. Dermoscopic patterns of cutaneous melanoma metastases. Melanoma Res 2004;14(5):367-73.
12. Alendar F, Drljevic I, Drljevic K, Alendar T. Early detection of melanoma skin cancer. Bosn J Basic Med Sci 2009;9(1):77-80.
13. Obralic N. Tumori kože. U: Mušanović M, Obralić N. Onkologija. Sarajevo: Bošnjački institut; 2001. str. 175-80.
14. Drljević I. Influence of detrimental radiation of sunrays on an increase in malignant melanoma and non-melanoma malignant skin tumors (master thesis). Sarajevo: Sarajevo University; 2006.

Značaj dermoskopskog praćenja u identifikaciji osoba s visokim rizikom od pojave drugog primarnog kutanog melanoma – prikaz slučaja

Sažetak

Uvod: Telemedicina koristi savremene informatičke i komunikacione tehnologije za prenos medicinskih podataka sa jednog na drugo mesto, čime se stiču uslovi za pružanje zdravstvenih medicinskih usluga po principima kliničke medicine, bez obzira na to gde se geografski nalaze davalac zdravstvenih usluga, pacijent, medicinska informacija ili oprema. Telemedicinske aplikacije obuhvataju: teledijagnostiku, telekonsultacije, telemonitoring, telenegu, telekonzilijume i daljinski pristup informacijama koje se nalaze u jednoj ili više baza podataka.

Telemedicina funkcioniše u dva konceptualno različita vremenska okvira: u realnom, tj. sinhronom (videokonferencija) i odloženom, tj, asinhronom. U teledermatologiji se najčešće koristi ovaj drugi pristup. Dermoskopija (epiluminiscentna mikroskopija; dermatoskopija) predstavlja *in vivo* dijagnostičku proceduru koja služi za bolju vizualizaciju kože, njene strukture i promena nastalih u njoj. Novonastale promene, ukoliko su nedovoljno vidljive golim okom, postaju zahvaljujući dermoskopskom pregledu bolje vidljive i mogu se klasifikovati kao melanocitne ili nemelanocitne. Glavni zadak dermatoskopije je rano otkrivanje i pravilno lečenje melanoma.

Prikaz slučaja: Prikazujemo četrdesetosmogodišnju pacijentkinju koja je u svojoj ličnoj anamnezi navela podatak da joj je godinu dana ranije odstranjen melanom sa kože leđa. Takođe je navela podatak o srodniku obolelom od melanoma. Javila se na pregled zbog nove pigmentovane promene lokalizovane na levom bedru, koja se pojavila šest meseci ranije i na kojoj je zapazila porast i promenu boje lezije.

Iz priložene medicinske dokumentacije, tumor koji je odstranjen godinu dana ranije, predstavljao je melanom debljine 0,5 mm po Breslowu i Clark II (stadijum IA).

Kliničkim pregledom, kod pacijentkinje je utvrđen tip kože I (po Fitzpatrickovoj skali), bez povećanog broja mladeža (< 25), i sa nekoliko promena tipa solarnog lentiga na fotoeksponiranim regijama, posebno na gornjoj polovini leđa. Postoperativni ožiljak na mestu prethodno postojećeg melanoma nije pokazivao znake aktivnosti, a regionalne limfne žlezde nisu bile palpabine.

Pacijentkinja se javila na pregled zbog nove pigmentne promene lokalizovane na levom bedru, koja se pojavila šest meseci ranije, vremenom se povećavala i promenila boju.

Kliničkim pregledom je na koži levog bedra uočena tumorska promena s maksimalnim dijametrima 10,5 x 12 mm, palpabilna, naročito u svom centralnom delu. Na površini lezije uočavala se različita obojenost, od svetlosmeđe, tamnosmeđe do crne i sive.

Na dermoskopskom pregledu uočen je melanocitni karakter promene sa sledećim strukturnim elementima: atipična mreža, iregularne crte, iregularne globule/tačke, iregularne mrlje, centralna homogena hipopigmentovana zona.

U predelu desne lopatice, nalazila se lako indurovana promena tumorskog izgleda, svetlosmeđe do crvenkaste boje, ovalnog izgleda, zaravljene površine, sa maksimalnim dijametrima 1,5 x 0,9 mm.

Dermoskopskim pregledom lezije utvrđene su sledeće strukture: nedostak pigmente mreže, gracilni arborizovani krvni sudovi u centralnom delu, nekoliko

© 2009 The Serbian Association of Dermatovenereologists

malih ulceracija prekrivenih svetlosmeđom krustom.
Radi sprovođenja patohistološke analize, izvršena je uz pomoć lokalne anestezije kompletna hirurška ekscizija pigmentne lezije, uključujući okolno, klinički nepromenjeno tkivo, u širini od 2 mm. Analiza je pokazala da se radilo o površinski širećem melanomu: Breslow 1 mm, Clark III stadijum, bez ulceracija, gust limfocitni inaflamatorni infiltrat (5 mitoza/10 vidnih polja HPF – eng. *high power fields*). Usledila je reekscizija sa zahvatanjem klinički neizmenjene kože u širini od 10 mm. Pregledom stražarskog limfnog čvora u predelu levog bedra, dobijen je negativan nalaz, u stražarskom čvoru nisu utvrđene mikrometastaze. Radilo se o Ia stadijumu po kriterijumima Američkog združenog komiteta za kancer – AJCC. Indikovno je praćenje pacijentkinje kako kliničko tako i dermoskopsko, s kontrolnim pregledima u intervalima 3-6 meseci.
Radi patohistološke analize, u lokalnoj anesteziji izvršena je totalna ekscizija tumora i postavljena je dijagnoza bazocelularnog karcinoma u pT1 stadijumu.
Diskusija: Melanom se može javiti u bilo kom životnom dobu. Najveća incidencija melanoma je u Australiji, ali zahvaljujući ranom otkrivanju i adekvatnoj terapiji stopa mortaliteta u odnosu na druge zemlje je niska. Osobe sa primarnim melanomom su pod povišenim rizikom od nastajanja drugog primarnog kutanog melanoma. S obzirom da je pacijentkinja već ranije imala površinski šireći primarni melanom na koži, ceo slučaj je bio poslat na telekonsultaciju u Internacionalno dermoskopsko društvo na ekspertizu da li je tumor bio primarni ili metastatski. Zaključak je bio da se nije mogla isključiti ni jedna ni druga mogućnost. Dilemu je rešila patohistološka analiza (početak u epidermisu).
Najviši rizik od dobijanja melanoma je u područjima sa malom geografskom širinom, gde je količina UV zračenja najveća. Pored klimatskih faktora, genetska predispozicija i način življenja takođe utiču na primečivost za dobijanje melanoma. Kod naše pacijentkinje, pored anamnestičkih podataka o nekoliko epizoda opekotina od sunca u detinjstvu, fototip I kože i pozitivna lična i porodična anmneza u vezi sa melanom, povećali su rizik od obolevanja.
Nažalost, u našoj zemlji ne raspolažemo preciznim epidemiološkim podacima o morbiditetu i mortalitetu od malignog melanoma, ali ono što je evidentno, nakon uvođenja digitalne dermoskopije u rutinski rad dermatologa, svakodnevno se dijagnostikuje sve veći broj melanoma, prvenstveno mikroinvazivnih.
Radi što boljeg dijagnostičkog, a samim tim i terapijskog postupka, veliku pomoć pružaju telemedicinske platforme, naročito one koje su usmerene na telekonsultacije, kao što su: telederm.org; dermoscopy-ids.org; eMedicine; DermIS.net; dermatlas.org.
Istovremeno postojanje bazocelularnog karcinoma kod naše pacijentkinje, ukazuje na prisustvo najučestalijeg nemelanomskog karcinom kože, za čiji nastanak izlaganje UV zracima predstavlja najvažniji faktor rizika. Za razliku od skvamocelularnog, za nastanak bazocelularnog karcinoma, veći značaj se danas pridaje intermitentnoj a ne kumulativnoj dozi UV zračenja.
Zaključak: Najznačajnije je rano otkrivanje svih faktora rizika i adekvatna evaluacija pacijenata koji spadaju u rizičnu grupu. Potrebno je sprovoditi preglede i kontrolne preglede čitave kože, koji pored inspekcije treba da obuhvate i palpaciju, ali i da se dopunjuju samopregledima za koje treba obučiti pacijente. Najveći zadatak dermoskopije je upravo edukacija pacijenata sa ciljem sprovođenja redovne i adekvatne samoinspekcije. Pozitivna lična i porodična anamneza za melanom, ili prisustvo jednog ili većeg broja ostalih faktora rizika (fototip kože I ili II, najmanje pet mladeža dijametra većeg od 6 mm, displastični nevusi, više od 25 običnih nevusa; novonastale promene na postojećim nevusima), svrstavaju određenog pacijenta u grupu rizičnih i zahtevaju njegovo stalno dermoskopsko praćenje. Prevencija i profilaktička terapija su od neprocenjivog značaja.

Ključne reči

Melanom; Druga primarna neoplazma; Dermoskopija; Limfne žlezde; Bazocelularni karcinom; Telemedicina; Praćenje bolesnika

© 2009 The Serbian Association of Dermatovenereologists