sciendo

DOI: 10.2478/rjr-2023-0009

Romanian Journal of Rhinology, Volume 13, No. 50, April - June 2023

ORIGINAL STUDY

Peripheral smell regions in patients with central vertigo: An MRI evaluation

Mikail Inal[1], Nuray Bayar Muluk[2], Neşe Asal[1], Murat Alpua[3]

[1]Radiology Department, Kırıkkale University, Faculty of Medicine, Kırıkkale, Turkey

[2]ENT Department, Kırıkkale University, Faculty of Medicine, Kırıkkale, Turkey

[3]Neurology Department, Kırıkkale University, Faculty of Medicine, Kırıkkale, Turkey

ABSTRACT

OBJECTIVES. We investigated peripheral smell regions in patients with central vertigo by cranial magnetic resonance imaging (MRI).

MATERIAL AND METHODS. In this study, 137 adult patients were included by selecting cranial MRI images from the hospital's PACS system, covering both recent and past records. The first group included 68 adult patients suffering from central vertigo, and the control group (Group 2) 69 healthy individuals, who had no central vertigo. Measurements of olfactory bulb (OB) volume and olfactory sulcus (OS) depth were taken from all groups.

RESULTS. The study found that the OB volume of the group with central vertigo was significantly lower compared to the control group ($p<0.05$). However, there were no significant differences in the OS depth between the two groups ($p>0.05$). In both groups, there were no significant variations in OB volume between the right and left sides ($p>0.05$). Additionally, both the central vertigo group and the control group showed that the left OS depth was lower than the right side ($p<0.05$). Positive correlation was seen between OB volume and OS depth on both left and right sides as well as bilateral OB volume and OS depth in the central vertigo group. However, there were no significant correlations between OB volume, OS depth and age and gender in the central vertigo group.

CONCLUSION. We concluded that OB volume got lower in patients with central vertigo. However, there were no side differences between OB volumes. As central vertigo secondary to cerebral ishchemia causes olfactory disorders, measures should be taken to prevent central vascular problems. From another perspective, olfactory problems may be one of the initial signs of central vascular problems and central vertigo.

KEYWORDS: central vertigo, OB volume, OS depth, cranial MRI.

INTRODUCTION

Central vertigo often develops secondary to cerebellar or brain stem ischemia. In central vertigo, autonomic symptoms, nausea, diplopic, focal weakness, dysarthria and dysphagia may occur. Usually, it lasts 20 minutes to 24 hours. During acute vertigo episodes, people with cerebellar disease typically have difficulty walking, while those with peripheral vertigo tend to be able to walk and maintain awareness of their surroundings[1].

In inflammatory and neurodegenerative diseases of the central nervous system, audiovestibular, taste and odor symptoms may occur in relation to disease activity and progression (e.g., multiple sclerosis). Gustatory changes are linked to demyelination in the taste region of the brain. The progression of the disease causes additional audiovestibular and olfactory symptoms[2]. Cerebral ischemic conditions may play a role in central vertigo; moreover, olfactory disorders may be detected due to central vertigo related to cerebellar ischemia.

The carotid arteries are blood vessels located in the neck that deliver blood to the brain, head and face. Carotid artery stenosis is a condition in which these vessels narrow. In some cases, people with carotid artery stenosis may experience symptoms such as dizziness, fainting, and blurred vision, indicating a lack of blood flow to the brain. Often, the first signs of the condition are a transient ischemic attack (TIA) or a

Corresponding author: Dr. Nuray Bayar Muluk, ENT Department, Kırıkkale University, Faculty of Medicine, Kırıkkale, Birlik Mahallesi, Zirvekent 2. Etap Sitesi, C-3 blok, No: 6-3/43, 06610 Çankaya / Ankara, Turkey

ORCID: https://orcid.org/0000-0003-3602-9289

e-mail: nuray.bayar@yahoo.com; nurayb@hotmail.com

Received for publication: December 21, 2022 / **Accepted:** January 23, 2023

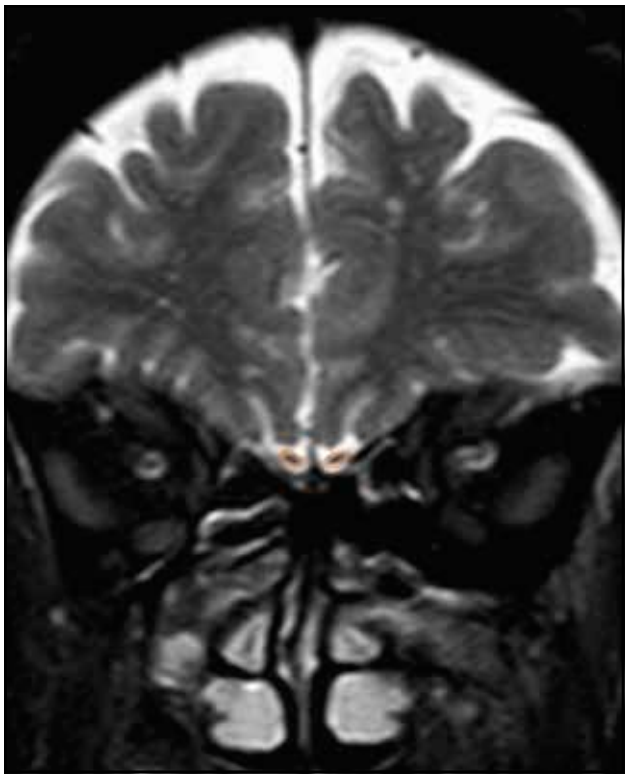

Figure 1. On coronal T2-weighted MRI images, OB volume measurements are shown (orange circles).

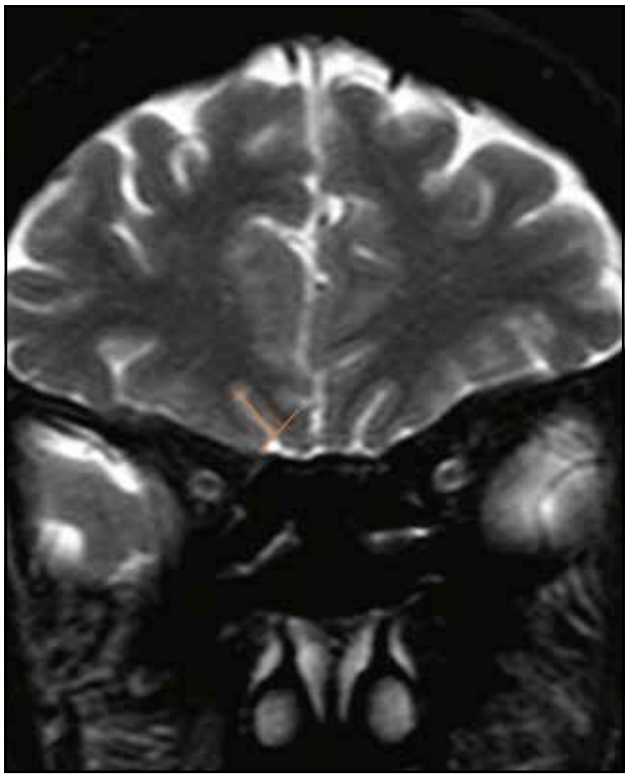

Figure 2. On coronal T2-weighted MRI images, OS depth measurements are shown (orange arrow).

stroke, which can occur as a result of a blood clot forming in an area of the vessel affected by atherosclerosis. Risk factors for carotid artery stenosis include age, smoking, high blood pressure, diabetes, obesity and a sedentary lifestyle[3].

When there is damage or narrowing of the vertebral arteries, the artery can be torn, or dissect; dizziness or stroke may develop[4-9]. Therefore, odor disorders may occur due to central vertigo, which occurs in central ischemic pathologies due to carotid artery pathologies.

Clinical symptoms of odor disorders include "hyposmia (decreased sense of smell); dysosmia (distorted odor identification) or parosmia (abberent odor perception), phantosmia (without odor stimulant) or agnosia (which is an odor stimulant but cannot be classified); and anosmia (total loss of odor)"[10].

In the present study, we investigated peripheral smell regions of the olfactory bulb (OB) volume and olfactory sulcus (OS) depth in central vertigo patients, by cranial magnetic resonance imaging (MRI). Our study is the first conventional MRI study in the literature to examine the relationship between central vertigo and odor pathways. In addition, performing conventional MRI examination will facilitate diagnosis in routine practice.

MATERIAL AND METHODS

The study was conducted retrospectively by a collaboration of "Neurology, Radiology and Otorhinolaryngology Departments at Kırıkkale University, Faculty of Medicine". Cranial MRI images were obtained from the "Radiology Department database", and the ethical approval for this study was taken by "Kırıkkale University Non-invasive Research Ethics Committee" (Date: 18.09.2019; Number: 2019/08/18).

Subjects

This study employed a retrospective design, in which 137 adult patients were included by selecting cranial MRI images from the hospital's PACS system, covering both recent and past records.

The first group, which included 68 adult patients (33 males, 35 females) suffering from central vertigo, was made up of individuals whose vertigo was linked to carotid artery stenosis, vertebral artery stenosis, cerebellar infarcts, and cerebral small vascular disease. The average age of this group was 52.63±16.46 years, with a range from 18 to 82 years.

The control group (Group 2), which had 69 adult patients (32 males and 37 females) without vertigo, was made up of cranial MRI images of individuals without vertigo. The images used in this study were gathered from the hospital's PACS system, comprising both recent and historical records. These images were of adult

Table 1. Measurement results for olfactory bulb volume and olfactory sulcus depth of the groups.

		Group 1 (Central Vertigo) (n=68)			Group 2 (Control) (n=69)			P*
		(n=68)	Median	Std.Dev.	Mean	Median	Std.Dev.	
Age		52.63	56.00	16.46	48.31	50.00	13.67	0.097
Measurement results								
Olfactory bulb (OB) volume (mm^3)	R	36.36	35.15	9.80	50.18	50.21	6.77	0.000
	L	36.95	38.01	10.74	51.19	49.45	7.83	0.000
	P**		0.462			0.210		
Olfactory sulcus (OS) depth (mm)	R	6.82	6.82	0.90	6.91	6.82	0.94	0.570
	L	6.54	6.44	0.89	6.65	6.62	0.92	0.473
	P**		0.006			0.005		

*p value shows the results of independent samples t-test
**p value shows the results of paired samples t-test

patients who had undergone cranial MRI scans for headaches or vertigo and were reported as normal. The average age of these patients was 43.31±13.67 years, with ages ranging from 18 to 79 years.

Individuals who had a history of prior trauma or surgery, nasal polyps, severe deviation of the nasal septum, tumors, leaks in the cerebrospinal fluid, Parkinson's disease, Alzheimer's disease, or multiple sclerosis were excluded from the study.

Cranial MRI measurements

Magnetic resonance imaging (MRI) was performed using a "1.5 Tesla MRI machine (Philips MRI Systems, Achieva Release 3.2 Level 2013-10-21, Philips Medical Systems Nederland B.V.) with a cranial coil". Fat-suppressed T2-weighted images in the coronal plane ("TR ms/TE ms; 6557/100, FOV 220×175mm and matrix 224×165 mm") were taken with a "5-mm slice thickness and 1-mm intersection gap". A total of 25-30 coronal sections were obtained from these images. Measurements were taken from the coronal T2-weighted images for standardization.

Olfactory bulb (OB) volume (Figure 1) and olfactory sulcus (OS) depth (Figure 2) were measured by a single radiologist (N.A.)[11].

Statistical Analysis

The statistical analysis was performed by SPSS for Windows 16.0 (SPSS, INC, an IBM Company, Chicago, Illinois). Chi-square test, paired samples t-test, independent samples t-test, Pearson correlation test and Spearman's correlation rho efficient test were used. P-value <0.05 was considered statistically significant.

RESULTS

The data for age and gender of the groups revealed no significant distinctions (p>0.05), as seen in Table 1. Results for measurements of the olfactory bulb volume and olfactory sulcus depth are provided in Table 1 as well.

Additionally, the data for gender of the groups revealed no significant distinctions (p=0.801, chi-square=0.064), which is also reflected in Table 1.

Olfactory bulb (OB) volume

The results showed that the olfactory bulb volumes of the two groups were significantly different, on both sides (p<0.05), as seen in Table 1. The olfactory bulb volume of the vertigo group was also found to be significantly smaller compared to the control group (p<0.05), as indicated in Table 1. Additionally, when analyzing the data for each group individually, there were no significant variantions in olfactory bulb volume between the right and the left sides (p>0.05), as Table 1 reflects.

Olfactory sulcus (OS) depth

Table 1 shows that the olfactory sulcus depth did not have any significant differences between the two groups (p>0.05). However, when the data for each group was examined independently, it was observed that in both the control group and the vertigo group, the left olfactory sulcus depth was statistically lower than the right side (p<0.05) as reflected in Table 1.

Correlation test results in the vertigo group are shown in Table 2. After analysing the results, we ob-

Table 2. Correlation test results in the central vertigo group.

			OB Volume (mm^3)		OS Depth (mm)	
			R	L	R	L
OB Volume (mm^3)	R	r		0.799	0.292	0.243
		P*		0.000	0.016	0.046
	L	r	0.799		0.345	0.329
		P*	0.000		0.004	0.006
OS Depth (mm)	R	r	0.345	0.345		0.576
		P*	0.004	0.004		0.000
	L	r	0.243	0.329	0.576	
		P*	0.046	0.006	0.000	
Age		r	-0.150	-0.162	-0.131	-0.055
		P*	0.221	0.187	0.287	0.656
Gender (Code 1: Male, Code 2: Female)		r	-0.061	-0.049	0.008	-0.067
		P**	0.618	0.689	0.952	0.589

*p value shows the results of Pearson correlation test
**p value shows the results of Spearman's correlation rho efficient test
OB: Olfactory bulb, OS: Olfactory sulcus t

served a positive correlation between OB volumes and OS depths on the left and the right side, respectively. The same observation was made in case of bilateral OB volumes and OS depths ($p<0.05$) (Table 2). There were no significant correlations between OB volume, OS depth and age and gender of the vertigo group ($p>0.05$) (Table 2).

DISCUSSIONS

Central vertigo mostly occurs due to strokes, acute vascular events, metabolic conditions, central tumors, degenerative or paroxysmal disorders[12-14]. Central vertigo or dizziness is the most common symptom of strokes, whose 20% is related to ischemic strokes[15]. Acute vascular vertigo must be diagnosed in the emergency conditions[14]. Therefore, a detailed neuro-otological examination and perfusion imaging are very important to diagnose acute vascular vertigo to prevent strokes[16,17]. Transient ischemia within the vertebrobasilar circulation and infarction in the posterior circulation may result in central vertigo. In cerebrovascular disorders, there are additional neurological signs and symptoms which accompany vertigo[18].

People with carotid artery stenosis may remain asymptomatic for a long time. Temporary symptoms that may be stimulating symptoms of a future paralysis include: 1). "blurred or darkened vision"; 2). "temporary visual impairment including blurred vision in an eye (called monocular vision loss or "amaurosis fugax")"; 3). "weakness or paralysis on one side of the body"; 4). "slurred speech"; 5). "less common symptoms include dizziness, nausea and concentration difficulties". Such symptoms should be taken seriously, as a longer interruption in blood flow can lead to tissue death (stroke). The most common symptoms are paralysis on one side of the body, speech impairment and difficulty finding the right words[19].

Stroke is one of the most distressing complications seen in the carotid stenosis. Stenosis may be asymptomatic in 60-99% of patients. However, 45% of strokes can be caused by lacunar infarctions and cardiac embolisms[20]. Other possible symptoms of carotid stenosis include impaired sense of smell, hearing loss and vision loss[19].

The current research looked into the peripheral olfactory regions of the olfactory bulb volume and olfactory sulcus depth in patients experiencing central vertigo by using cranial MRI. Results revealed that the olfactory bulb volume in the central vertigo group was significantly smaller than that of the control group; however, there were no differences in olfactory sulcus depth between the two groups. No significant variations were seen in olfactory bulb volumes between the right and left sides in both groups. In both the central vertigo group and the control group, the left olfactory sulcus depth was lower than the right side.

The central vertigo group showed positive correlation between the olfactory bulb volume and olfactory sulcus depth, as well as bilateral olfactory bulb volume and olfactory sulcus depth. There was no correlation found between olfactory bulb volume, olfactory sulcus depth, age, and gender in the central vertigo group.

Vertigo can be caused by issues in either the peripheral or central nervous system. The most prevalent peripheral causes include BPPV, vestibular neuronitis, Ménière's disease, and conditions that affect the inner ear due to an immune response. Migraines, also known as vestibular migraines or migraine-associated dizziness, are the most common central cause of dizziness. Other potential central triggers include demyelination, tumors affecting the ear, and damage to the brainstem or cerebellum. An important aspect of evaluating vertigo is analyzing the characteristics of nystagmus, which can indicate whether the cause is in the peripheral or central system. Peripheral nystagmus is typically rotational and more pronounced when visual fixation is removed, while central nystagmus is usually horizontal or vertical

and not influenced by visual fixation[1].

Odor disorders are reported in cases of chronic dizziness after minor traumas[21]. Controversial from olfactory disorders related to central vertigo, vertigo cases caused by olfactory reasons have also been reported in the literature[22,23].

Explanations for smell loss may be related to decreased blood flow after surgery[24] or functional lesions due to surgical interventions of olfactory bulbs and tracts[25]. While the change in odor threshold is considered to be associated with the peripheral parts of the olfactory system, smell discrimination is related to brain central processing[26,27]. Olfactory and taste disorders were rarely reported in patients with post-stroke period[28,29].

CONCLUSIONS

Our results showed that OB volume got lower in patients with central vertigo. However, there are no side differences between OB volumes. As central vertigo secondary to cerebral ishchemia causes olfactory disorders, measures should be taken to prevent central vascular problems. From another perspective, olfactory problems may be one of the initial signs of central vascular problems and central vertigo.

Financial discloser: There are no financial disclosures of the authors.

Conflict of interest: The author Mikail INAL declares that he has no conflict of interest. The author Nuray BAYAR MULUK declares that she has no conflict of interest. The author Neşe ASAL declares that she has no conflict of interest. The author Murat ALPUA declares that he has no conflict of interest.

Ethics committee approval: This study is retrospective. Ethics committee approval was obtained from Kırıkkale University Non-invasive Research Ethics Committee (Date: 18.09.2019; Number:2019/08/18).

There is no need to take informed consent because the data were evaluated retrospectively.

There are no funds for this article.

Contribution of authors: Mikail INAL: Planning, designing, Literature survey. Nuray Bayar Muluk: Planning, designing, literature survey, statistical analysis, writing, submission. Neşe ASAL: Planning, designing, data collection, literature survey. Murat ALPUA: Planning, designing, literature survey.

Authors' information:

Mikail Inal, Associate Professor in Kırıkkale University, Faculty of Medicine, Radiology Department, Kırıkkale, Turkey. E-mail: inal_m@hotmail.com. ORCID: https://orcid.org/0000-0003-0642-7913.

Nuray Bayar Muluk, Professor in Kırıkkale University, Faculty of Medicine, ENT Department, Kırıkkale, Turkey. E-mail: nuray.bayar@yahoo.com. ORCID: https://orcid.org/0000-0003-3602-9289.

Neşe Asal, Associate Professor in Kırıkkale University, Faculty of Medicine, Radiology Department, Kırıkkale, Turkey. E-mail: nese_asal@yahoo.com.tr. ORCID: https://orcid.org/0000-0002-3787-556X.

Murat Alpua, Associate Professor in Kırıkkale University, Faculty of Medicine, Neurology Department, Kırıkkale, Turkey. E-mail: dr.muratalpua@yahoo.com. ORCID: https://orcid.org/0000-0002-0951-5962.

REFERENCES

1. Samy HM, Hamid MA, Friedman M Dizziness, vertigo, and imbalance. [Internet]. Medscape. [updated Oct 27, 2022]. Available from: https://emedicine.medscape.com/article/2149881-overview.
2. Ralli M, D'Aguanno V, Altieri M, Di Stadio A, Turchetta R, de Vincentiis M, et al. Ageusia, hyposmia, dizziness and tinnitus as presenting symptoms of multiple sclerosis. International Tinnitus Journal. 2018;22(2):150-5. DOI: 10.5935/0946-5448.20180025.
3. Carotid Artery Stenosis. [Internet]. RadiologyInfo.org. Available from: https://www.radiologyinfo.org/en/info/carotidstenosis. Accessed September 22, 2020.
4. Cassidy JD, Boyle E, Cote P, He Y, Hogg-Johnson S, Silver F, et al. Risks of vertebrobasilar stroke and chiropractic care: results of a population-based case-control and case-crossover study. Spine (Phila Pa 1976). 2008;33(4 Suppl):S176-83. DOI: 10.1097/BRS.0b013e3181644600.
5. Kamouchi M, Kishikawa K, Matsuo R, Yasumori K, Inoue T, Okada Y, et al. Ultrasonographic detection of extracranial vertebral artery compression in bow hunter's brain ischemia caused by neck rotation. Cerebrovasc Dis. 2003;16(3):303-5. DOI: 10.1159/000071134.
6. Mann T, Refshauge KM. Causes of complications from cervical spine manipulation. Aust J Physiother. 2001;47(4):255-66. DOI: 10.1013/s0004-9514(14)60273-7.
7. Smith WS, Johnston SC, Skalabrin EJ, Weaver M, Azari P, Albers GW, et al. Spinal manipulative therapy is an independent risk factor for vertebral artery dissection. Neurology. 2003;60(9):1424-8. DOI: 10.1212/01.wnl.0000063305.61050.e6.
8. Sakaguchi M, Kitagawa K, Hougaku H, Hashimoto H, Nagai Y, Yamagami H, et al. Mechanical compression of the extracranial vertebral artery during neck rotation. Neurology. 2003;61(6):845-7. DOI: 10.1212/01.wnl.0000078081.12097.ae.
9. Vibert D, Rochr-Le Floch J, Gauthier G. Vertigo as manifestation of vertebral artery dissection after chiropractic neck manipulations. ORL J Otorhinolaryngol Relat Spec. 1993:55(3):140-2. DOI: 10.1159/000276405.
10. Mann NM. Management of smell and tasteproblems. Cleve Clin J Med. 2002;69(4):329-36. DOI: 10.3949/ccjm.69.4.329.
11. Duprez TP, Rombaux P. Imaging the olfactory tract (cranial nerve #1). Eur J Radiol. 2010;74(2):288-98. DOI: 10.1016/j.ejrad.2009.05.065.
12. Dieterich M. Central vestibular disorders. J Neurol. 2007;254(5):559-68. DOI: 10.1007/s00415-006-0340-7.
13. Choi JY, Kim JS. Nystagmus and central vestibular disorders. Curr Opin Neurol. 2017;30(1):98-106. DOI: 10.1097/WCO.0000000000000416.
14. Choi JY, Lee SH, Kim JS. Central vertigo. Curr Opin Neurol. 2018;31(1):81-9. DOI: 10.1097/WCO.0000000000000511.
15. Fisher CM. Vertigo in cerebrovascular disease. Arch Otolaryngol. 1967;85(5):529-34. DOI: 10.1001/archotol.1967.00760040531010.

16. Choi JH, Park MG, Choi SY, Park KP, Baik SK, Kim JS, et al. Acute transient vestibular syndrome: prevalence of stroke and efficacy of bedside evaluation. Stroke. 2017;48(3):556-62. DOI: 10.1161/STROKEAHA.116.015507.
17. Choi JH, Kim HW, Choi KD, Kim MJ, Choi YR, Cho HJ, et al. Isolated vestibular syndrome in posterior circulation stroke: Frequency and involved structures. Neurol Clin Pract. 2014;4(5):410-8. DOI: 10.1212/CPJ.0000000000000028.
18. Wang Y, Liu J, Cui Z, Yan L, Si J. Analysis of risk factors in patients with peripheral vertigo or central vertigo. Neurologist. 2018;23(3):75-8. DOI: 10.1097/NRL.0000000000000179.
19. Carotid artery stenosis. [Internet]. Available from: https://herzzentrum.immanuel.de/en/services-offered/conditions/gefaesserkrankungen/carotid-artery-stenosis/.
20. Hemingway JF, Singh N. Atherosclerotic disease of the carotid artery. [Internet]. Medscape. [updated Feb 21, 2019]. Available from: https://emedicine.medscape.com/article/463147-overview.
21. Soma K, Kunihiro T. Examination of the hearing, taste and smell function in patients with chronic dizziness following minor trauma. Equilibrium Research. 2017;76(2):63-71.
22. Hinoki M, Nakanishi K, Kishimoto S, Ushio N, Kitamura H, Higashitsuji H, et al. Olfactory vertigo. A neurotological approach. Agressologie. 1981;22(B):45-57.
23. Yoza HT, Morimoto M, Futaki T. Olfactory induced vertigo - a case report of syphilitic hydrops. Practica Oto-Rhino-Laryngologica. 1979;72(10):1327-31.
24. Kumoi T, Iritani H, Nishimura Y, Minatogawa T. Animal model for ischemic facial nerve paralysis with selective vascular embolization. Ann Otol Rhinol Laryngol. 1992;101(5):423-9. DOI: 10.1177/000348949210100509.
25. Welge-Luessen A, Temmel A, Quint C, Moll B, Wolf S, Hummel T. Olfactory function in patients with olfactory groove meningioma. J Neurol Neurosurg Psychiatry. 2001;70(2):218-21. DOI: 10.1136/jnnp.70.2.218.
26. Moscavitch SD, Szyper-Kravitz M, Shoenfeld Y. Autoimmune pathology accounts for common manifestations in a wide range of neuro-psychiatric disorders: the olfactory and immune system interrelationship. Clin Immunol. 2009;130(3):235-43. DOI: 10.1016/j.clim.2008.10.010.
27. Soter A, Kim J, Jackman A, Tourbier I, Kaul A, Doty RL. Accuracy of self-report in detecting taste dysfunction. Laryngoscope. 2008;118(4):611-7. DOI: 10.1097/MLG.0b013e318161e53a.
28. Landis BN, Leuchter I, San Millán Ruíz D, Lacroix JS, Landis T. Transient hemiageusia in cerebrovascular lateral pontine lesions. J Neurol Neurosurg Psychiatry. 2006;77(5):680-3. DOI: 10.1136/jnnp.2005.086801.
29. Holbrook EH, Leopold D. Disorders of taste and smell. [Internet]. Medscape. [update Aug 02, 2022]. Available from: https://emedicine.medscape.com/article/861242-overview.

This is an open access article published under the terms and conditions of the Creative Commons Attribution-NonCommercial-NoDerivatives 4.0 International (CC BY-NC-ND 4.0) License (https://creativecommons.org/licenses/by-nc-nd/4.0/). CC BY-NC-ND 4.0 license requires that reusers give credit to the creator by citing or quoting the original work. It allows reusers to copy, share, read, download, print, redistribute the material in any medium or format, or to link to the full texts of the articles, for non-commercial purposes only. If others remix, adapt, or build upon the material, they may not distribute the modified material.