Atrial standstill in a young patient treated with left bundle branch area pacing

Cicala Ecaterina[1]*, Luca Cezar Dumitrel[2,3], Pestrea Catalin[1,2]

Abstract
Atrial standstill is a rare arrhythmogenic condition characterized by the absence of electrical and mechanical activity in the atria. The therapeutic options for these patients described in the current literature, in which no reversible cause is detected, are permanent cardiac pacing, anticoagulant, and heart failure treatment when the latter exists. We present a case of a young male with no personal or family history of cardiovascular disease, diagnosed with atrial standstill after multiple syncopal episodes, in whom, because of the high expected ventricular pacing percentage, we opted for conduction system pacing with left bundle branch area pacing.

Keywords
atrial standstill, syncope, conduction system pacing, left bundle branch area pacing

Rezumat
Paralizia atrială reprezintă o patologie rară, caracterizată prin absența activității electrice și mecanice la nivelul atriilor. Opțiunile terapeutice descrise în literatură la acești pacienți, la care nu se decelează o cauză reversibilă, sunt cardiostimularea electrică artificială permanentă, tratamentul anticoagulant și cel al insuficienței cardiace, atunci când aceasta există. Prezentăm cazul unui bărbat tânăr, fără antecedente personale și heredocolaterale cardiovasculare semnificative, diagnosticat cu paralizie atrială după multiple episoade sincopale. Având în vedere că anticipam un procent mare de stimulare ventriculară, am optat pentru stimularea fiziologică la nivelul ramului stang.

Cuvinte cheie
paralizie atrială, sincopă, cardiostimulare a sistemului de conducere, stimulare de ram stâng

Introduction

Atrial standstill (AS) is a rare arrhythmogenic condition characterized by the temporary or permanent absence of electrical and mechanical activity in the atria.[1] The clinical presentation can vary from exercise intolerance, syncope, cardioembolic episodes, hemodynamic compromise, and heart failure to arrhythmic death due to prolonged asystole or bradycardia-induced ventricular arrhythmia. For a definite diagnosis and adequate treatment, an electrophysiological study (EPS) is necessary, as most of the patients require dual or single-chamber pacemakers.

Clinical case

We present a case of a 28-year-old male without any significant personal or family history of cardiovascular disease hospitalized after multiple episodes of loss of consciousness in the past month. The patient was a non-smoker and denied any drug use or medication. The physical examination revealed a well-developed male (body mass index of 24.4kg/cm2) with bradycardic heart sounds but was otherwise unremarkable.

The presenting electrocardiogram (ECG) showed a junctional rhythm with a narrow QRS complex at 30 bpm with no atrial activity (Figure 1A). The echocardiography showed a mildly dilated left ventricle (LV) (69ml/m2) but normal left and right ventricular function, mildly enlarged atria, and absence of A-wave on a Doppler study of mitral and tricuspid inflow.

The laboratory, including the complete blood count, electrolytes, cardiac enzymes, thyroid, liver, and kidney function tests, were within the normal range.

The 24-hour Holter ECG monitoring captured numerous ventricular pauses with the longest of 12 seconds and no atrial activity (Figure 1B) and the minimum, maximum, and mean heart rates of 24, 65, and 48bpm, respectively.

An EPS was performed using a decapolar catheter placed in the coronary sinus (CS) and a quadripolar catheter placed into the right atria (RA) via the right femoral vein. During the mapping of the RA and CS, no electrical activity was detected. There was also a lack of capture at maximum energy output in different locations in RA and CS (Figure 2). The absence of atrial contraction was noted on fluoroscopy, confirming the diagnosis of AS.

We considered that the patient had a class I indication for permanent cardiac pacing. We opted for conduction system pacing because of the high percentage of expected right ventricular (RV) pacing. Using an axillary venous access site, the His bundle region was mapped with a 3830 SelectSecure lead (Medtronic, Minneapolis,

*Corresponding author: Cicala Ecaterina, Interventional Cardiology Unit, Brasov County Clinical Emergency Hospital, 500326 Brasov, Romania; E-mail address: cicalaecaterina@gmail.com

[1]Interventional Cardiology Unit, Brasov County Clinical Emergency Hospital, 500326 Brasov, Romania
[2]Department of Medical and Surgical Specialties, Faculty of Medicine, "Transilvania" University of Brasov, 500019 Brasov, Romania
[3]Acute Cardiology Unit, "Dr Benedek Geza" Hospital of Rehabilitation in Cardiovascular Diseases, 525200, Covasna, Romania

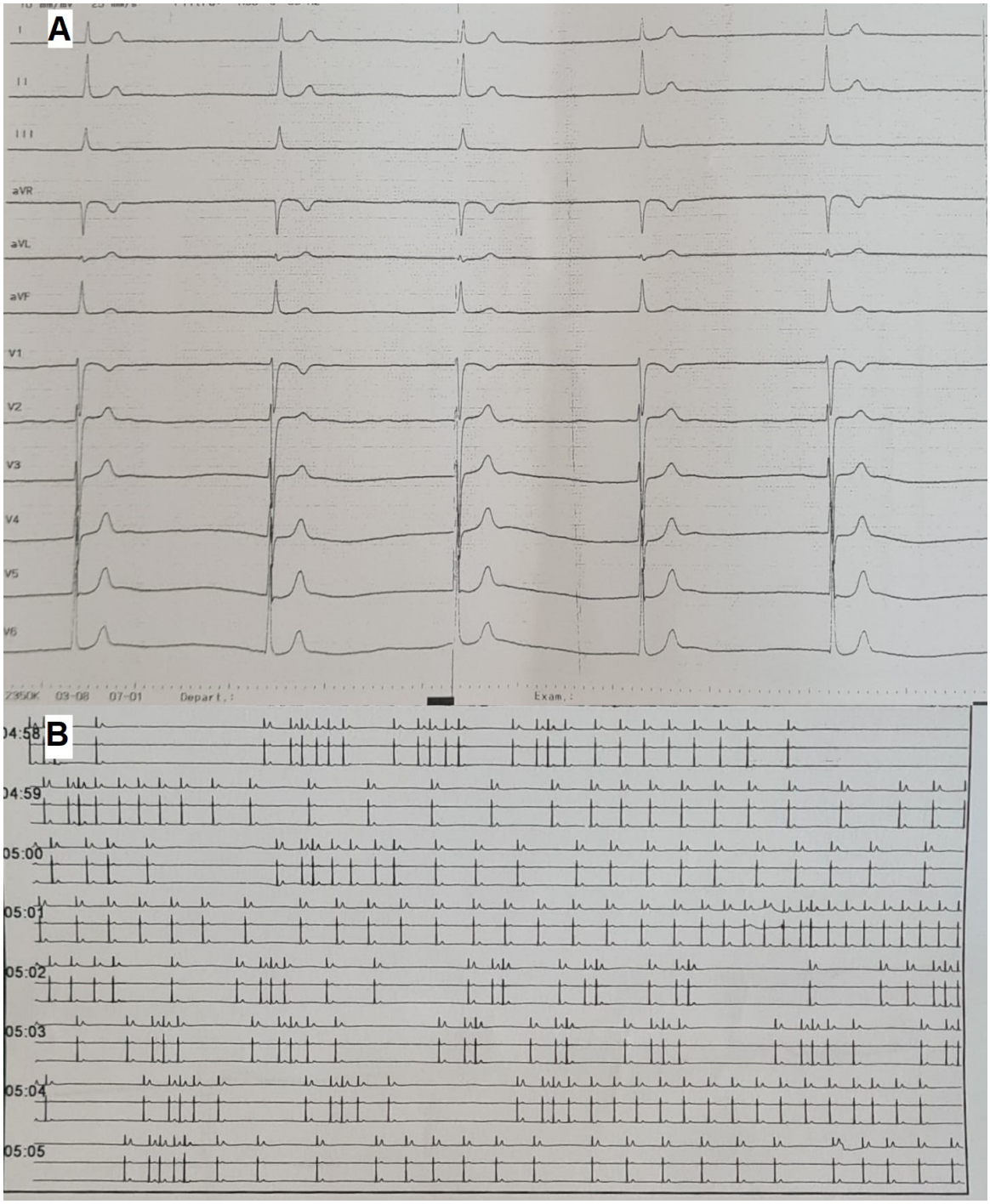

Figure 1 - A. The presenting ECG showed a junctional rhythm with a narrow QRS complex at 30 bpm with no atrial activity. B. The 24-hour Holter ECG monitoring showed numerous ventricular pauses and no atrial activity. ECG – electrocardiogram.

MN, USA) placed through a C315 His catheter (Medtronic, Minneapolis, MN, USA). A sharp His potential was obtained but with unacceptably high pacing capture thresholds (3V at 1ms pulse duration). Therefore, the lead was advanced approximately 1-1.5 cm distal to the His bundle toward the RV apex. After a suitable position perpendicular to the septum was achieved, the lead was screwed deep into the interventricular septum, reaching the left bundle branch (LBB), and confirmed by the presence of an LBB potential and a paced QRS complex of right bundle branch block morphology with a short left ventricular activation time (Figure 3A and 3B). The procedural pacing threshold was 1V at 0.4 ms pulse duration with a detection of 6 mV. The lead was connected to a single-chamber MRI-compatible Vitatron G20A2 pacemaker.

The procedure and the post-procedural hospitalization were uneventful. The patient was discharged the following day with a non-vitamin K anticoagulant, a recommendation for cardiac magnetic resonance imaging to be performed later, and family screening. Unfortunately, the patient did not consent to genetic testing. At the six-

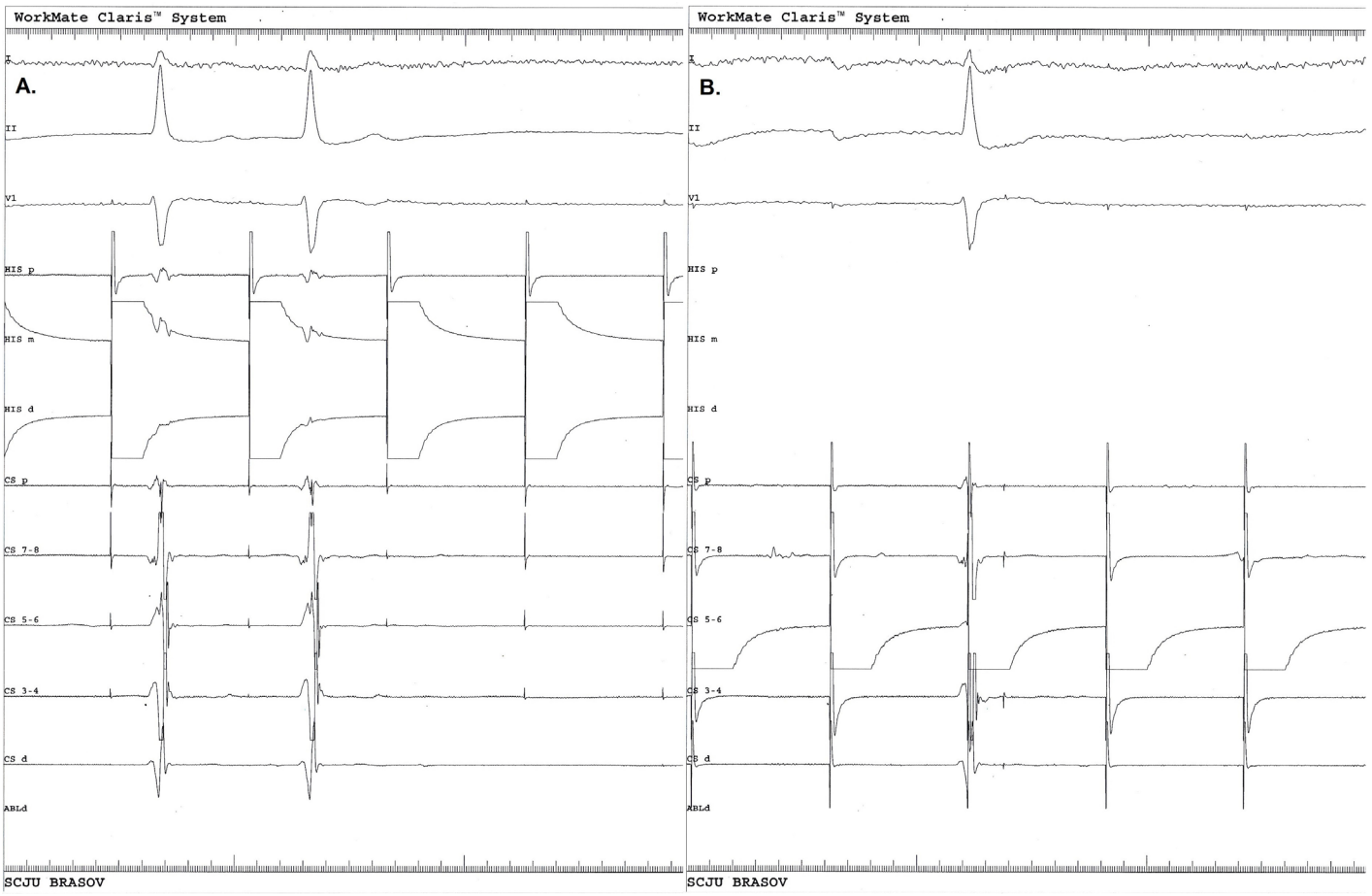

Figure 2 - Intracavitary electrograms (49mm/s) showed no atrial capture during pacing at 600 ms, 20mA at 1ms pulse duration at the level of the right atrium (quadripolar catheter at the lateral wall of the RS, the electrogram marked His d) (A) and coronary sinus (decapolar catheter placed in the coronary sinus, the electrogram marked CS 5-6) (B).

month follow-up, the patient was asymptomatic with stable sensing and pacing thresholds and 99% ventricular pacing at device interrogation.

Discussion

Atrial standstill is a rare arrhythmogenic condition characterized by the absence of electrical and mechanical activity in the atria. First described by Chavez, the diagnostic criteria require the absence of A-waves in jugular venous pulse and intra-atrial pressure recordings, regular junctional escape rhythm, the lack of atrial electrical activity on surface ECG and intracavitary electrograms, immobility of the atria on fluoroscopy, and inability to stimulate atria electrically.[1] AS distribution can vary from partial involvement or spread to the entire atria, intermittently or permanently affecting the atrial contractility.[2]

From an etiological point of view, AS can appear as a primary disease or secondary to specific clinical conditions such as hypoxia, myocardial infarction, and drug toxicity in transient forms, or muscular dystrophy, amyloidosis in permanent forms.[1, 2] It is assumed that there is also a genetic determinism, having been associated with the mutation of the sodium channels gene (SCN5A), lamin A/C gene (LMNA), and polymorphism of the atrial gap junction protein (connexin 40).[3]

Differential diagnosis of AS is made with sinus arrest and fine atrial fibrillation, usually requiring an EPS. [4] Compared to sinus arrest, along with no atrial electrical activity, there is no atrial capture at pacing in AS, while in atrial fibrillation with low amplitude f waves, disorganized atrial electrical activity can be detected at EPS.

Most of the patients require pacemaker implantation due to the symptomatic course of the disease and potentially fatal arrhythmic consequences. Knowing the importance of atrioventricular synchrony and atrial systole to ventricular filling with age, it is reasonable to map both atria in search of an adequate pacing site in AS with partial atrial involvement, highlighting once again the importance of the EPS. There are several reported cases with an atrial lead placed in the CS, reducing the unnecessary RV pacing and minimizing the risk of pacing-induced cardiomyopathy, pacemaker syndrome, and, consequently, heart failure.[5, 6] However, because of the progressive nature of the disease, there is a high risk of atrial capture failure over time. In our case, recordings from different RA and CS sites showed no electrical activity and no atrial capture; therefore, the implantation of a single-chamber pacemaker was considered.

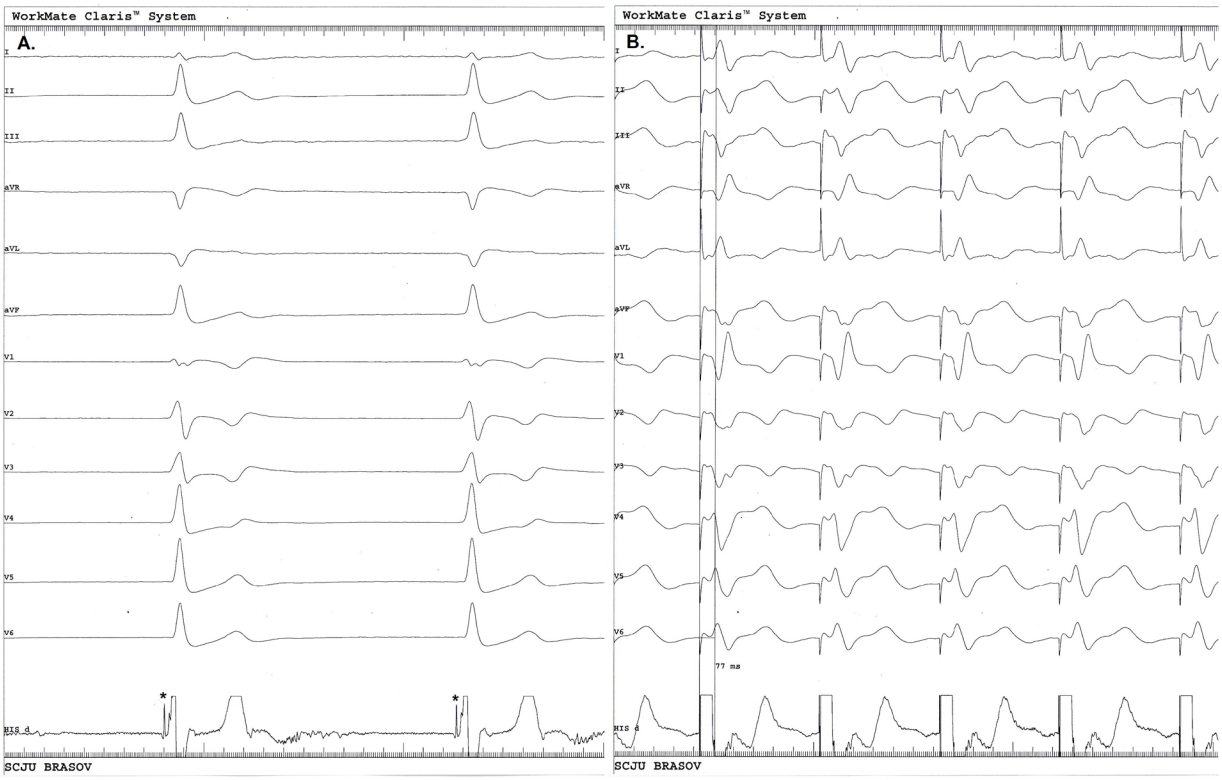

Figure 3 - A. A 12-lead ECG and intracardiac electrogram (49mm/s) showed an LBB potential after screwing the lead into the interventricular septum (asterisk). B. Pacing from the lead placed in the LBB area, depicting a typical QR morphology in V1 and an LVAT of 77ms. LBB-left bundle branch; LVAT-left ventricular activation time.

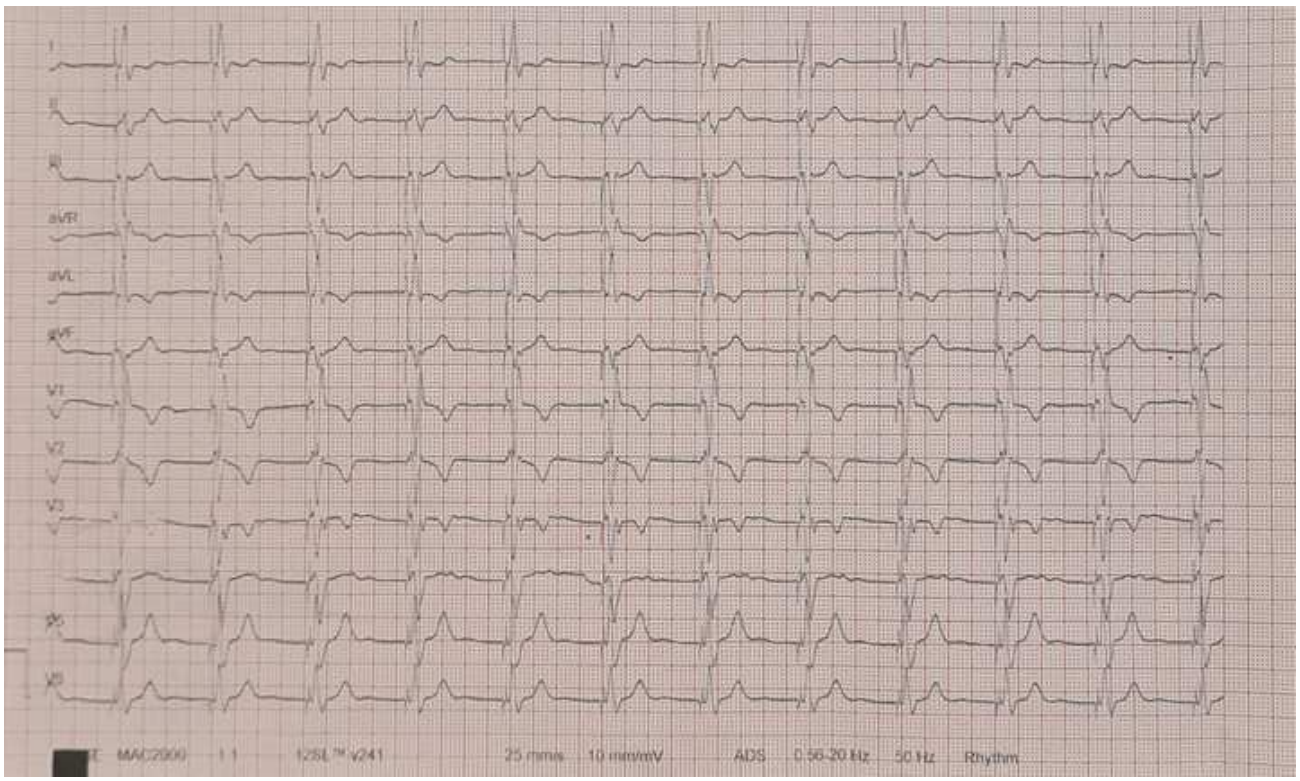

Figure 4 - The final 12-lead ECG showed a paced QRS complex with morphology suggestive of the LBB area pacing. ECG - electrocardiogram, LBB - left bundle branch.

Without electrical and mechanical atrial activity, the expected percentage of ventricular pacing is almost 100%. To avoid the development of pacing-induced cardiomyopathy, conduction system pacing is an attractive alternative for maintaining a synchronized ventricular contraction.[7] To our knowledge, few cases of LBB pacing are reported in patients with AS.[3, 8, 9]

AS with a wide QRS complex can be associated with absent His potential or inability to correct the bundle branch block at an adequate threshold with His bundle pacing. [2] Considering the narrow QRS complex in our patient, His pacing could be attempted. Despite the advantages of a physiological ventricular activation pattern, there are some well-known limitations regarding His bundle pacing, such as reduced R wave amplitudes and high and unstable pacing thresholds.[10] In our case, because of the high pacing threshold in a young patient, this approach was abandoned in favor of LBB pacing, which has excellent acute sensing and pacing parameters and long-term stability.

Due to absent atrial contractility and atrial stasis, there is a high risk of cardioembolic episodes. Despite our patient's low CHAD2S2-VASc score, the AS represents an atrial myopathy with structural changes in the atrial myocardium, requiring chronic oral anticoagulation.[11] We opted for a non-vitamin K anticoagulant.

Cardiac magnetic resonance imaging and genetic testing can provide important information on the etiology and follow-up of the family members.[12] Because of our hospital's limited access to the investigation, cardiac magnetic resonance was not performed before pacemaker implantation. It could have a more significant impact in patients with reduced LV systolic function or cardiomyopathies, along with patients with specific mutations (particularly LMNA mutation), when prophylactic defibrillator implantation could be considered.[13]

Conclusion

In summary, our case underlines the importance of the EPS in the diagnosis and appropriate treatment of the disease and the feasibility of single-chamber pacemaker implantation with LBB pacing in a young patient with AS to preserve LV synchrony.

Author Contributions

All authors have read and agreed to the published version of the manuscript.

Funding

This research received no external funding.

Informed Consent Statement

Written informed consent for the procedure and to publish this paper has been obtained from the patient.

Acknowledgments

None.

Conflicts of Interest

The authors declare no conflict of interest.

REFERENCES

1. Fuenmayor A, Rodríguez S. Atrial standstill. International journal of cardiology, 165:3; pp. e47–e48. https://doi.org/10.1016/j.ijcard.2012.10.077

2. Yaminisharif A, Shafiee A, Sahebjam M, Moezzi A. Atrial standstill: a rare case. The journal of Tehran Heart Center 2011, 6:3; pp. 152–154.

3. Zhang Y, Zhang Y, Ren M, Xue M, Hu C, Hou Y, Li Z, Qu H, Moreira P. Atrial standstill associated with lamin A/C mutation: A case report. SAGE Open Medical Case Reports 2023, 11. https://doi.org/10.1177/2050313X231179810

4. Woolliscroft J, Tuna N. Permanent atrial standstill: the clinical spectrum. The American journal of cardiology 1882, 49:8; pp. 2037–2041. https://doi.org/10.1016/0002-9149(82)90226-0

5. Suzuki Y, Takei A, Takahara H, Taniguchi Y, Ozawa T, Inoue N. A case of an atrial standstill with the atrial lead of a dual-chamber pacemaker implanted in the coronary sinus. HeartRhythm case reports 2019, 5(6), 338–342. doi.org/10.1016/j.hrcr.2019.03.008

6. Bellmann B, Roser M, Muntean B, Tscholl V, Nagel P, Schmid M, Schauerte P. Atrial standstill in sinus node disease due to extensive atrial fibrosis: impact on dual chamber pacemaker implantation. Europace 2016, 18:2; pp. 238–245. doi.org/10.1093/europace/euv098

7. Glikson M, Nielsen JC, Kronborg MB, Michowitz Y, Auricchio A, Barbash IM, et al. 2021 ESC Guidelines on cardiac pacing and cardiac resynchronization therapy. *Eur Heart J*. 2021, 42:35; pp. 3427-3520. doi.org/10.1093/eurheartj/ehab364

8. Zheng J, Yang Q, Zheng J, Chen Q, Jin Q. Left bundle branch area pacing in a giant atrium with atrial standstill: A case report and literature review. Frontiers in Cardiovascular Medicine 2022, 9; p. 836964. doi.org/10.3389/fcvm.2022.836964

9. Aronis KN, Yang E, Barnes BT, Cedars A, De La Uz CM, Barth AS. Left bundle pacing in a patient with atrioventricular canal defect presenting with atrial standstill and junctional bradycardia. HeartRhythm Case Reports 2023, 9:5; pp. 314–318. doi.org/10.1016/j.hrcr.2023.02.009

10. Yuan Z, Cheng L, Wu Y. Meta-analysis comparing safety and efficacy of left bundle branch area pacing versus His bundle pacing. Am J Cardiol 2022, 164; pp. 64-72. doi.org/10.1016/j.amjcard.2021.10.025

11. Khatoun MA, Toufayli H, Touma MJ, Nasr SR. Persistent atrium standstill post atrial fibrillation ablation therapy. Cureus 2022, 14:5; p. e25293. doi.org/10.7759/cureus.25293

12. Kim TH, Kim H, Park HS, Han S, Park NH. Atrial standstill in suspected isolated cardiac sarcoidosis. Journal of Cardiology Cases 2016, 14:5; pp. 136–138. doi.org/10.1016/j.jccase.2016.06.010

13. Ollil LH, Nikus K, Parikka H, Weckström S, Tiina H. Timing of pacemaker and ICD implantation in LMNA mutation carriers. Open Heart 2021, 8:1; p. e001622. doi.org/10.1136/openhrt-2021-001622