research article

Ultrasonography of peripheral nerve tumours: a case series

Simon Podnar

Institute of Clinical Neurophysiology, Division of Neurology, University Medical Centre Ljubljana, Ljubljana, Slovenia

Radiol Oncol 2023; 57(1): 35-41.

Received 5 August 2022
Accepted 8 December 2022

Correspondence to: Prof. Simon Podnar, M.D., Ph.D., Institute of Clinical Neurophysiology, Division of Neurology, University Medical Centre Ljubljana, Zaloška cesta 7, SI-1525 Ljubljana, Slovenia. E-mail: simon.podnar@kclj.si

Disclosure: No potential conflicts of interest were disclosed.

This is an open access article distributed under the terms of the CC-BY license (https://creativecommons.org/licenses/by/4.0/).

Background. Peripheral nerve tumours (PNTs) are rare, but important cause of peripheral nerve dysfunction. The aim of the study was to present a series of consecutive patients with PNTs evaluated in authors' ultrasonography (US) practice.

Patients and methods. The electronic medical records of patients with PNTs examined at our US laboratory from February 2013 to May 2020 were retrospectively reviewed. Data on gender, age, clinical features, PNT location, electrodiagnostic (EDx) features and US findings were collected.

Results. In the analyzed period 2845 patients were examined in our US laboratory. From these 15 patients (0.5%) with PNTs were identified. Four of them (3 with confirmed neurofibromatosis) had multiple PNTs. Half of patients (53%) presented with features of peripheral nerve damage, and others with palpable mass or pain. The most often involved nerve was ulnar (36%). PNT cross sectional areas varied from 24 mm^2 to 1250 mm^2 (median, 61 mm^2). Based in 5 patients on histological and in remaining patients on US features, schwannoma was diagnosed in 40%, neurofibroma in 27%, and perineurioma in 27% of patients.

Conclusions. As in previous reports, PNTs in our series presented with neurological symptoms, palpable mass or pain. In contrast to other focal neuropathies, particularly nerves with schwannomas, in spite of their large thickening, often demonstrated well preserved function. Adding US to our clinical practice, enabled us to diagnose these rare peripheral nerve lesions that we missed before.

Key words: electrodiagnosis; nerve cross-sectional area; peripheral nerves; peripheral nerve tumors; ultrasonography

Introduction

Peripheral nerve tumours (PNTs) are rare, but important cause of peripheral nerve dysfunction. Usually they present with neurological symptoms (muscle atrophy and weakness, paresthesia or sensory loss), palpable mass or pain.[1,2] On examination neurological deficits can be found distally to PNTs in the affected nerve innervation area. Mass movable perpendicular, but not along the peripheral nerve axis, and sensations along the affected nerve elicited on mass percussion (i.e., Tinel's sign) are also pointing to possible PNT.[1,2] Even before PNT diagnosis is known, electrodiagnostic (EDx) testing is often performed to evaluate severity of peripheral nerve damage. However, EDx is not useful for PNT diagnosis[1], but imaging studies are much more relevant. Magnetic resonance (MR) is regarded as the most useful method[1,3], although ultrasonography (US) is also gaining support among clinicians.[3,4] Particularly when diagnosis of PNT is not known, US is most useful, because it is cheap and widely accessible. Imaging delineates the lesion, identifies its relation to peripheral nerve, and helps to differentiate various types of PNTs (Table 1).[5] There are several nice reviews describing US characteristics of PNT.[3,4] However, only few publications written mainly by radiologists

describe actual clinical experiences with US diagnosis of PNTs.[5-7]

In the present study we report a series of consecutive patients referred to our US unit mainly from EDx laboratories in whom we have diagnosed PNTs.

Patients and methods

We retrospectively reviewed the electronic medical records of all patients referred from February 2013 to May 2020 to the US laboratory at the Institute of Clinical Neurophysiology, University Medical Centre Ljubljana, Slovenia. Our unit is the only one dedicated to peripheral nerve US in Slovenia, a country with a population of two million. The National Ethics Committee of Slovenia approved the study (approval code: 63/07/17), and at the time of analysis all patients signed written informed consent. During the whole review process, all patients' personal information was carefully protected.

We were not blinded to the findings of the clinical neurologic examination and EDx testing. Before US examinations we performed a focused neurological examination of patients by ourselves. We used standard US equipment (ProSound Alpha 7, Hitachi Aloka Medical, Ltd., Tokyo, Japan), with a 4–13 MHz linear array transducer. We measured tumor cross sectional areas (CSAs) by a trace method that excluded the hyperechoic rim.[8] During review of US images we observed PNT features typical for neurofibromas and schwannomas (Table 1).[5] In patients without histological diagnosis presumptive PNT diagnoses were based on clinical, EDx and particularly US features. In all included patients, we collected data on gender, age, symptoms (including duration), neurological, EDx features, US findings, and PNT location.

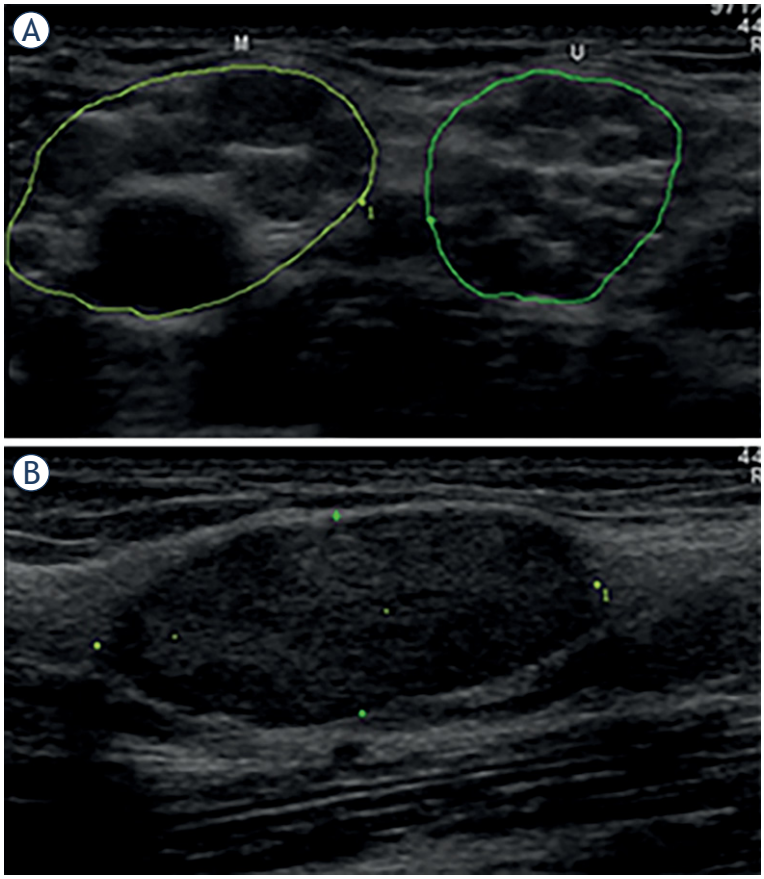

FIGURE 1. (A) Transverse ultrasonographic (US) view of the median (M) and ulnar (U) nerve in the axillary region showing numerous globular hypoechoic peripheral nerve tumours (PNTs) causing largely increased nerve cross sectional areas (CSAs, 148 mm2 and 101 mm^2, respectively). **(B)** Longitudinal view of a single partially encapsulated, slightly lobulated and rather homogenous oval PNT (length 24 mm, thickness 9 mm) with central, but poorly defined nerve-tumour transition.[5] Most probably these numerous PNTs are neurofibromas, although diagnosis in this 52-year-old woman presenting with peripheral neuropathy, primary lymphedema, and history of mitral and aortic valve surgery (patient #13, Tables 2–3), is not known yet.

Results

In the analyzed period, in our US unit we examined 2845 patients, and we found PNTs in 15 (0.5%) of them. Demographic features of individual patients, PNT anatomic, clinical, EDx and US features are shown in Table 2. Our patients' median age was 33 years (range: 16–69 years). Slightly less than half of them were male (47%). Four had multiple PNTs; in 2 neurofibromatosis type 1 (NF1), and in 1 neurofibromatosis type 2 (NF2) were previously diagnosed. In another (patient #13, Tables 2–3) gene sequencing results are pending. Of 11 patients with single PNTs, 7 (64%) had lesions on the right side. Ulnar nerve was involved in 4 (36%), median, sciatic and tibial in 2 (18%) patients each, and fibular in 1 (9%) patient with single PNT. Elbow and forearm were each involved in 3 (27%), thigh and ankle in 2 (18%) patients each, and knee in 1 (9%) patient with single PNT. The most common clinical findings in our patients were weakness and sensory abnormalities, each found in 7 (47%) patients, followed by muscle atrophy in 6 (40%), pain in 3 (20%), sensitivity on mass percussion in 2 (13%) and only palpable mass in 1 patient (7%). At the time of US study, EDx report was available for 12 (80%) patients. Affected nerve compound muscle action potential (CMAP) amplitude was markedly

reduced or absent in 5 (42%) patients, and sensory nerve action potential (SNAP) amplitude in 9 (75%) patients. In our series CSAs of PNT varied from 24 mm^2 to 1250 mm^2 (median, 61 mm^2). Ratio of PNT/unaffected segment of the same nerve CSA varied from 2.9 to 156 (median, 6.0). Morphological features of PNTs are presented in Table 3. Ratio of maximum/minimum PNT diameter varied from 1.5 to > 10 (median, 4.5). Majority (64%) of PNTs were of fusiform shape. PNT contour was smooth in 8 (53%), and lobulated in remaining 7 (47%). PNT encapsulation was complete in 7 (47%), partial in 6 (40%), and absent in 2 (13%). PNTs echotexture was heterogenous in 13 (87%). Nerve entrance into PNT was central in 10 (67%), eccentric in 3 (20%), and not possible to asses in 2 (13%). In our series infiltrative nerve-tumor transition was observed in 7 PNTs (58%), poorly defined in 5 (42%), and could not be observed in 3 (20%). Histological diagnosis was available in 5 patients (Tables 2 and 3) with schwannoma. In another patient with NF1 histology of multiple PNTs could be also established –

TABLE 1. Morphological features useful for differentiation between neurofibromas and schwannomas[5]

Peripheral nerve tumor (PNT) feature	Comment
Maximum to minimum diameter	Ratio > 3 → neurofibroma
Shape: round, oval, fusiform	Fusiform → neurofibroma
Contour: smooth, lobulated	Lobulated → neurofibroma
Encapsulation: absent, partial, complete	Complete → schwannoma
Echogenicity: hypo-, iso-, hyper-	Hypoechoic → PNT
Echo texture: homogenous, heterogenous	Heterogenous → schwannoma
Cystic changes: absent, focal, partial, large	Cystic changes → schwannoma
Calcifications: absent, present	Present → schwannoma
Target sign: absent, present	
Nerve entrance: not identified, identified	
Nerve-tumor position: central, eccentric	Central → neurofibroma
Nerve-tumor transition: clear, poorly defined, infiltrative	Infiltrative → neurofibroma
Vascularity: increased, normal, decreased	Hypovascular → neurofibroma

TABLE 2. Demographic, anatomical, clinical, electrodiagnostic (EDx) and ultrasonographic (US) features of patients with peripheral nerve tumors (PNTs)

#	Gender	Age	Side	Nerve	Location	Symptoms & Signs	CMAP amp. (mV)	SNAP amp. (μV)	Tumor CSA (mm^2)	Tumor diagnosis	Other
1	Male	69	R	Ulnar	Elbow	AWS			43	Neurofibroma	
2	Male	24	L	#Radial	Upper arm	W	0.2	4	24	Schwannoma*	NF2
3	Male	66	R	Median	Forearm	Æ	6.9	5	49	Schwannoma	
4	Male	16	L	#Median	Upper arm	WS			61	Neurofibroma	NF1
5	Female	26	R	Ulnar	Forearm	AWS	0.2	0	30	Perineurioma	
6	Female	18	L	Sciatic	Thigh	AWS	0.4	0	109	Perineurioma	
7	Female	18	R	Fibular	Knee	AWS	0	0	47	Perineurioma	
8	Male	47	L	Ulnar	Elbow	M	7.6	3	348	Schwannoma*	
9	Female	58	R	Median	Forearm	P	7.6	16	45	Neurofibroma	
10	Female	22	R	Sciatic	Thigh	AWS	0	0	97	Perineurioma	
11	Female	34	R	Tibial	Ankle	PAWS	10.6	7	1250	Schwannoma*	
12	Male	63	L	Ulnar	Elbow	L	8.2	5	368	Schwannoma*	
13	Female	52	R	#Ulnar	Forearm		6.2	12	212	Neurofibroma	NF?
14	Male	24	R	#Median	Upper arm	P	6.3	33	26	Neurofibroma*	NF1
15	Female	33	L	Tibial	Ankle	L			92	Schwannoma	

A = muscle atrophy; amp. = amplitude; CMAP = compound muscle action potential; CSA = cross sectional area; L = left; L = local sensitivity; M = palpable mass; NF1 = neurofibromatosis type 1; NF2 = neurofibromatosis type 2; P = pain; R = right; S = sensory loss; SNAP = sensory nerve action potential; W = weakness; # = patients had multiple tumors; * = histological diagnosis of PNT available

TABLE 3. Morphological features of peripheral nerve tumors (PNTs) found on ultrasonographic (US) examination[5] of individual patients

#	Ratio	Shape	Contour	Encapsulation	Echo texture	Nerve position	Nerve transition	Number	Tumor diagnosis
1	5	Fusiform	Lobulated	Partial	Heterogeneous	Central	Infiltrative	Single	Neurofibroma
2	?		Lobulated	Partial	Heterogeneous	?	?	Several	Schwannoma*
3	6	Fusiform	Smooth	Whole	Heterogeneous	Central	Poorly defined	Single	Schwannoma
4	6	Fusiform	Fusiform	None	Heterogeneous	Central	Infiltrative	Several	Neurofibroma
5	8	Fusiform	Lobulated	Partial	Heterogeneous	Central	Infiltrative	Single	Perineurioma
6	> 10	Fusiform	Lobulated	Partial	Heterogeneous	?	?	Single	Perineurioma
7	6	Fusiform	Smooth	None	Homogenous	Central	Infiltrative	Single	Perineurioma
8	3	Oval	Smooth	Whole	Heterogeneous	Central	Poorly defined	Single	Schwannoma*
9	> 10	Fusiform	Lobulated	Partial	Heterogeneous	Eccentric	Infiltrative	Single	Neurofibroma
10	5	Fusiform	Smooth	Whole	Heterogeneous	Central	Infiltrative	Several	Perineurioma
11	1,5	Oval	Smooth	Whole	Homogenous	Eccentric	?	Single	Schwannoma*
12	2,5	Oval	Smooth	Whole	Heterogeneous	Central	Poorly defined	Single	Schwannoma*
13	2,5	Oval	Smooth	Whole	Heterogeneous	Central	Poorly defined	Several	Neurofibroma
14	4	Fusiform	Lobulated	Partial	Heterogeneous	Central	Infiltrative	Several	Neurofibroma*
15	1,7	Oval	Smooth	Whole	Heterogeneous	Eccentric	Poorly defined	Single	Schwannoma

Ratio = Maximum/minimum PNT diameter; * = histological diagnosis of PNT available

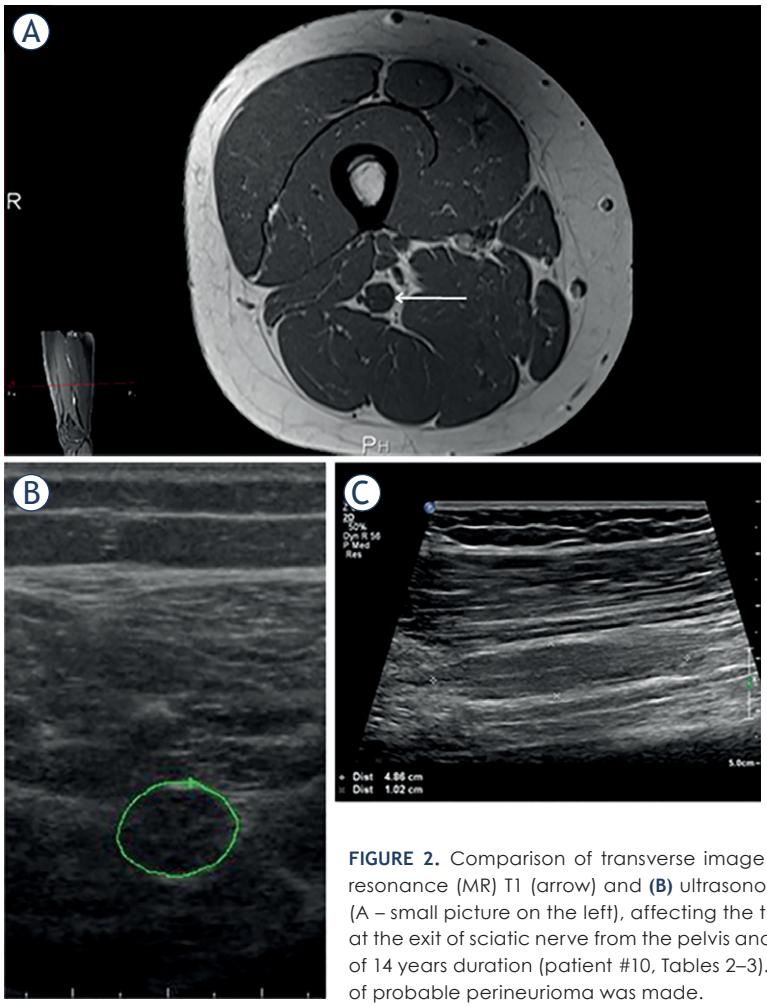

FIGURE 2. Comparison of transverse image of the sciatic peripheral nerve tumour (PNT) on **(A)** magnetic resonance (MR) T1 (arrow) and **(B)** ultrasonography (US). **(C)** Longitudinal US view of PNT in the middle thigh (A – small picture on the left), affecting the tibial portion of sciatic nerve. In this 22-year-old girl MR revealed at the exit of sciatic nerve from the pelvis another PNT affecting its fibular portion, and causing right foot drop of 14 years duration (patient #10, Tables 2–3). Based on clinical and imaging features in this patient diagnosis of probable perineurioma was made.

neurofibroma. Based on histological definite, and based on clinical and US features probable diagnoses of schwannoma were made in 6 (40%), neurofibroma in 5 (27%), and perineurioma in 4 (27%) patients.[5]

Discussion

PNTs are known to be rare, which was also confirmed by our US experience, demonstrating PNTs in only every 200th examined patient. As in our US laboratory we see referrals from a number of Slovenian EDx laboratories, and examine primarily patients with unclear etiology of peripheral nerve lesions, in reality PNTs are probably even rarer. It was reported that PNTs constitute only 5% of adult, and 2% of pediatric upper extremity tumors.[9]

With median age of 33 years our patients were much younger compared to typical oncological patients, which is similar to previously reported series of patients with PNTs reporting mean age of 36 years[10], and 37 years.[7] As reported by others[7,10], we also found equal distribution of PNTs between both genders.

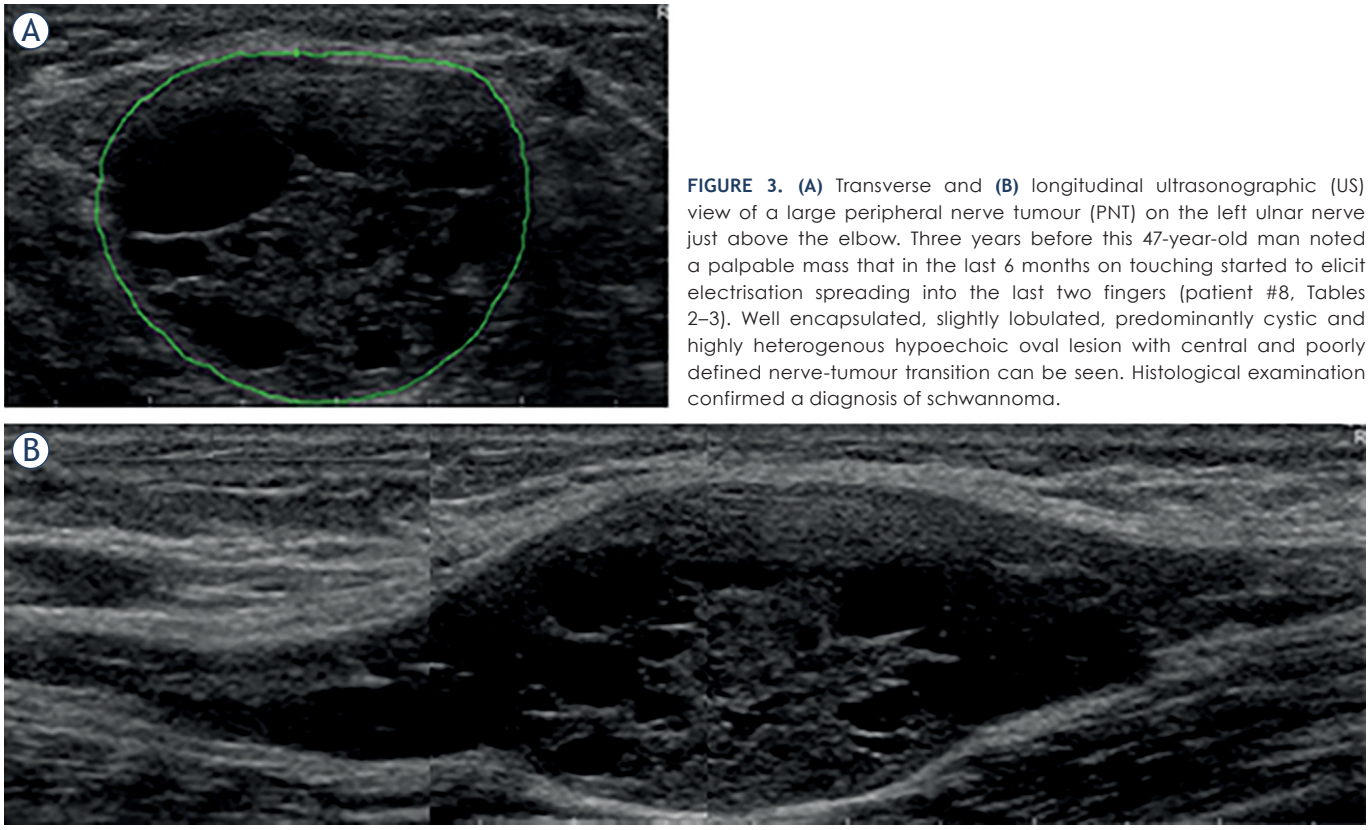

FIGURE 3. (A) Transverse and **(B)** longitudinal ultrasonographic (US) view of a large peripheral nerve tumour (PNT) on the left ulnar nerve just above the elbow. Three years before this 47-year-old man noted a palpable mass that in the last 6 months on touching started to elicit electrisation spreading into the last two fingers (patient #8, Tables 2–3). Well encapsulated, slightly lobulated, predominantly cystic and highly heterogenous hypoechoic oval lesion with central and poorly defined nerve-tumour transition can be seen. Histological examination confirmed a diagnosis of schwannoma.

We could divide our patient cohort into several groups. The first group consisted of 4 patients with numerous PNTs in several peripheral nerves. Two of patients from this group with numerous neurofibromas had known NF1 and a single patient with schwannomas had NF2. Diagnosis in a remaining patient (#13), with numerous neurofibromas in all US examined peripheral nerves (Figure 1), has not been established yet.

The second group consisted of three girls (patients #6, 7, 10) presenting in the first decade of life with unilateral foot drop. Each of them had several lumbo-sacral spine MRs that all proved negative, and their PNTs were not diagnosed until they presented to our US laboratory 8–15 years after symptom onset. At that time their clinical features were unchanged for several years, so none of them decided to have a nerve biopsy to establish a histological PNT diagnosis. Nevertheless, we believe these 3 patients most probably have sciatic nerve perineurioma.[11] One of them (patient #10) had two PNTs, separated by 20–30 cm segment of US relatively normal sciatic nerve. Using US we demonstrated the more distal PNT of the tibial portion of sciatic nerve (Figure 2). Additional more proximal PNT affecting fibular portion of sciatic nerve, and causing foot drop was found on MR.

The third group consisted of four patients with PNTs on the ulnar nerve in the elbow segment (Figure 3). The main challenge in this group of patients is differentiation of PNTs from ulnar neuropathy at the elbow (UNE) due to entrapment under the humeroulnar aponeurosis (i.e., cubital tunnel syndrome). The main distinctive feature of PNTs is their large CSA (43 mm^2, 348 mm^2, 45 mm^2, and 368 mm^2). We found CSA larger than 40 mm^2 in only 1 of 202 (0.5%) UNE patients,[12] and is therefore extremely rare. Another characteristic feature of PNTs is rather well preserved nerve function in spite of large nerve thickening. By contrast, large CSA in UNE is as a rule accompanied by severe nerve dysfunction.[12] What is the reason for such high number of PNTs on ulnar nerve in the elbow area is not clear. One possibility would be exposure of the nerve in this segment to mechanical stress. Alternative explanation would be a sampling artefact, as we see a plenty of patients with suspected UNE. If the latter case that would mean that a large number of PNTs on other nerves and locations are still missed.

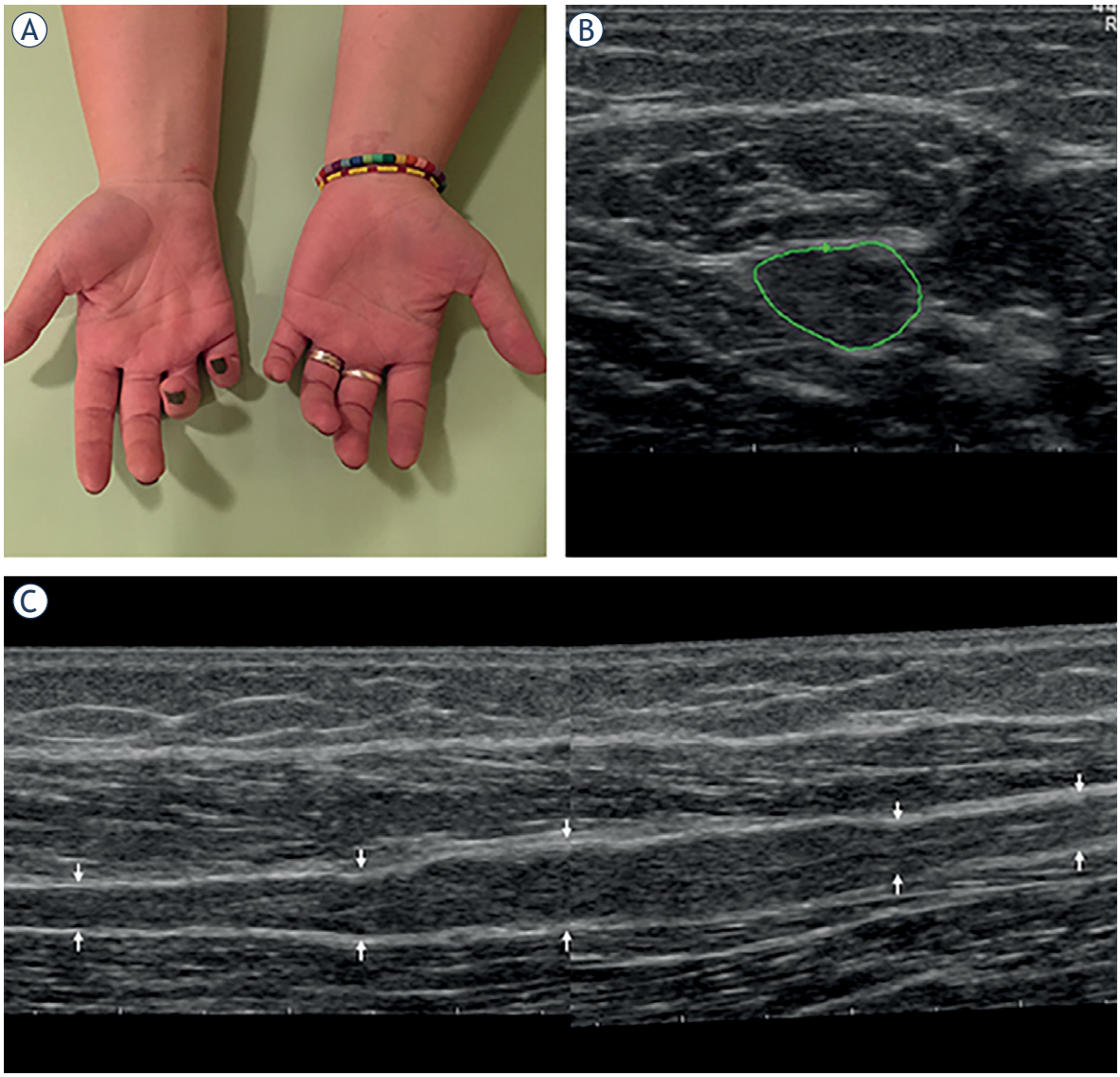

FIGURE 4. (A) Hands of a 26-year-old woman with 4-year history of muscle atrophy, weakness and numbness in the distal ulnar nerve territory (patient #5, Tables 2–3). Note intrinsic right palm muscle atrophy and clawing of the last two fingers. **(B)** On transverse ultrasonographic (US) view ulnar nerve cross sectional area (CSA) increased from 7 mm^2 both proximally and distally to 20 mm^2 in the middle of the lesion. **(C)** On longitudinal view a partially encapsulated, lobulated, fusiform hypoechoic right ulnar peripheral nerve tumour (PNT) of the forearm can be seen. Based on clinical and US features, we made a diagnosis of probable perineurioma.

Of remaining 4 patients, 1 had definite and another probable tibial nerve schwannoma at the ankle, which is again a region of considerable mechanical stress. Another young woman had a fusiform thickening of the ulnar nerve in the forearm (patient #5, Figure 4). She had surgical release of the ulnar nerve exit from the flexor carpi ulnaris muscle, with no apparent benefit. She might also have perineurioma, or less likely neurofibroma. In the fourth man probable median nerve schwannoma in the forearm was a coincidental finding during US evaluation due to Lewis-Sumner syndrome, and caused no additional symptoms.

As described previously[1] according to clinical presentation, our patients could be divided into two groups. Eight (53%) patients presented with features of peripheral nerve lesion (e.g., muscle atrophy, weakness, sensory loss). Remaining 7 patient presented by other clinical features (i.e., pain, local sensitivity, palpable mass), or as coincidental

PNT finding without symptoms. In the first group CMAP and SNAP amplitudes of affected nerves were severely reduced or absent (42% and 75%, respectively), and in the second group they were mainly preserved (58% and 25%, respectively). The first group consisted of all 4 young women with probable perineurioma, and additional 3 patients with probable neurofibroma. By contrast, majority of the second group consisted of 4 patients with probable or definite schwannoma (Table 2).

Before introduction of US into our institution, we diagnosed PNTs only very rarely. This changed after we started to perform US studies. Some PNTs that we finally diagnosed using US, were causing patients' unexplained severe nerve dysfunction for more than a decade. Without US we would probably not be able to diagnose PNTs in majority of patients from this series, and some of them would probably remain without diagnosis to this day.

The main limitation of the present study was that in majority of patients histological diagnosis of PNTs was not available. Therefore, in these patients we based our PNT diagnoses on clinical and particularly imaging features of the lesions. For differentiation between schwannomas and neurofibromas we applied US criteria of Ryu *et al*. that demonstrated high diagnostic accuracy.[5] Unfortunately, no similar criteria are available for US diagnosis of perineurioma. Another limitation of the present study was its retrospective design; at the time of image analysis all projections needed for optimal differentiation between schwannomas and neurofibromas were therefore not available (Table 3).

In conclusion, the present study confirmed that PNTs are rare, but important cause of peripheral nerve dysfunction. We found US critically important for demonstration of PNTs, and published US criteria as useful to differentiate schwannomas from neurofibromas. Unfortunately, no such criteria are available for perineuriomas. PNTs are most likely when their continuity with peripheral nerves is demonstrated, and discrepancy between lesions' large size and well preserved nerve function is found.

Acknowledgments

Author thanks Dr. Gregor Omejec for collaboration in performance of US examinations, and Mr. Boštjan Kastelic for help with preparing of figures. The author is supported by the Republic of Slovenia Research Agency, Grant No. P3-0338.

References

1. July J, Guha A. Peripheral nerve tumors. *Handb Clin Neurol* 2012; **105:** 665-74. doi: 10.1016/b978-0-444-53502-3.00016-1
2. Kubiena H, Entner T, Schmidt M, Frey M. Peripheral neural sheath tumors (PNST) – what a radiologist should know. *Eur J Radiol* 2013; **82:** 51-5. doi: 10.1016/j.ejrad.2011.04.037
3. Abreu E, Aubert S, Wavreille G, Gheno R, Canella C, Cotten A. Peripheral tumor and tumor-like neurogenic lesions. *Eur J Radiol* 2013; **82:** 38-50. doi: 10.1016/j.ejrad.2011.04.036
4. Gruber H, Glodny B, Bendix N, Tzankov A, Peer S. High-resolution ultrasound of peripheral neurogenic tumors. *Eur Radiol* 2007; **17:** 2880-8. doi: 10.1007/s00330-007-0645-7
5. Ryu JA, Lee SH, Cha EY, Kim TY, Kim SM, Shin MJ. Sonographic differentiation between Schwannomas and neurofibromas in the musculoskeletal system. *J Ultrasound Med* 2015; **34:** 2253-60. doi: 10.7863/ultra.15.01067
6. Telleman JA, Stellingwerff MD, Brekelmans GJ, Visser LH. Nerve ultrasound in neurofibromatosis type 1: a follow-up study. *Clin Neurophysiol* 2018; **129:** 354-9. doi: 10.1016/j.clinph.2017.11.014
7. Reynolds DL, Jr., Jacobson JA, Inampudi P, Jamadar DA, Ebrahim FS, Hayes CW. Sonographic characteristics of peripheral nerve sheath tumors. *AJR Am J Roentgenol* 2004; **182:** 741-4. doi: 10.2214/ajr.182.3.1820741
8. Omejec G, Zgur T, Podnar S. Diagnostic accuracy of ultrasonographic and nerve conduction studies in ulnar neuropathy at the elbow. *Clin Neurophysiol* 2015; **126:** 1797-804. doi:
9. Forthman CL, Blazar PE. Nerve tumors of the hand and upper extremity. *Hand Clin* 2004; **20:** 233-42, v. doi: 10.1016/j.hcl.2004.03.003
10. Pedro MT, Antoniadis G, Scheuerle A, Pham M, Wirtz CR, Koenig RW. Intraoperative high-resolution ultrasound and contrast-enhanced ultrasound of peripheral nerve tumors and tumorlike lesions. *Neurosurg Focus* 2015; **39:** E5. doi: 10.3171/2015.6.focus15218
11. Salvalaggio A, Cacciavillani M, Coraci D, et al. Nerve ultrasound and 3D-MR neurography suggestive of intraneural perineurioma. *Neurology* 2016; **86:** 1169-70. doi: 10.1212/wnl.0000000000002488
12. Omejec G, Podnar S. Utility of nerve conduction studies and ultrasonography in ulnar neuropathies at the elbow of different severity. *Clin Neurophysiol* 2020; **131:** 1672-7. doi: 10.1016/j.clinph.2020.02.019