Case report • DOI: 10.2478/pneum-2023-0024 • 71 • 2022 • 76-80

Pneumologia

Coexistence of multiple forms of tuberculosis – a delayed diagnosis

Militaru Laura Amalia[1,*], Vastag Emanuela[1,2], Oancea Cristian[1,2]

[1]Department of Pulmonology, Clinical Hospital for Infectious Diseases and Pneumophtisiology "Dr. Victor Babes", Timișoara, Romania
[2]Department of Pulmonology, Center for Research and Innovation in Precision Medicine of Respiratory Diseases, "Victor Babes" University of Medicine and Pharmacy Timisoara, Eftimie Murgu Square 2, 300041 Timișoara, Romania

Abstract

English:

Introduction: *Tuberculosis (TB) can be located in any segment of the osteoarticular system, being the most common in the spine, with approximately 50% of cases. In only 10% of the cases of osteoarticular TB the location is multiple; generally, it is monoarticular or located at the level of a single segment of the spine. The diagnosis can be delayed in the early stages due to its varied and hidden presentation and the probability of being confused with other pathologies of the osteoarticular system. Delay in diagnosis can lead to chronic pain, joint destruction and progression to symptomatic bony ankylosis.*
Case Presentation**:** *A 64-year-old man presented with left lower limb, coccyx pain and peri-anal discharge. CT scan of the pelvis showed recto-integumentary perianal fistulous trajectory externalised on the left side of the anus and osteomyelitis. Left ankle CT: Cystic image of approximately 4.2/6/10 cm well-demarcated, with some central microcalcifications, located in the postero-tibial soft parts, communicating with the tibiotalar joint.*
Conclusion: *This case highlights the importance of considering TB as a diagnosis if unusual sites are involved.*

Keywords

osteoarticular tuberculosis • multiple locations • cold abscess • perianal fistulas

Coexistența multiplelor forme de tuberculoză – Un diagnostic întârziat

Rezumat

Romanian:

Introducere: *Tuberculoza poate fi localizată în orice segment al sistemului osteoarticular, cel mai frecvent fiind în coloana vertebrală, aproximativ 50% din cazuri. În doar 10% din cazurile de tuberculoză osteoarticulară, localizarea este multiplă, în general este monoarticulară sau localizată la nivelul unui singur segment al coloanei vertebrale. Diagnosticul poate fi întârziat în stadiile incipiente datorită prezentării sale variate și ascunse și a probabilității de a fi confundat cu alte patologii ale sistemului osteoarticular. Întârzierea diagnosticului poate duce la durere cronică, distrugere articulară și progresie către anchiloză osoasă simptomatică.*
Prezentarea Cazului: *Un bărbat de 64 de ani s-a prezentat cu durere la membrul inferior stâng, coccis și scurgere peri-anală. Scanarea CT a pelvisului a arătat o traiectorie fistuloasă recto-integumentară perianală externalizată pe partea stângă a anusului și osteomielită. CT glezna stângă: Imagine chistică de aprox. 4.2/6/10 cm bine delimitată, cu unele microcalcificări centrale, localizată în părțile moi postero-tibiale, comunicând cu articulația tibiotalară.*
Concluzie: *Acest caz subliniază importanța considerării tuberculozei ca diagnostic dacă sunt implicate localizări neobișnuite.*

Cuvinte-cheie

Tuberculoză osteo-articulară • localizare multiplă • abces rece • fistule perianale

Introduction

Tuberculosis (TB) is an infectious-contagious condition, potentially fatal if untreated, endemic and mainly localised in the lungs, although it can affect almost any organ in the body. Extrapulmonary TB localised in the osteoarticular system is present in only 1%–3% of cases. The most common form of extrapulmonary TB of the osteoarticular system is located at the

*Corresponding author: Militaru Laura Amalia
E-mail: militarulaura74@yahoo.com

Open Access. © 2022 Amalia et al., published by Sciendo
This work is licensed under the Creative Commons Attribution-NonCommercial-NoDerivs 4.0 License.

level of the spine, with up to 50% of cases being encountered at this level. The foot and ankle are relatively rare sites, with incidence in the literature ranging from 3% to 6%–7% to 12% (1,2). TB is generally monoarticular or localised to a single segment of the spine; however, in approximately 10% of cases multiple lesions can be detected, both clinically and radiologically (3,4). This makes the problem a rare one, and the ability of TB to mimic other diseases combined with a lack of awareness on the part of the attending physician often leads to delays in diagnosis (1,5).

If osteoarticular TB is diagnosed and treated at an early stage, about 90%–95% of patients would achieve healing, with near-normal function of the affected segment. The main treatment of osteoarticular TB is anti-tubercular therapy (from 12 months to 18 months) and musculoskeletal rehabilitation for the affected joint throughout the healing period (3). Surgical intervention is necessary when the patient does not respond after 4–5 months of pharmacological treatment, the therapeutic outcome is not satisfactory or the healing state has resulted in a painful ankylosis (6).

In this article, we will describe a rare case of osteoarticular TB with multiple localisation, both at the coccygeal (which was difficult to differentiate from a persistent anal fistula) and tibio-talar levels.

Clinical problems – Differential diagnosis

We present the case of a 64-year-old male patient former smoker and chronic drinker, who first presented to the Hospital for Infectious Disease and Pneumophthisology Dr. Victor Babeș' presenting mMRC2 dyspnoea, predominantly dry cough, significant weight loss of approximately 20 kg over the course of a year, asthenia, fatigue and pain in the left lower limb and in the coccyx area for approximately 3–4 months. Personal medical history revealed that the patient was previously diagnosed with fistulised and abscessed Chron's disease and left ileostoma. The physical examination of the patient revealed an altered general state, cachexia (BMI = 14.69 kg/m^2), pale and dry skin, perianal fistulas (Figure 1) and a tumoral lesion with liquid content at the level of the left ankle (Figure 2) and abdominal pain syndrome.

Blood tests showed an important inflammatory syndrome and anaemia. The chest CT scan (Figures 3,4) showed diffuse interstitial-alveolar infiltrates with a tendency to confluence and condensation, which alternate with pulmonary nodules that are diffusely contoured, some excavated inside, with obvious drainage bronchi, having various sizes dispersed throughout the bilateral lung parenchyma – the appearance advocates for an evolutionary bacillary infectious process. Pleurisy was found in small amounts in the postero-basal left lung.



Figure 1. Peri-anal inspection. There were multiple fistulous orifices between the anus and the coccyx.



Figure 2. Peritibial cold abscess in the left lower limb.

A CT scan of the pelvis (Figure 5) showed recto-integumentary perianal fistulous trajectory externalised on the left side. Osteomyelitis-type changes at the coccygeal level with changes in the bone structure and multiple intra- and periosseous air bubbles with changes in the adjacent fatty tissue and continuity defect were found at the integumentary level.

Left ankle CT scan (Figure 6): Cystic image of approximately 4.2/6/10 cm well-demarcated, with some central microcalcifications, located in the postero-tibial soft parts, communicating with the tibio-talar joint, with thin walls and parietal hypercaptant after contrast administration. Multiple cystic images with the same characteristics located adjacent



Figure 3. Chest CT scan.

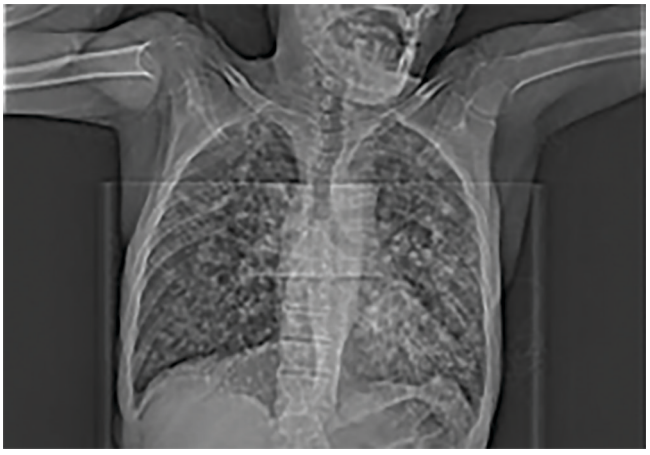

Figure 4. Chest CT scan.

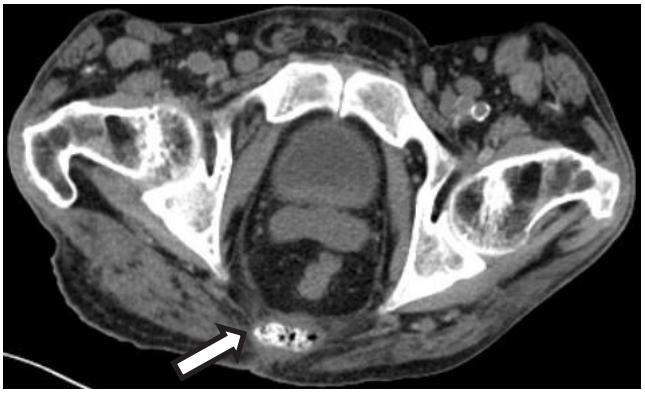

Figure 5. Pelvic CT scan.

to the tibiotalar and talofibular joints. Changes suggestive of arthritis with lobulated (parietal hypercapturing) collections, without being able to exclude suprainfection. Tibio and



Figure 6. Left ankle CT scan.

talo-fibular intra-articular fluid accumulation. Osteoarthritis changes with joint space narrowing and osteogenic production. Irregularity of the bone surface at the tibio-talar and talo-fibular joint slopes. Diffuse bone demineralisation of the skeleton of the examined region.

The diagnosis of certain cases of osteoarticular TB may not be simple due to the similarity of the clinical and radiological imaging with other entities such as subacute monoarticular arthritis, chronic abscess and chronic osteomyelitis. In this patient's case, the differential diagnosis included persistent perianal fistulas and abscesses of another aetiology. Definitive diagnosis was based on TB testing of sputum, purulent fluid from the abscess and perianal fistulas.

Result of clinical findings

Bacteriological examination for *Mycobacterium tuberculosis* from sputum is Positive in microscopy (A3+, B2+) and in genetic test (GeneXpert detected high).

From the level of the perianal fistulas (Figure 1), the secretion collected from the wound for bacteriological examination for *M. tuberculosis* was Positive in microscopy (A2+), and in genetic test (GeneXpert detected high), 30 colonies were detected on Lowenstein Jensen medium, positive in liquid medium (MGIT).

At the level of the peritibial formation (Figure 2), an aspiration puncture is performed with the evacuation of 150 mL of purulent fluid, collected for bacteriological examination for *M. tuberculosis* with positive result in microscopy (A 8 BAAR, B1+) and in genetic test (GeneXpert detected high), A 20 colonies B 30 colonies were detected on Lowenstein Jensen medium, positive in liquid medium (MGIT).

Following the clinical presentation and investigations, the patient was diagnosed with ulcerated nodular infiltrative, bilaterally extended secondary pulmonary TB and extrapulmonary coccygeal and left tibiotalar osteoarticular TB. The patient was treated with Anti-Tubercular Therapy according to the National Guidelines, vitamins, intravenous electrolyte rebalancing, gastric and liver protectors with monitoring of liver function. The patient had a favourable outcome. After 2 months of treatment, the pain and swelling gradually subsided and the lesions progressively healed. Two years after the treatment the subject is able to walk.

Discussion

TB remains a persistent infectious disease of global importance and is still a challenge for both clinicians and radiologists due to its nonspecific and diverse clinical manifestations that can mislead the diagnosis and management of this condition (4).

Osteoarticular TB is most commonly a secondary infection from a primary site, such as the lungs or less commonly from the kidney or gastrointestinal tract (7). The underlying histopathological lesion is a tubercle, which shows an area of necrosis surrounded by epithelial cells, Langhans giant cells and lymphocytes, and develops in response to Koch's bacillus (8). A cold abscess is formed by the collection of liquefaction products and the marked exudative reaction observed in some cases of osteoarticular TB. Because most of the leg bones are superficial, cold abscesses drain like sinuses at an early stage (1).

TB usually begins as a periarticular granuloma that is difficult to diagnose at an early stage. Delays in diagnosis and treatment lead to joint damage, with associated complications such as joint stiffness or the development of an external sinus (6,9). In this case, the ankle CT (Figure 6) shows an arthritis with lobulated collections, with irregularity of the bone surface at the level of the tibio-talar and talo-fibular joint slopes, and diffuse bone demineralisation of the skeleton of the examined region, which indicates an advanced stage of the disease with functional impotence of the affected member.

In addition, this patient has a second localisation at the osteoarticular level, in the coccyx bone. Coccygeal TB is a very rare form, with few cases described in the literature as a perianal fistula (5) (Figure 1). The diagnosis is generally made through invasive procedures such as biopsy; in the case of this patient no such procedure was needed (10,11).

The peculiarity of the case is the triple localisation: pulmonary, one in the coccyx and the another one at the tibio-talar level; in most cases the osteoarticular TB is monoarticular or in a localised segment of the vertebral column, whereas in only 10% of patients multiple lesions appear (8).

The bacteriological examination for MTB from pathological products such as synovial fluid, para-articular abscesses and bone fragment is positive in only 25%–30% of cases; this patient had both positive smears and cultures from the level of perianal fistulas and peritibial abscess (12,13).

If osteoarticular TB is diagnosed and treated at an early stage, approximately 90%–95% of patients would not experience complications. When the disease is active, radiographs will reveal nonspecific features: osteoporosis, lytic areas of destruction and erosions along the joint margins. Anti-tubercular therapy can cure the early stages of the disease with almost complete resolution, but about 2% of cases may experience reactivation or recurrence of infection in any part of the body (14,15).

Conclusions

Osteoarticular TB is a challenge for public health systems as the diagnosis can be difficult to make. In order to improve the therapeutic approach, an integrated and detailed analysis of the clinical and morphological aspects is necessary, so that the time between the development of a presumptive diagnosis at admission and the one of certainty should be as short as possible.

The diagnosis of osteoarticular TB may not be simple due to the similarity of the clinical or radiological features with other entities such as subacute monoarticular arthritis, chronic abscess or chronic osteomyelitis. Local pain, oedema and movement limitation of the affected segment may precede radiological changes by approximately 4–8 weeks. A high index of suspicion, careful clinical examination, radiographs and modern imaging modalities can help to establish the diagnosis of early-stage osteoarticular TB.

Funding

None.

Authors contributions

All author have contributed equally to this work.

Conflicts of interest

The authors declare no conflict of interest.

Informed consent statement

Informed consent was obtained from all subjects involved in the study.

References

1. Dhillon MS, Tuli SM. Osteoarticular tuberculosis of the foot and ankle. *Foot and Ankle International*. 2001;22(8): 679–686. doi:10.1177/107110070102200812.
2. Jain VK, Iyengar KP, Botchu R, Vaishya R. Sacroiliac joint tuberculosis revisited – a clinico-radiological review. *Journal of Clinical Orthopaedics and Trauma*. 2021;24: 101707. doi:10.1016/j.jcot.2021.101707.
3. Tuli SM. General principles of osteoarticular tuberculosis. *Clinical Orthopaedics and Related Research*. 2002;398: 11–19. doi:10.1097/00003086-200205000-00003.
4. Ehara S. Osteoarticular tuberculosis. *Seminars in Musculoskeletal Radiology*. 2001;5(2): 107–112. doi:10.1055/s-2001-15662.
5. Takakura Y, Fujimori M, Okugawa K, Egi H, Ohdan H, Kaneko S, et al. Rare case of sacrococcygeal tuberculosis mimicking as an anal fistula. *International Journal of Surgery Case Reports*. 2018;49: 74–77. doi:10.1016/j.ijscr.2018.05.033.
6. Kamal AF, Oktari PR, Kurniawan A, Kodrat E, Mumpuni NA. Clinical outcomes of delayed osteoarticular tuberculosis: a review of 30 cases. *Orthopedic Research and Reviews*. 2022;14: 351–363.
7. Procopie I, Popescu EL, Huplea V, Pleșea RM, Ghelase ȘM, Stoica GA, et al. Osteoraticular tuberculosis-brief review of clinical morphological and therapeutic profiles. *Current Health Sciences Journal*. 2017;43(3): 171–190. doi:10.12865/CHSJ.43.03.01
8. Faroug R, Psyllakis P, Gulati A, Makvana S, Pareek M, Mangwani J. Diagnosis and treatment of tuberculosis of the foot and ankle – a literature review. *The Foot*. 2018;37: 105–112. doi:10.1016/j.foot.2018.07.005.
9. Agashe VM, Johari AN, Shah M, Anjum R, Romano C, Drago L, et al. Diagnosis of osteoarticular tuberculosis: perceptions, protocols, practices, and priorities in the endemic and non-endemic areas of the world – a WAIOT view. *Microorganisms*. 2020;8(9): 1312. doi:10.3390/microorganisms8091312.
10. Cataño J, Sanchez-Bautista J. Osteoarticular tuberculosis. *The American Journal of Tropical Medicine and Hygiene*. 2022;106(6): 1575–1576. doi:10.4269/ajtmh.21-1258.
11. Kumar K. Spinal tuberculosis, natural history of disease, classifications and principles of management with historical perspective. *European Journal of Orthopaedic Surgery and Traumatology*. 2016;26(6): 551–558.
12. Hu S, Guo J, Ji T, Shen G, Kuang A. Multifocal osteoarticular tuberculosis of the extremities in an immunocompetent young man without pulmonary disease: a case report. *Experimental and Therapeutic Medicine*. 2015;9(6): 2299–2302. doi:10.3892/etm.2015.2425.
13. Magnussen A, Amirthanayagam T, Sofat R. Osteoarticular tuberculosis: the great mimicker still catches us out – a case report. *Acta Orthopaedica*. 2016;87(1): 83–84.
14. Sbai MA, Benzarti S, Bouzaidi K, Sbei F, Maalla R. A rare localization of tuberculosis of the wrist: the scapholunate joint. *International Journal of Mycobacteriology*. 2015;4(2): 161–164.
15. Dhammi IK, Kumar S. Current concepts in diagnosis & management of osteoarticular tuberculosis. *Orthopaedic Journal of MP Chapter*. 2020;26(1): 3–13.