sciendo Internal Medicine 2023 vol. XX No. 1 - www.srmi.ro 81
10.2478/inmed-2023-0240

MYELOPROLIFERATIVE SYNDROME - A DIAGNOSIS ON THE BORDER BETWEEN MEDICAL SPECIALTIES

Marilena Stoian[1, 2], Andrei Turbatu[2, 3], Bianca Procopiescu[1], Silviu Șeitan[1], Gabriel Scarlat[1],
[1]„Dr. Ion Cantacuzino" Clinical Hospital, Bucharest, Romania
[2]„Carol Davila" University of Medicine and Pharmacy, Bucharest, Romania
[3]Colțea Clinical Hospital, Bucharest, Romania
Correspondent address: marilenastoian@yahoo.com

Abstract

Background. *Myeloproliferative disorders define a vast and heteregenous group of neoplastic entities, characterized by malignant proliferation of blood cells. These may affect multiple tissues, some of these malignancies involving organs in which there is lymphoid tissue.*

Case report. *A 81-year-old female patient was admitted to the Department of Internal Medicine with moderate-to-intense spontaneous pain in the left hypochondrial and in the left abdominal flank, associated with generalized fatigue and loss of appetite. According to the personal medical history, the patient is known with type II diabetes mellitus, being under treatment with oral antidiabetics (metformin 1000 mg), and arterial hypertension under treatment with candesartan. Upon admission, the physical examination revealed cutaneous and mucosal pallor and marked physical weakness. Abdominal palpation revealed pain in the left hypochondrial and in the left abdominal flank, associated with firm and massive splenomegaly, descending towards the umbilicus. Abdominal ultrasound confirmed massive splenomegaly, associated with moderate hepatomegaly. Blood analysis revealed several modifications, indicative of hypochromic normocytic anemia, associated with lymphocytosis, thrombocytopenia and neutropenia. C-reactive protein (CRP) serum levels were in normal range upon admission. All of these modifications suggested a possible leukemogenous or lymphoid malignancy, which resulted in the patient's transfer towards the Department of Hematology, for further investigations.*

Conclusions. *Massive splenomegaly, associated with anemia and thrombocytopenia in elderly patients, should always indicate a leukemogenous or lymphoid malignancy and a thorough differential diagnosis and collaboration between internists and hematologists is required.*

Keywords: *myeloproliferative disorder, blood malignancy, anemia, splenomegaly.*



Internal Medicine

Clinical Cases

Rezumat

Introducere. *Tulburările mieloproliferative definesc un grup vast și heteregen de entități neoplazice, caracterizate prin proliferarea malignă a celulelor sangvine. Acestea pot afecta mai multe țesuturi, unele dintre aceste afecțiuni maligne implicând organe în care există țesut limfoid.*

Prezentarea cazului. *O pacientă în vârstă de 81 de ani a fost internată în secția de medicină internă cu dureri spontane moderate până la intense în hipocondrul stâng și în flancul abdominal stâng, asociate cu oboseală generalizată și pierderea poftei de mâncare. Conform istoricului medical personal, pacienta este cunoscută cu diabet zaharat de tip 2, fiind în tratament cu antidiabetice orale (metformin 1000 mg), și hipertensiune arterială în tratament cu candesartan. La internare, examenul fizic a evidențiat paloare cutaneo-mucoasă și slăbiciune fizică marcată. Palparea abdominală a evidențiat durere în hipocondrul stâng și în flancul abdominal stâng, asociate cu splenomegalie fermă, palpabilă până la ombilic. Ecografia abdominală a confirmat splenomegalia masivă, asociată cu hepatomegalie moderată. Analizele de sânge au evidențiat mai multe modificări, indicând anemie hipocromă normocitară, asociată cu limfocitoză, trombocitopenie și neutropenie. Nivelurile serice ale proteinei C reactive (CRP) au fost în limite normale la internare. Toate aceste modificări au sugerat o posibilă malignitate leucemoidă sau limfoidă, care a dus la transferul pacientei către departamentul de hematologie, pentru investigații ulterioare.*

Concluzii. *Splenomegalia masivă, asociată cu anemie și trombocitopenie la pacienții vârstnici, ar trebui să indice întotdeauna o malignitate leucemoidă sau limfoidă și este necesar un diagnostic diferențial aprofundat și o colaborare între medici internişti și hematologi.*

Cuvinte cheie: *tulburare mieloproliferativă, malignitate a sângelui, anemie, splenomegalie.*

A 81 year old female pacient was admitted to the Department of Internal Medicine, in March 2022, with moderat-to-intense spontaneous pain in the left hypochondrial and left flank abdominal pain, associated with generalized physical weakness and loss of appetite.

According to the personal medical history of the patient, she is known with type II diabetes mellitus, treated with oral antidiabetics (Metformin 1000 mg), and arterial hypertension under treatment with candersartan 32 mg. The patient was also diagnosed with a mild form of COVID-19, through a RT-PCR SARS-CoV-2 test, in February 2022, without having any known complications due to the disease.

The hypochondrial pain started an year prior to the admission in the Department of Internal Medicine.

The pain was initially felt as an abdominal disconfort, being initially considered to be of digestive origin. As a consequence, the patient had an abdominal ultrasound, which detected mild splenomegaly, without any other morphological or functional abnormalities. However, for the following months, the intensity of the hypochondrial pain increased and spread towards the left abdominal flank and in the left interscapular region.

The patient also had an increase in physical weakness and a gradual loss of appetite. It should be noted that the patient also experienced mild weight loss (2-3 kg in the last year). In February 2022, the patient received a second abdominal ultrasound, which revealed a marked increase in the splenic volume. Based on the suspicion of a pernicious (Biermer) anemia, the patient received 1 intramuscular injection per month of vitamin B12, without any clinical or biological manifestations. However, just a day before the present admission, an abdominal computed tomography (CT) was performed, that detected marked splenomegaly, with an longitudinal diameter of 20 cm, associated with moderate homogeneous hepatomegaly (Figure 1, Figure 2). Enlarged celiac and hepatic hillum lymph nodes were also detected, which resulted in the suspicion of a neoplastic phenomenon, either leukemogenous or lymphoid in nature.

Upon admission, the clinical examination of the patient revealed altered general state, without fever or chills, associated with mild cutaneous and mucosal pallor, generalized physical weakness and impalpable superficial lymph nodes. In supine position, the clinical examination of the abdomen revealed spontaneous pain in the left hypochondrial region and left abdominal flank, which was amplified through palpation, but also palpation-induced pain in the right hypochondrial region. Also, palpation of the left abdominal flank revealed a massive and firm splenomegaly, palpable above the umbilicus.

Furthermore, the inferior margin of the liver was 2-3 cm below the right costal rim. No other clinical findings were detected during the patient's examination.

Paraclinical investigations included complete blood count, blood biochemistry, coagulation tests, C reactive protein serum levels, vitamin B12 serum levels, an electrocardiogram (ECG) and a chest X-ray.

Complete blood count revealed the several modifications, as shown in Table 1. The analysis revealed hypochromic normocytic anemia, associated with mild lymphocytosis, thrombocytopenia and mild monocytosis. Blood biochemistry also detected several biochemical modifications (Table 2). Coagulation tests revealed no modifications.



Internal Medicine

Clinical Cases

C reactive protein serum levels were in normal range, with a value of 2.16 mg/dl (normal values: ≤5 mg/dl). The patient's ***chest X-ray*** showed difuse reticular patterns in both pulmonary parenchyma, with slight cardiomegaly, but with no other radiological modifications (Fig. 3).

To exclude pernicious anemia - a pressumed diagnosis prior to the patient's admission, vitamin B12 serum levels were also analysed. Hence, the levels of vitamin B12 were in normal range: 486.00 pg/ml (normal values: 191.00 – 663.00 pg/ml), thus rulling out Biermer anemia from the differential diagnosis. The differential diagnosis included several diseases, in which splenomegaly and anemia are typical manifestations. A precise diagnostic algorithm is necessary in the context of splenomegaly (Figure 6).

Malaria is characterized by hemolytic anemia induced by the parasitic plasmodial infection of the circulating erythrocytes, associated with generalized fatigue, high fever – which is unresponsive to classic antipyretics – and hepatosplenomegaly.

The diagnosis of a potential infection with Plasmodium spp. requires a thorough medical history of the patient, focusing on epidemiological aspects, such as travelling to certain endemic regions (for example, Africa, India, Mexico and other parts of Central America). The patient, however, had no indicative epidemiological background. Furthermore, the patient had hypochromic normocytic anemia, in contrast to the normochromic normocytic anemia detected in malaria, which is determined by the intravascular and extravascular hemolysis. Also, the patient had no recurrent febrile episodes.

Thus, malaria was easily excluded based on the non-suggestive clinical manifestations and paraclinical modifications.

Bacterial endocarditis may express itself not only through cardiovascular signs and symptoms, but also through systemic manifestations, such as high fever and splenomegaly. However, the patient did not experience fever and, upon cardiac examination, there were no suggestive heart murmurs, indicative of valvular heart disease, which is present in all forms of bacterial endocarditis.

Splenic tuberculosis may appear in the context of a hematogenic dissemination of Mycobacterium tuberculosis, associated with miliary tuberculosis, polyserositis and even meningitis; patients develop massive splenomegaly and also experience high fever, enlarged lymph nodes and anemia. Apart from the massive splenomegaly and anemia, no one of these manifestations were expressed by the patient, therefore excluding splenic tuberculosis.

Chronic lymphocytic leukemia frequently develops in elderly patients, manifesting

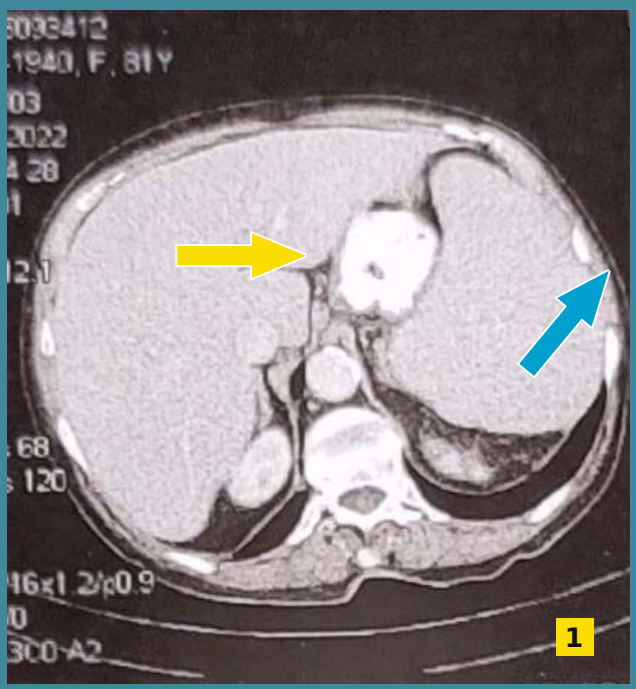

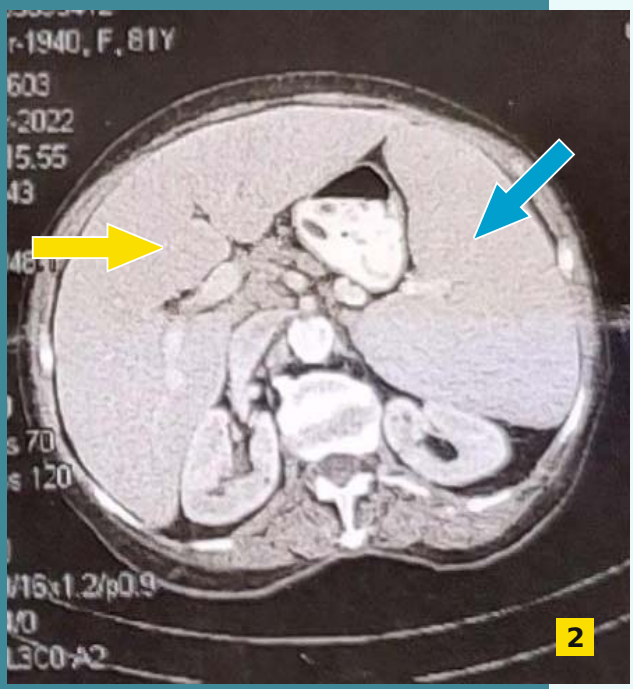

Figure 1. *Sagital CT view of the upper abdominal cavity, showing enlarged liver (left side, yellow arrow) and massive splenomegaly (right side, blue arrow), associated with enlarged hepatic hillum lymph nodes*

Figure 2. *Sagital CT view of mid abdominal cavity (moderate hepatomegaly - yellow arrow, massive splenomegaly - blue arrow)*

Parametre	Result	Normal Values
Eosinophils	0.06	00.00 – 0.70
Hematocrit (%)	32.90	36.00 – 48.00
Hemoglobin (g/dl)	10.30	11.70 – 15.00
Lymphocytes	4.37	1.00 – 4.00
Medium cell hemoglobin (MCH)	26.60	27.00 – 32.00
Mean corpuscular volume (MCV)	85.00	80.00 – 100.00
Mean corpuscular hemoglobin concentration (MCHC)	31.30	32.00 – 36.00
Monocytes	10.70	2.00 – 10.00
Neutrophils	25.10	50.00 – 75.00
Platelets	122.00	150.00 – 450.00
Erythrocytes	3.87	4.20 – 5.60
Leucocytes	6.94	4.00 – 11.00

Table 1. *Complete blood count modifications (highlighted in red) of the patient upon admission*



itself through moderate splenomegaly, lymphocytosis and anemia, which was one of the main differential diagnosis. At this point, it was necessary to have a bone marrow biopsy in the Department of Hematology. Hence, the patient was transferred to the Department of Hematology, in order to confirm or exclude chronic lymphocytic leukemia. The patient underwent further investigations after being transferred in the Department of Hematology in April 2022. It should be noted that the general clinical state of the patient was unmodified.

A complete blood count revealed several modifications (Table 3), highlighted in red. Blood biochemistry also revealed the modifications presented in Table 4.

As Table 3 shows, there is persistent lymphocytosis associated with hypochromic normocytic anemia. From a clinical point of view, the patient's firm and tender splenomegaly was also persistent, which resulted in the suspicion of a leukemogenous or lymphoid neoplasia. Further hematological investigations were required.

Blood cytology revealed severe hypocellular smears, with a percentage of 40% mature and polymorphic lymphocytes, associated with rare mature and intermediate neutrophils and rare erythroblasts. However, this result required a histopathological examination through bone marrow biopsy. The bone marrow biopsy included a grey tissue fragment, with firm consistency, from the iliac crest. The histopathological examination used hematoxylin-eosin staining.

Optic microscopy showed 70% cellularity, all blood cell lines being present. In the paratrabecular and interstitial region abnormal nodules were detected, which were formed by small lymphocytes, with irregular nuclei and pale cytoplasm. Megakariocytes were found to have normal localization and morphology, some of them having hypolobated nuclei. The granulocyte lines described a slight left shift, but with present maturation.

As for the erythroblasts, these cells were normal in terms of maturation and morphology. Furthermore, the M:E (myeloid to erythroid) ratio was 4:1. The microscopic examination also revealed a small number of plasmocytes and eosinophils in the interstitial space. The hematologist's and pathologist's diagnosis was that of a non-Hodgkin B-cell marginal lymphoma.

The microscopic examination of the bone marrow biopsy is shown below. The red arrows reveal the abnormal proliferations of B lymphocytes.(Figures 7,8,9,10).

Imunophenotyping through flow cytometry of circulating lymphocytes used the following monoclonal antibodies for labeling: CD3, CD4, CD5, CD8, CD10, CD16, CD19, CD20, CD23, CD38, CD45, CD56, CD79b, CD103,

Parametre	Result	Normal Values
Uric acid (mg/dl)	6,15	2,40 – 5.70
Total serum bilirubin (mg/dl)	0,37	00.00 – 1,20
LDL-cholesterol (mg/dl)	139.10	<70
Total serum cholesterol (mg/dl)	171.95	120 – 200
Serum creatinine (mg/dl)	0.56	0.50 – 0.90
Alkaline phosphatase (U)	58.07	35.00 – 104.00
Serum glucose (mg/dl)	169.25	80.00 – 115.00
Glycated hemoglobin (g/dl)	5.88	4.00 – 5.60
Serum iron	35.41	37.00 – 145.00
TGO	19.23	00.00 – 32.00
TGP	8.75	00.00 – 33.00
Serum urea (mg/dl)	32.00	17.40 – 49.00

Table 2. *Blood biochemistry modifications (highlighted in red) of the patient upon admission*

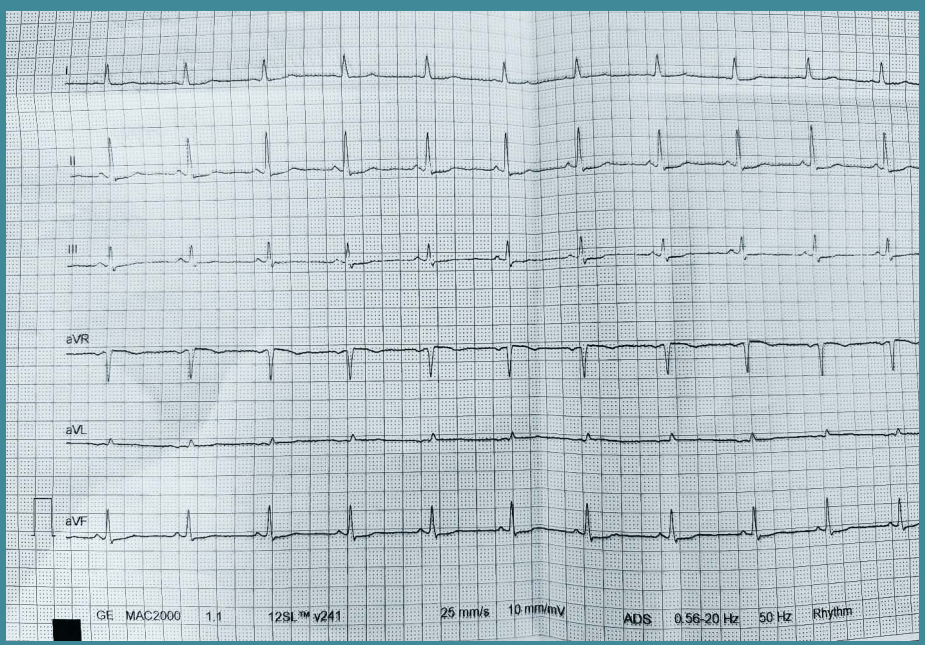

Figure 3. *Patient's ECG (leads DI, DII, DIII, aVR, aVL, aVF)*

Internal Medicine

Clinical Cases

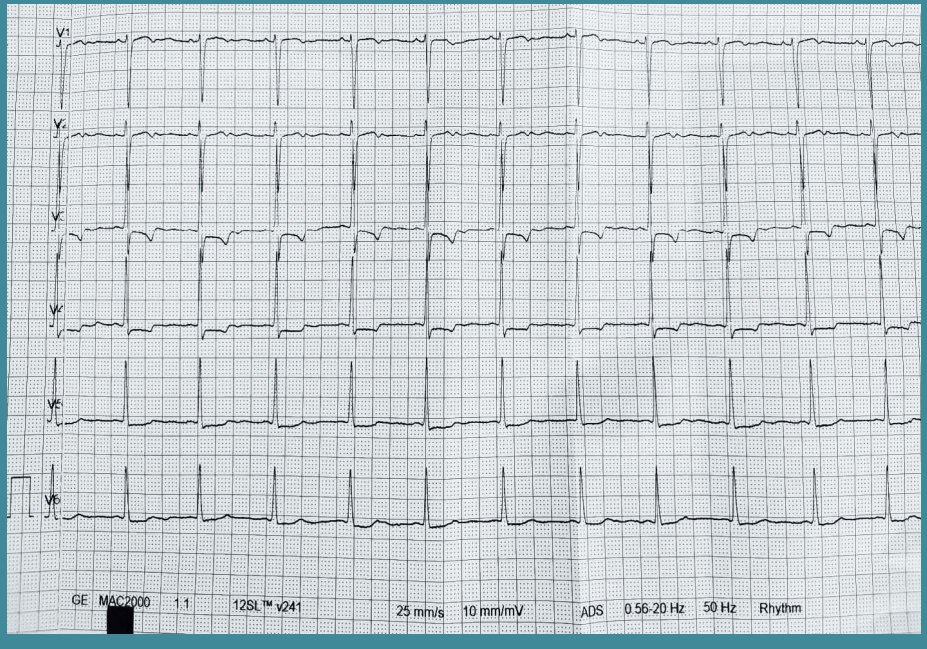

Figure 4. *Patient's ECG (leads V1-V6)*



Figure 5. *Patient's posteroanterior chest X-ray*

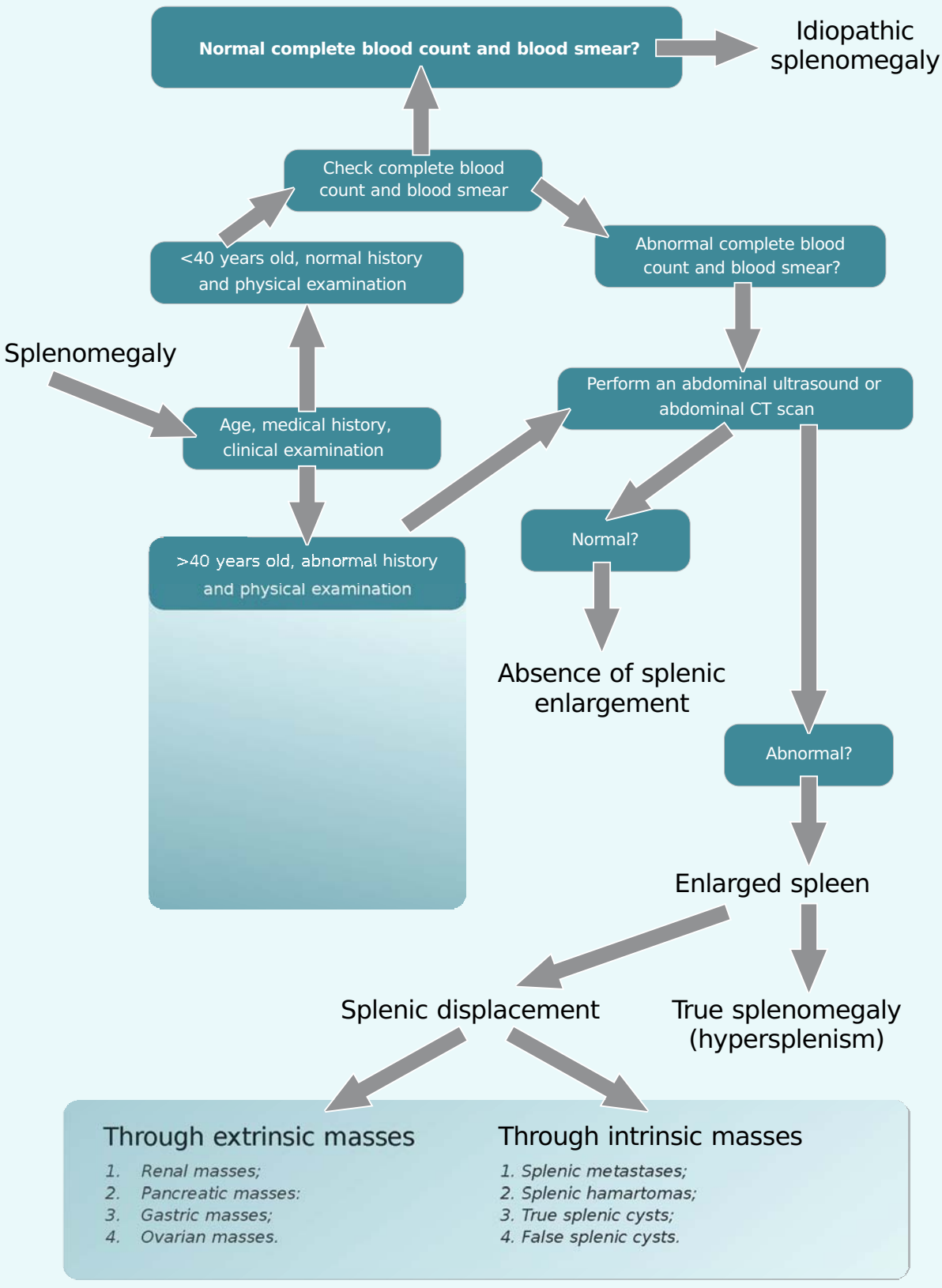

Figure 6. *Algorithm of Splenomegaly*



CD200, mIgκ, mIgλ. In the CD45+ region, a percentage of 75% lymphocytes, 3% monocytes and 2% granulocytes were revealed.

The lymphocytic subpopulations were as follows: 6% CD19+ B lymphocytes, 28% CD3+ T lymphocytes and 4% CD3-CD56+ NK cells. The B lymphocytes revealed the following phenotype: intense CD20+, CD79b+, partial CD23+, CD200+dim, mIgk+, CD5-, CD10-, CD103-, CD38-, mIgë-.

The hematologist's conclusion was that of an existent monoclonal B cell population with a phenotype compatible with a a lymphoproliferative neoplasia, namely marginal B-cell lymphoma. Thus, chronic lymphocytic leukemia, which was taken into consideration in the Department of Internal Medicine, prior to the patient's admission in the Department of Hematology, was excluded based on imunophenotyping through flow cytometry.

The final diagnosis was that of a splenic marginal zone non-Hodgkin B-cell lymphoma stage IVA, which explained the massive splenomegaly and other clinical and paraclinical manifestations.

The patient immediately underwent chemotherapy for several weeks, which clearly improved the general clinical state: the absence of pain in the left hypochondrial and abdominal flank and a gradual decrease in the splenic volume.

Discussions

Splenic marginal zone lymphoma (abreviated as SMZL) is defined as a rare variant of a non-Hodgkin lymphoma determined by the malignant proliferation of B lymphocytes within the marginal zone of secondary follicles[1,2,3].

Massive splenomegaly and bone marrow involvement are frequently detected clinical manifestations, resulting in pain residing in the left hypochondrial and left abdominal flank and anemia. It should be noted that, in SMZL, superficial lymphnode enlargement is minimal or absent, but on abdominal computed tomography there is englargement of the lymphonodes in the hepatic and splenic hillum[3, 4]. Biologically, lymphocytosis is a common hematological modification and cytopenias, most frequently represented by anemia, are mostly related to the associated hypersplenism[4].

The infiltration of the bone marrow with malignant B cells is common, being revealed in 83-100% of all cases of SMZL[5]. Although bone marrow biopsy is essential for the diagnosis of this blood malignancy – which can reveal either nodular, interstitial or intrasinusoidal infiltration –, histology with immunohistochemical analysis if also required and fundamental[6]. Two minimum diagnostic criteria for the diagnosis of SMZL were proposed by Matutes et al.:

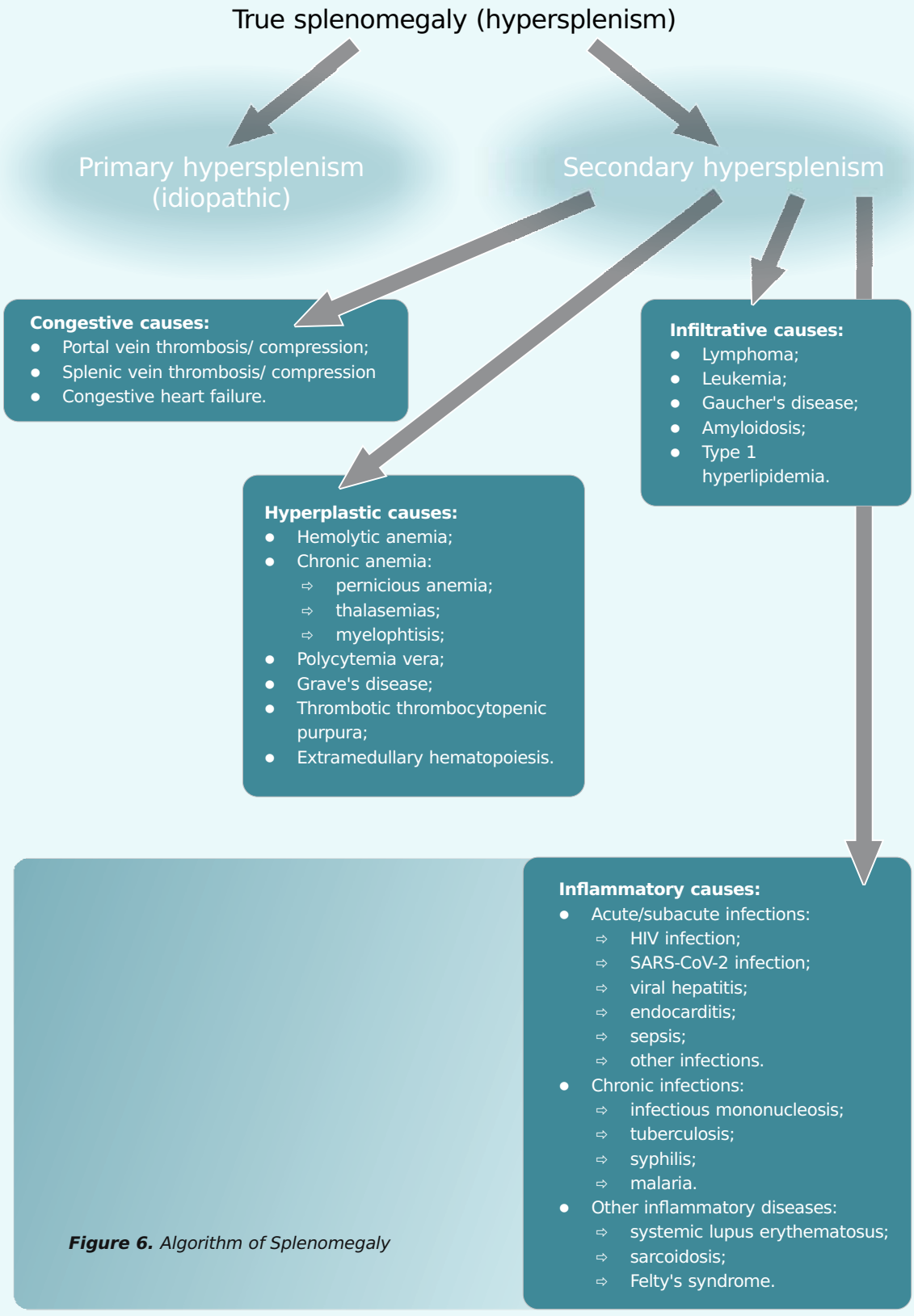

Figure 6. *Algorithm of Splenomegaly*



1. Splenic tissue histological examination and immunophenotype with a modified Matutes score of <3 points[7].
2. If the patient has massive splenomegaly and splenectomy is not performed, the diagnosis is based solely on the blood and bone marrow findings, through morphology and immunophenotype with intrasinusoidal infiltration of CD20+ lymphocytes.

Treatment options in SMZL may vary. Although splenectomy was the therapy of choice for numerous decades, there is, at the present moment, a tendency to prescribe Rituximab monotherapy, the explanation being that the majority of patients being old and with known co-morbidities [8,9,10]. Acording to Arcaini et al., laparoscopy should be preffered over splenectomy especially in elderly patients and with associated diseases[11].

Chemotherapy in SMZL may use different combinations, such as cyclophosphamide, vincrstine and prednisone; cyclophosphamide, doxorubicine, vincristine and prednisone, but also fludarabine and cyclophosphamide[12,13,14,15].

Rituximab as monotherapy was proved to be as effective in SMZL as splenectomy, having the potential to provide better therapeutic responses and being associated with less toxicity in contrast to chemotherapy[11], thus having very little impact on the patient's quality of life (for example, reduced risk of infections). It should be noted that purine analogs have been proved to be more toxic for the patient with SMZL. Hence, these pharmacological agents should only be used for refractory or relapsed cases of the disease. Also, fludarabine has been considered to have high response rates, with a progression-free survival of 4.7 years[16,17].

As a follow-up, it should emphasized that asymptomatic patients should be clinically and biologically evaluated every six months, with no more than a physical examination (for example, examination of the splenic volume), complete blood count and blood biochemistry. However, the interval between admissions ought to be shortened in case of increasing splenomegaly or aggravation of cytopenias[18].

Conclusions

The present clinical case presents a representative example of a complex systemic disorder – non-Hodgkin B-cell lymphoma –, for which collaboration between the internists and hematologists is essential in confirming the diagnosis.

Whereas the internist is concerned mainly in the semiological aspects, differential and clinical diagnosis of a complex disease (myeloproliferative disorder), the hematologist's sole purpose is to confirm the diagnosis of this particular blood malignancy through

Parameter	Result	Normal Values
White blood cells	4.69	3.17 – 8.40 / x10^3/µL
Red blood cells	3.60	3.72 – 5.06 / 10^6/ µL
Hemoglobin (g/dl)	9.6	11.00 – 14.70
Hematocrit (%)	29.1	35.1 – 46.7
MCV	80.8	80.0 – 96.0/fL
MCH	26.7	26.80 – 32.40/pg
MCHC	33.0	29.60 – 32.5 g/dl
Platelets	50	167 – 390/ x 10^3/ µL
Lymphocytes (%)	54.4	21.9 – 50.3/%
Eosinophils (%)	0.0	0.6 – 4.9/%
Monocytes (%)	3.2	4.2 – 9.6/%
Basophils (%)	0.0	0.2 – 1.4/%
Neutrophils (%)	42.4	39.7 – 71.2/%

Table 3. *Complete blood count modifications*

Parameter	Result	Normal Values
Serum glucose (mg/dl)	110	76-106
Serum urea (mg/dl)	53.1	9-23
Serum creatinine (mg/dl)	0.57	0.55 – 1.02
Serum uric acid (mg/dl)	5.3	3.1 – 7.8
Calcium (Ca^{2+}) (mg/dl)	8.3	8.3 – 10.6
Sodium (Na^+) (mmol/L)	138.2	137 – 145
Potasium (K^+) (mmol/L)	3.46	3.6 – 5
Magnesium (Mg^{2+}) (mg/dl)	1.56	1.6 – 2.3
Lactate-dehydrogenase (LDH) (U/L)	319	120 – 246
C-reactive protein (CRP) (mg/dl)	2.63	0 – 0.32
D-dimers (ug/ml)	19.12	0 – 0.50

Table 4. *Blood biochemistry modifications*

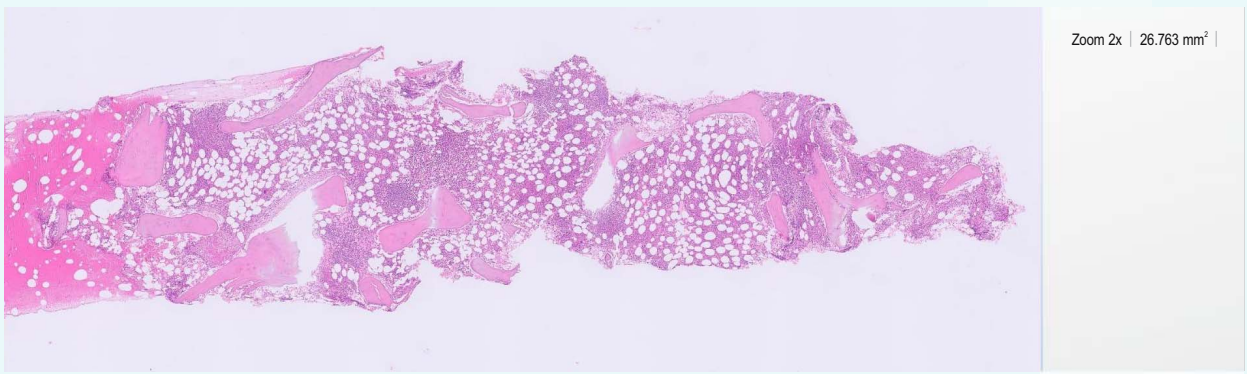

Figure 7. *Bone marrow biopsy showing diffuse B cell proliferation associated with numerous adipocytes related to senescence (zoom 2x)*

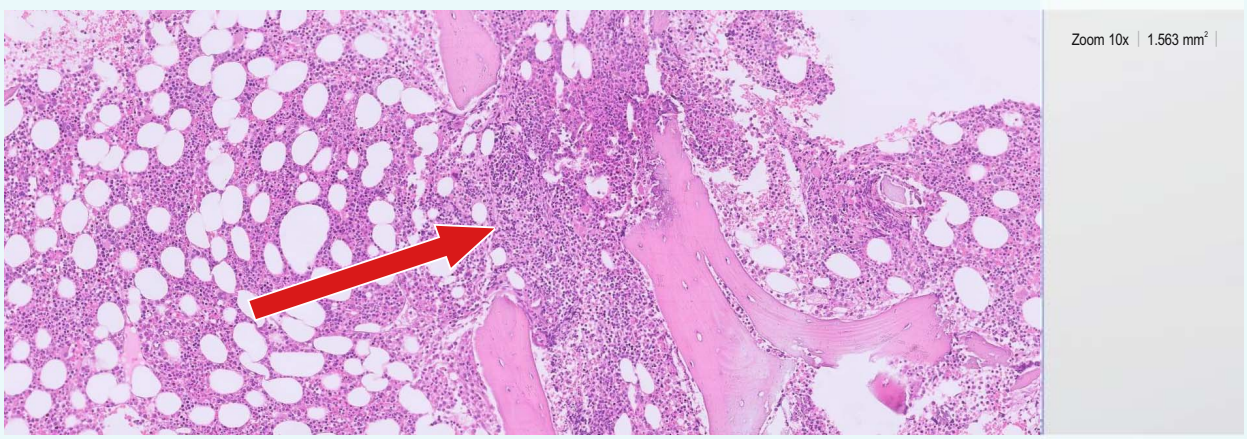

Figure 8. *Diffuse B cell proliferation (zoom 10x)*

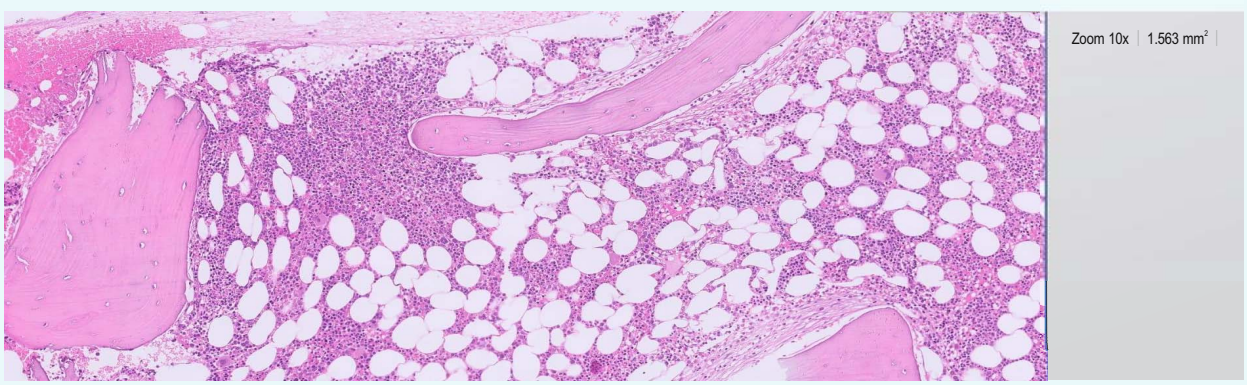

Figure 9. *Diffuse proliferation of B lymphocytes associated with a large number of adipocytes (zoom 10x)*

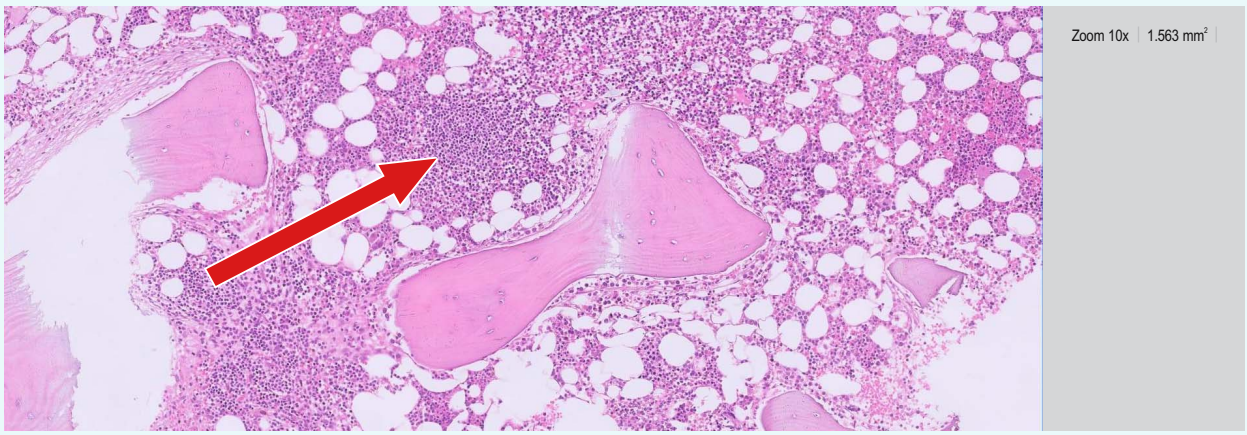

Figure 10. *Diffuse proliferation of B lymphocytes (zoom 10x)*

specialized paraclinical procedures. Taken into consideration that an elderly patient presented with massive splenomegaly, generalized fatigue and cutaneous and mucosal pallor, without having fever or significant weight loss during the past year, a thorough differential diagnosis was required, as these manifestations may be present in several other systemic diseases.

References

1. Zinzani P.L. The many faces of marginal zone lymphoma. ASH Educ Progr B. 2012;2012(1):426–432.

2. Lenglet J., Traullé C., Mounier N., Benet C., Munoz-Bongrand N., Amorin S. Long-term follow-up analysis of 100 patients with splenic marginal zone lymphoma treated with splenectomy as first-line treatment. Leuk Lymphoma. 2013;55:1854–1860.

3. Swerdlow S.H., Campo E., Harris N.L., Jaffe E.S., Pileri S.A., Stein H. In: World Health Organization classification of tumours of haematopoietic and lymphoid tissues. 4th ed. Swerdlow S.H., Campo E., Harris N.L., Jaffe E.S., Pileri S.A., Stein H., et al., editors. International Agency for Research on Cancer (IARC); Lyon: 2008. International Agency for Research on Cancer (IARC). 422 p.

4. Behdad A., Bailey N.G. Diagnosis of splenic B-cell lymphomas in the bone marrow: a review of histopathologic, immunophenotypic, and genetic findings. Arch Pathol Lab Med. 2014;138(10): 1295–1301.

5. Traverse-Glehen A., Baseggio L., Salles G., Felman P., Berger F. Splenic marginal zone B-cell lymphoma: a distinct clinicopathological and molecular entity. Recent advances in ontogeny and classification. Curr Opin Oncol. 2011;23(5):441–448.

6. Matutes E., Oscier D., Montalban C., Berger F., Callet-Bauchu E., Dogan A. Splenic marginal zone lymphoma proposals for a revision of diagnostic, staging and therapeutic criteria. Leukemia. 2008;22(3):487–495.

7. Moreau E.J., Matutes E., A'Hern R.P., Morilla A.M., Morilla R.M., Owusu-Ankomah K.A. Improvement of the chronic lymphocytic leukemia scoring system with the monoclonal antibody SN8(CD79b) Am J Clin Pathol. 1997;108(4):378–382.

8. Chacón J.I., Mollejo M., Muñoz E., Algara P., Mateo M., Lopez L. Splenic marginal zone lymphoma: clinical characteristics and prognostic factors in a series of 60 patients. Blood. 2002;100(5):1648–1654.

9. Iannitto E., Ambrosetti A., Ammatuna E., Colosio M., Florena A.M., Tripodo C. Splenic marginal zone lymphoma with or without villous lymphocytes. Cancer. 2004;101(9):2050–2057.

10. Kalpadakis C., Pangalis G.A., Vassilakopoulos T.P., Sachanas S., Angelopoulou M.K. Treatment of splenic marginal zone lymphoma: should splenectomy be abandoned? Leuk Lymphoma. 2014;55(7):1463–1470.

11. Arcaini L., Rossi D., Paulli M. Splenic marginal zone lymphoma: from genetics to management. Blood. 2016;127(17):2072–2081.

12. Tsimberidou A.M., Catovsky D., Schlette E., O'Brien S., Wierda W.G., Kantarjian H. Outcomes in patients with splenic marginal zone lymphoma and marginal zone lymphoma treated with rituximab with or without chemotherapy or chemotherapy alone. Cancer. 2006;107(1):125–135.

13. Thieblemont C., Felman P., Berger F., Dumontet C.,



Arnaud P., Hequet O. Treatment of splenic marginal zone B-cell lymphoma: an analysis of 81 patients. Clin Lymphoma. 2002;3(1):41–47.

14. Kalpadakis C., Pangalis G.A., Maria K.A., Sachanas S., Kontopidou F.N., Yiakoumis X. Treatment of splenic marginal zone lymphoma with rituximab monotherapy: progress report and comparison with splenectomy. Oncologist. 2013;18(2):190–197.

15. Else M., Marín-Niebla A., de la Cruz F., Batty P., Ríos E., Dearden C.E. Rituximab, used alone or in combination, is superior to other treatment modalities in splenic marginal zone lymphoma. Br J Haematol. 2012;159(3):322–328.

16. Kalpadakis C., Pangalis G.A., Dimopoulou M.N., Vassila-kopoulos T.P., Kyrtsonis M-C., Korkolopoulou P. Rituximab monotherapy is highly effective in splenic marginal zone lymphoma. Hematol Oncol. 2007;25(3): 127–131.

17. Bennett M., Yegena S., Chubar E., Schechter G. Rituximab monotherapy in splenic marginal zone lymphoma instead of splenectomy. Br J Haematol. 2010;149(Suppl. 1):45.

18. Dreyling M., Thieblemont C., Gallamini A., Arcaini L., Campo E., Hermine O. Esmo consensus conferences: guidelines on malignant lymphoma. Part 2: marginal zone lymphoma, mantle cell lymphoma, peripheral T-cell lymphoma. Ann Oncol. 2013;24(4):857–877.