sciendo
Internal Medicine 2022 vol. XIX No. 1 - www.srmi.ro 115
10.2478/inmed-2022-0203

RENAL INVOLVEMENT IN SJOGREN S SYNDROME

Marilena Stoian MD, PhD[1,2]
[1]University of Medicine and Pharmacy „Carol Davila", Bucharest, Romania
[2]„Dr. Ion Cantacuzino" Clinical Hospital, Bucharest, Romania

Abstract

Background. *Primary Sjogren's syndrome (pSS) is a chronic progressive autoimmune disorder characterized by lymphocytic infiltration of the exocrine glands, which affects the salivary and lacrimal glands, presenting dryness of the mouth and eyes. Renal involvement is easily ignored by the physicians because the clinical symptoms are often insidious. The most common renal disease in pSS is tubulointerstitial nephritis, responsible for renal tubular acidosis in 20%.*

Case report. *A 36-year-old woman with polyuria and polydipsia for 10 years ago was admitted to the hospital because asymptomatic hypokalemia, kidney stones, and rashes. This woman presented nephrogenic diabetes insipidus and chronic metabolic acidosis for one year, conditions treated with amiloride and sodium bicarbonate. Anti-Sjögren's antibody A and B were checked and were both found to be positive. At presentation, she had elevated serum osmolality of 301, with a very low urine osmolality of 61, and serum sodium of 143. A metabolic acidosis with hypokalemia and elevated urine pH are consistent with distal renal tubular acidosis (RTA). A kidney biopsy was obtained, which revealed tubular interstitial fibrosis with infiltration of lymphocytes and plasmacytes who extended into intact cortical parenchyma and was consistent with active chronic interstitial nephritis.*

Conclusions*. Our presenting patient presented renal manifestations of pSS, including diabetes insipidus, renal tubular acidosis type I, tubulointerstitial nephritis, and nephrolithiasis. None of these findings are common presentations of pSS. The presence of all of these symptoms in one individual makes this patient an atypical way to diagnose a primary Sjogren's syndrome.*

Keywords: *renal tubular acidosis type I, renal biopsy, chronic interstitial nephritis, primary Sjogren's syndrome.*

Rezumat

Introducere. *Sindromul Sjogren primar (SSp) este o afecțiune autoimună cronică progresivă caracterizată prin infiltrarea limfocitară a glandelor exocrine, care afectează glandele salivare și lacrimale, cauzând uscăciunea gurii și a ochilor. Afectarea renală trece adesea neobservată de către medici, deoarece simptomele clinice sunt insidioase. Cea mai frecventă afecțiune renală în contextul SSp este nefrita tubulointerstițială, responsabilă de acidoză tubulară renală în 20% dintre cazuri.*

INTERNAL MEDICINE

Clinical Cases

Prezentarea cazului. *Pacientă de 36 de ani care prezenta poliurie și polidipsie de 10 ani a fost spitalizată pentru hipokaliemie asimptomatică, litiază renală și erupție cutanată. Pacienta era cunoscută de un an cu diabet insipid nefrogen și acidoză metabolică, afecțiuni tratate cu amilorid și bicarbonat de sodiu. Anticorpii anti-Sjögren A și B s-au dovedit pozitivi. La prezentare, osmolalitatea serică era crescută - 301, cu o osmolalitate urinară foarte scăzută - 61 și sodiu seric de 143. Acidoza metabolică cu hipokaliemie și pH-ul urinar crescut sunt în concordanță cu acidoza tubulară renală distală (RTA). S-a prelevat biopsie renală, care a evidențiat fibroză interstițială tubulară, cu infiltrare de limfocite și plasmocite care s-au extins în parenchimul cortical intact, fiind în concordanță cu diagnosticul de nefrită interstițială cronică activă.*

Concluzii. *Pacienta noastră a prezentat manifestări renale ale SSp, inclusiv diabet insipid, acidoză tubulară renală de tip I, nefrită tubulointerstițială și nefrolitiază. Niciuna dintre acestea nu se numără printre manifestările comune ale SSp. Prezența tuturor acestor simptome face ca tabloul diagnostic al sindromului Sjogren primar să fie unul atipic în acest caz.*

Cuvinte cheie: *acidoză tubulară renală de tip I, biopsie renală, nefrită interstițială cronică, sindrom Sjogren primar.*

Introduction

Primary Sjogren's syndrome (pSS) is a chronic progressive autoimmune disorder characterized by lymphocytic infiltration of the exocrine glands, which affects the salivary and lacrimal glands, presenting dryness of the mouth and eyes. The majority of infiltrating mononuclear cells are CD4+ T cells[1]. Some patients may present diverse extraglandular impairment such as that in the lungs, kidneys, nervous system, and skin affected by this disorder[2].

The degree of infiltration defines whether the process becomes clinically significant. A systematic review estimated the prevalence of Sjogren's syndrome in the general population to be 7 per 100,000 person-years[3], which makes it the most common systemic autoimmune disease after rheumatoid arthritis. The annual incidence of new cases is 5.8 to 5.9 per 100,000 as reported from the Mayo Clinic Olmstead Country Minnesota USA Cohorts[4]. The prevalence doubles when including these with additional connective tissue disease[4].

The heterogeneity of signs and symptoms has led to the development of multiple classification criteria.

The three most commonly used criteria for the diagnosis of pSS are:

1. the Copenhagen criteria;
2. the European classification criteria;
3. the International Collaborative Clinical Alliances Cohort.

The Copenhagen criteria, proposed in 1986, included objective evidence of kerato-conjunctivitis sicca, salivary gland involvement, and whole unstimulated salivary flow[5]. The European classification criteria was initially proposed in 1996 and was later revised in 2002 by the American-European consensus group (AECG). According to this criterion, the diagnosis of pSS can be met by fulfilling four out of six items. Four of the six items include subjective or objective evidence of keratoconjunctivitis sicca and xerostomia. The two final items include a positive minor salivary gland biopsy with a focus score of ≥1/4 mm^2 or the presence of anti-Ro/SSA or anti-La/SSB antibodies[6].

The third classification criteria, proposed in 2012 by the Sjogren's International Collaborative Clinical Alliances Cohort, has since been approved by the American College of Rheumatology. Based on this criterion, the diagnosis of pSS can be established with the presence of two or more of the following objective findings: 1) positive anti-Ro/SSA and/or anti-La/SSB antibodies, or positive rheumatoid factor (RF) and positive antinuclear antibodies (ANA); 2) positive minor salivary gland biopsy with a focus score of ≥1/4 mm2; and 3) keratoconjunctivitis sicca with an ocular staining score of ≥3[7]. Both the American-European consensus and the International Collaborative Clinical Alliances Cohort have been validated in further studies with a sensitivity and specificity of greater than 90%[7,8].

The predominant serologic findings of pSS are positive anti-nuclear antibodies (ANA), anti-SSA antibodies, and anti-SSB antibodies. Since the condition is caused by a B-lymphocyte proliferation, development of lymphoproliferative disorders is a major concern[9].

Sjögren's syndrome can also be secondary to other autoimmune conditions, including, but not limited to, systemic lupus erythematosus (SLE), rheumatoid arthritis (RA), and systemic sclerosis (scleroderma)[9,10,11,12]. The prevalence of renal involvement in pSS has been reported to range approximately from 10%[9] to 30%[13]. For example, a review by François et al. estimated the prevalence of renal disease in pSS to be less than 10%[14]. Renal disease in pSS is due to 2 distinct pathophysiological processes:

1. Epithelial disease with significant lymphocytic infiltration, resulting in different conditions like tubulointerstitial nephritis (TIN), electrolyte disturbances like hypokalemia, distal renal tubular acidosis, proximal renal tubular acidosis, Fanconi syndrome, diabetes insipidus, Gitelman syndrome, nephrolithiasis and nephrocalcinosis, and
2. Non-epithelial disease that can lead to glomerulopathy as a result of an immune complex-mediated process[15,16]. However, most of the patients present only 1 of the above-mentioned signs and symptoms. Furthermore, it is uncommon for 1 patient to present multiple features of renal disease associated with pSS.

Renal involvement is easily ignored by the physicians because the clinical symptoms are often insidious. Growing evidence suggests that patients with pSS may have greater renal injury risk than the general population and the



most common renal disease in pSS is tubulointerstitial nephritis, responsible for renal tubular acidosis in 20%[17]. However, it is still challenging to diagnose renal involvement in pSS patients.

Case Report

A 36-year-old woman who had polyuria and polydipsia for 10 years ago included chronic asymptomatic hypokalemia, kidney stones, and rashes was admitted into the hospital. One year ago, she was seen by an outside nephrologist and was diagnosed with nephrogenic diabetes insipidus and chronic metabolic acidosis, conditions treated with amiloride and sodium bicarbonate.

Family history was negative for any autoimmune condition, and social history was non-contributory. Upon further questioning, the patient mentioned long-standing severe dry mouth without any skin or eye dryness. This is why the anti-Sjögren's antibody A and B were checked and were both found to be positive. At presentation, she had elevated serum osmolality of 301, with a very low urine osmolality of 61, and serum sodium of 143. Another lab test: K. 3 mmol/L, HCO3 16 mmol/L, Chloride 112 mmol/L, Creatinine 1.5 mg/dl, GFR 43 mL/min/1.73 m^2, BUN 14 mg/dl 3.5 mg/dl, Uric uric 3.5 mg/dl. 4-hour urine collection. She also produced more than 9 liters of urine per day: and 24-hour urine collection shows Oxalate 600 mg/day. A metabolic acidosis with hypokalemia and elevated urine pH are consistent with distal RTA. Serological profile: ANA 1:1080; Sm ab Negative; RNP Negative; Anti SSA 128; Anti SSB 64; Rheumatoid Factor 111 IU/mL; Beta 2 Macroglobulin 12700 mcg/mg. A kidney biopsy was obtained, which revealed tubular interstitial fibrosis with infiltration of lymphocytes and plasmacytes.

This infiltration focally extended into intact cortical parenchyma and was consistent with active chronic interstitial nephritis (Figure 1). Out of 19 glomeruli studied in the specimen, 7 were completely or near-completely sclerotic, with no endocapillary hypercellularity, crescent formation, or evidence of thrombosis. For pSS treatment, she was started on azathioprine, hydroxy-chloroquine and steroids. Before the initiation of hydroxychloroquine, she was referred to an ophthalmologist and was diagnosed with dry eyes, even though she was completely asymptomatic. However, as a result of the treatment, acidosis improved and her bicarbonate level normalized. Nocturia and polyuria, which were her chief concerns, improved.

Discussion

Interstitial nephritis (IN), the most common renal lesion of pSS is characterized by the presence of lymphocytes, plasma cells and

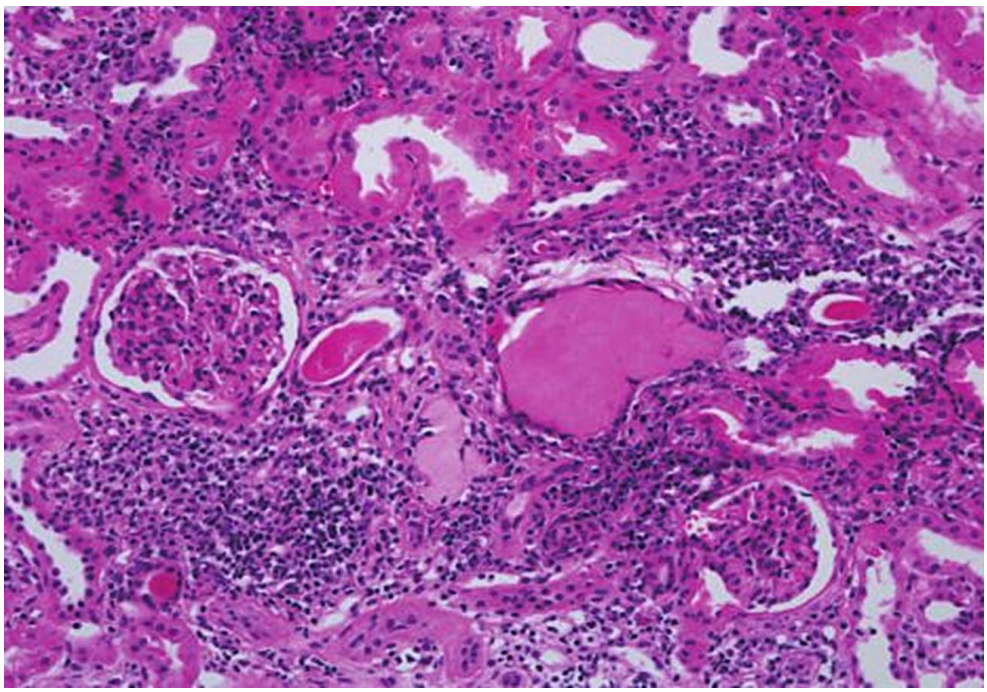

Figure 1. *Renal biopsy shows chronic tubulointerstitial nephritis. The interstitium shows interstitial fibrosis, tubular atrophy and mononuclear cell infiltration (PAS staining, magnification; x200).*

monocytes in the interstitium combined with tubular atrophy and fibrosis[18].

Interstitial nephritis is observed in 30% patients and leads to clinical symptoms in 5% to 10% of patients. The majority of the infiltrating cells have the phenotype of CD4+ cells resembling the lesion in the salivary glands[19]. The clinical presentation may be hyposthenuria, overt or latent distal tubular acidosis (RTA) (Type I) and less commonly the Fanconi syndrome (RTA) (Type II)[20]. Renal tubular acidosis is characterized by acidosis and an inability to excrete a highly acid urine, out of proportion secondary to the reduction of glomerular filtration rate. Proximal tubular interstitial disease may lead to the excretion of urine with a pH less than maximally low 4.5) and a high bicarbonate content. The dysfunction of the proximal tubule may lead to the excretion of many of the constituents, which are normally completely reabsorbed in the proximal tubule. Thus, despite normal plasma levels of organic substances such as amino acids, glucose, and acid uric, these are excreted in excess in the urine. Phosphaturia and hypophosphatemia may be part of the full-blown Fanconi syndrome seen under these circumstances, or it may be the sole manifestation of what then must be viewed as a specific transport defect. Distal nephron disturbances are responsible for the fine regulation of renal sodium, chloride and potassium handling in the exchange with hydrogen ion transport.

As consequence, involvement of these structures can lead to disturbances of urine concentration, inability to reduce the pH below 5.5, low urinary citrate concentrations, nephrocalcinosis and renal stones, kaliuresis, which may or not be accompanied by modest



volume contraction, hypokalemia and negative potassium balance[21]. Renal tubular acidosis may be present in 22-30% of pSS patients and is associated with the lymphocytic and plasma cell infiltrates surrounding renal tubules[22, 23]. Polyuria and renal colic are the most common manifestations while cases of hypokalemic analysis and cardiac arrest[24] as well as osteomalacia due to RTA and hypophosphatemia have been described[25]. Mild azotemia is reported in young patients, and correspond with the severity of the interstitial disease. The RTA related manifestations in pSS patients are observed mostly early in the course of the disease, do not evolve to renal insufficiency and do not resolve with immunosuppressants[19]. A reasonable treatment for these patients is oral bicarbonate.

Glomerulonephritis (GMN), seen in 5% to 10% of the patients is a late manifestation in the course of the disease highly correlated with a more generalized small vessel involvement, manifested as palpable purpura or other vasculitic skin lesions and peripheral neuropathy or B-cell lymphoma[22]. The pathogenesis is most probably attributed to deposition of immune complexes, which are formed by cryoprecipitable monoclonal IgM*k* rheumatoid factor along with polyclonal IgG and IgA, in a manner similar to that observed in renal involvement of hepatitis C cryoglobulinemia[25].

Cryoglobulimaemia and low C4 levels are strong predicting factors for the development pf GM. Low levels of C4 tend to co-exist with the presence of monoclonal cryoglobulins; the association reflects the consumption of complement in the setting of cryoglobulinemia when cryoglobulins are deposited in the vasculature and cause vasculitis under a less or more benign or malignant process of the disease. Three histologic types of GMN have been reported in pSS: membranoproliferative, mesangial proliferative and membranous.
Mesangial proliferative GMN reflects an earlier stage of disease that may subsequently evolve into a more typical membrano-proliferative picture, but it is also conceivable that it could be an independent entity[27, 28, 29]. The most common clinical findings are hypertension, mild proteinuria, and microscopic hematuria the outcome of these patients is diverse. Immunosuppressants (pulse cyclophosphamide and corticosteroids) have been used with beneficial results while some patients may show an evolution to end-stage renal disease[29, 30, 31]. We report this case to raise the clinical suspicion of pSS in patients with nephrogenic diabetes insipidus and other tubular disturbances.

Conclusions

Interstitial nephritis is the typical renal injury in pSS, expressing the classical

histopathological lesions of the disease in different glandular or extraglandular organ systems with functional epithelium. It is common, it appears early in the disease process, it affects younger patients, it may precede the symptoms of xerostomia and xeropthalmia, and is rather benign. It is manifested by hyposthenuria distal renal tubular acidosis and, more rarely, with Fanconi syndrome. Glomerulonephritis may be seen also in pSS patients. This is a rare late event in the course of the disease, expressing a more systemic process including the consumption of complement in the setting of cryoglobulinemia under the development of B-cell lymphoma or a benign vasculitis. Patients with glomerulonephritis may evolve to renal failure.

In summary, our presenting patient presented renal manifestations of pSS, including diabetes insipidus, renal tubular acidosis type I, tubulointerstitial nephritis, and nephrolithiasis. None of these findings are common presentations of pSS. The presence of all of these symptoms in one individual makes this patient an atypical way to diagnose a primary Sjogren's syndrome.

References

1. H. Murata, Y. Kita, A. Sakamoto et al., "Limited TCR repertoire of infiltrating T cells in the kidneys of Sjögren's syndrome patients with interstitial nephritis," The Journal of Immunology, vol. 155, no. 8, pp. 4084-4089, 1995.

2. Y. Itoh, K. Kin, T. Kasahara et al., "Synthesis and secretion of alpha 1-microglobulin by human lymphocytes", Clinical & Experimental Immunology, vol. 37, no. 1, pp. 134-139, 1979.

3. Quin B, Wang J, Yangz, et al.Epidemiology of primary Sjogren's syndrome a systematic review and meta-analysis. Ann Rheum Dis. 2015; 74(11):1983-1989.

4. Fox RI, Stern M, Michelson P. Update in Sjogren's. Curr Opin Rheumatol.2000; 12(5) :391-398.

5. Manthorpe R, Oxholm P, Prause JU, Schiødt M. The Copenhagen criteria for Sjögren's syndrome. Scand J Rheumatol Suppl. 1986; 61:19-21.

6. Vitali C, Bombardieri S, Jonsson R, et al. Classification criteria for Sjögren's syndrome: a revised version of the European criteria proposed by the American-European Consensus Group. Ann Rheum Dis. 2002; 61:554-558.

7. Shiboski SC, Shiboski CH, Criswell L, et al. American College of Rheumatology classification criteria for Sjögren's syndrome: a data-driven, expert consensus approach in the Sjögren's International Col-laborative Clinical Alliance cohort. Arthritis Care Res (Hoboken). 2012; 64:475-487

8. Baldini C, Talarico R, Tzioufas AG, Bombardieri S. Classification criteria for Sjogren's syndrome: a critical review. J Autoimmun. 2012;39: 9-14.

9. Fox RI, Liu AY: Sjögren's syndrome in dermatology. Clin Dermatol, 2006; 24(5): 393-413.

10. Fox RI. Sjogren's syndrome. Lancet.2005; 366 (9482): 321-331.

11. Ramos- Casals M, Brito-Zeron P, Font J. The overlap of for Sjogren's syndrome with other systemic autoimmune diseases. Semin Arhtritis Rheum. 2007; 36(4):246-255.

12. Strombeck B, Ekdahe C, Manthorpe R, et al. Health-related quality of life in primary Sjogren's syndrome, rheumatoid and fibromyalgia compared to normal population data using SF-36. Scand J Rheumatol. 2000; 29(1):20-28.

13. Theander E, Jacobsson LTH: Relationship of Sjögren's syndrome to other connective tissue and autoimmune disorders. Rheum Dis Clin North Am, 2008; 34(4): 935-47.

14. Goules A V, Tatouli IP, Moutsopoulos HM, Tzioufas AG: Clinically significant renal involvement in primary Sjögren's syndrome: Clinical presentation and outcome. Arthritis Rheum, 2013; 65(11): 2945-53.

15. Lim AKH, Choi MJ: Distal renal tubular acidosis associated with Sjögren syndrome. Intern Med J, 2013; 43(12): 1330-34.

16. François H, Mariette X: Renal involvement in primary Sjögren syndrome. Nat Rev Nephrol, 2016; 12(2): 82-93.

17. M. Jallouli, M. Frigui, S. Marzouk et al., "Osteomalacia revealing Sjögren's syndrome: a case report," La Revue de Médecine Interne, vol. 29, no. 4, pp. 311-314, 2008.

18. Goules A, Masouridi S, Tziofas AG, Ioannidis JPA, Skopouli FN, Moutsopoulos HM. Clinically significant and biopsy documented renal involvement in primary Sjögren syndrome. Medicine ,2000;79:241-249.

19. Rosenberg ME, Schendel PB, McCurdy FA, Platt JL. Characterization of immune cells in kidneys from patients with Sjögren syndrome. A J Kidney Dis 1988;11:20-22.

20. Siamopoulos H M, Drosos A. Mavridis A, Moutsopoulos HM. Renal tubular acidosis in primary Sjogren's syndrome, Clin Reumatol 1992; 11:1-5

21. Moutsopoulos HM, C;edes J, Skopouli FN, Elisaf M, Youinoi P. Nephrocalcinosis in Sjogren's syndrome; a late sequela of renal tubular acidosis. J Inter Med 1991;



Internal Medicine

Clinical Cases

230:187-191.

22. Lim AKH, Choi MJ: Distal renal tubular acidosis associated with Sjögren syndrome. Intern Med J, 2013; 43(12): 1330-34

23. Skopouli FN, Dafni U, Ioannidis JPA, Moutsopoulos HM. Clinical evolution and morbidity and mortality of primary Sjogren's syndrome. Semin Arthritis Rheum 2000; 29:296-304.

24. Dowd JE, Lipsky PE. Sjogren's syndrome presenting as hypokalemic periodic paralysis. Arthritis Rheum 1993;12:1735-1738.

25. Pal B, Griffiths ID. Primary Sjogren's syndrome presenting as osteomalacia secondary to renal tubular acidosis. Br J Clin Practice 1988; 42:436-438.

26. Daghestani L, Pomeroy c. renal manifestation of hepatitis C infection. AM J Med 1999; 106:347-354.

27. Maripuri S, Grande JP, Osborn TG et al: Renal involvement in primary Sjögren's syndrome: A clinicopathologic study. Clin J Am Soc Nephrol, 2009; 4(9): 1423-31 13.

28. Evans R, Zdebik A, Ciurtin C, Walsh SB: Renal involvement in primary Sjögren's syndrome. Rheumatology (Oxford), 2015; 54(9): 1541-48 14.

29. Goules A V, Tatouli IP, Moutsopoulos HM, Tzioufas AG: Clinically significant renal involvement in primary Sjögren's syndrome: Clinical presentation and outcome. Arthritis Rheum, 2013; 65(11): 2945-53.

30. Thanou-Stavraki A, James JA: Primary Sjögren's syndrome: Current and pro-spective therapies. Semin Arthritis Rheum, 2008; 37(5): 273-92 17.

31. Tishler M, Yaron I, Shirazi I, Yaron M: Hydroxychloroquine treatment for primary Sjögren's syndrome: Its evet on salivary and serum inflammatory markers. Ann Rheum Dis, 1999; 58: 253-56.