sciendo
Internal Medicine 2022 vol. XIX No. 1 - www.srmi.ro
10.2478/inmed-2022-0194

COMPARATIVE STUDY OF THE LABORATORY, IMAGERY AND THERAPEUTIC PROFILE OF PATIENTS HOSPITALIZED AT THE GASTROENTEROLOGY VERSUS SURGERY DEPARTMENT DIAGNOSED WITH CHOLANGITIS AFTER CHOLECYSTECTOMY

Mariana Ungur
Faculty of Medicine and Pharmacy, University of Oradea, Romania
Address for correspondence: Mariana Ungur
Department of Surgery, Faculty of Medicine and Pharmacy, University of Oradea, Faculty of Medicine and Pharmacy Oradea - 1 Decembrie Street, No. 10, 410068, Oradea, Bihor County, Romania
Email: marianaungur@gmail.com

Abstract

Introduction. *Post-cholecystectomy cholangitis represents a controversial issue within the medical literature due to the polymorphism of the generating causes and due to the difficulties connected to its diagnosis and therapy.*

Material and methods. *The assessment of the study was performed on two batches of patients, namely 221 patients hospitalized at Surgery Departments and another batch of 109 patients hospitalized at the Gastroenterology Department all having post-cholecystectomy cholangitis as their main diagnosis. The assessment criteria were suggestive laboratory and imagery investigations and therapeutic management.*

Results. *If we compare the laboratory profile of both batches, we can see that only the non-specific inflammatory syndrome has shown significant differences statistically (way more frequent in case of patients hospitalized at the Gastroenterology Department), while the biliary-excretion, the cholestatic and hepatic cytolysis syndromes had approximately the same prevalence. In both batches, the treatment methods used were mainly pharmacology methods, and in a small number of cases retrograde endoscopic cholangiopancreatography. There were also a few cases where invasive surgery was applied.*

Conclusion. *An increased clinical suspicion, an early recognition based on laboratory and imagery investigations, a prompt therapy initiation, and a balanced and correct anti-microbial management, endoscopic and surgical, need the implication of complex teams of clinicians.*

Keywords: *cholangitis, choledochal lithiasis, endoscopic retrograde cholangiopancreatography.*



Internal Medicine

Original Papers

Rezumat

Introducere. *Colangita post-colecistectomie reprezintă o problemă controversată în literatura medicală din cauza polimorfismului cauzelor generatoare și a dificultăților legate de diagnostic și terapie.*

Material si metodă. *Au fost incluse în studiu două loturi de pacienți, respectiv 221 pacienți internați în secțiile de chirurgie și un lot de 109 pacienți internați în secția de gastroenterologie, toți având ca diagnostic principal colangita post-colecistectomie. Au fost evaluate investigațiile sugestive de laborator și imagistice și managementul terapeutic.*

Rezultate. *Dacă comparăm profilul de laborator al ambelor loturi, putem observa că doar sindromul inflamator nespecific a prezentat diferențe semnificative statistic (mult mai frecvent în cazul pacienților internați în secția de gastroenterologie), în timp ce excreția biliară, sindroamele de citoliză și colestază hepatică au avut aproximativ aceeași prevalență. În ambele loturi, metodele de tratament utilizate au fost în principal farmacologice, iar într-un număr mic de cazuri colangiopancreatografia endoscopică retrogradă. În câteva cazuri s-a aplicat intervenția chirurgicală invazivă.*

Concluzie. *Suspiciunea clinică crescută, recunoașterea precoce bazată pe investigații de laborator și imagistice, inițierea promptă a terapiei și managementul antimicrobian echilibrat și corect, endoscopic și chirurgical, necesită implicarea unor echipe complexe de clinicieni.*

Cuvinte cheie: *colangită, litiază coledociană, colangiopancreatografie retrogradă endoscopică.*

Introduction

Post-cholecystectomy cholangitis represents a controversial issue within the medical literature due to the polymorphism of the generating causes and due to the difficulties connected to its diagnosis and therapy.

Because of this difficult approach with multiple clinical challenges, a proper multidisciplinary coordination is needed, thus assuring an optimal therapeutic decision. Correct treatment can be applied only after having an accurate diagnosis, based on clinical methods and adequate imagery and laboratory investigations. Avoiding diagnosis mistakes and incorrect therapeutic conducts will increase the comfort and life quality of the patient.

Material and method

The assessment of the study was performed on two batches of patients, namely 221 patients hospitalized at Surgery I and II

Departments and another batch of 109 patients hospitalized at the Gastroenterology Department of the Emergency County Clinical Hospital of Oradea, all having post-cholecystectomy cholangitis as their main diagnosis. The assessment criteria in these two batches were suggestive laboratory and imagery investigations and therapeutic approach methods[1].

The following essential laboratory investigations were used for diagnosis establishment: bile retention samples, hepatic cytolysis tests: aspartate aminotrans-ferase(AST), (alanine aminotransferase, ALT), Gamma-glutamyl transferase (GGT), cellular hypofunction tests, a jeun blood sugar, glycated hemoglobin, coagulation samples: prothrombin time(PT), International Normalized Ratio(INR), blood count, C-Reactive Protein (CRP) test, erythrocyte sedimentation rate test(ESR), electrophoresis, immunoelectrophoresis, samples for renal function exploration[1].

For establishing the etiology of post-cholecystectomy cholangitis, the most frequent imagery investigations used were abdominal ultrasonography, abdominal tomography, cholangio-nuclear magnetic resonance, endoscopic retrograde cholangiopancreatography.

Within the batch of studied patients, for the etiologic diagnosis of post-cholecystectomy cholangitis particularly important information was provided mainly by the abdominal tomography and cholangio-NMR[1,2].

For example, abdominal tomography, performed within the Imagery Department of the County Clinical Hospital of Oradea, has allowed the reasoning of residual choledocal litiasis etiological diagnosis in case of a 68 years old patient, hospitalized with post-cholecystectomy angiocholitis and with a surgical history of biliary-digestive bypass.

The tomographic imagery performed in this case has shown important dilatations of the intra-hepatic bile ducts, more pronounced within the hepatic hilum and left lobe; upstream swelling of the main bile ducts, reaches a maximum caliber of approx. 2 cm.

Abdominal tomography scan allows the reasoning of residual choledocal litiasis etiological diagnosis of post-cholecystectomy cholangitis associated with an intra and extra-hepatic cholestasis syndrome[3]. Cholangio-NMR has shown to be a very useful modern imagery method in establishing the tumoral etiology of the extra-hepatic bile ducts in post-cholecystectomy cholangitis[4].

I would like to note the case of a 52 years old patient, hospitalized with post-cholecystectomy angiocholitis, case in which cholangio-NMR has allowed to set the diagnosis of a vaterian ampulloma. In the projection area of the Ampulla of Vater, an endoluminal polypoid image with a diameter of 7-8 mm is highlighted, which indicates a suspicion of vaterian ampulloma. The Wirsung duct shows an anatomic instance with a separate opening on the level of the duodenum, suprajacent to the vaterian ampulloma.

The dilatations of the intra-hepatic bile ducts are more distinguished in the projection of the left lobe. The dilatation of the main bile ducts reaches a maximum caliber of 8 mm on the level of the hepatic hilum.

For the diagnosis of post-cholecystectomy cholangitis the diagnosis criteria of the Tokyo guide were used[5,6,7,8,9,10]. As treatment methods, pharmacology, interventional endoscopy and, with decreased frequency, surgery (invasive on bile ducts and mini-invasive) were used. As invasive surgery methods, the following were used with very decreased frequency: coledochotomy with Kehr external biliary drainage and



choledochotomy with choledoch-duodenal-anastamosis.

Etiology was established by using the diagnosis criteria of acute cholangitis, based on the Tokyo guide (Tg13). A basic clinical item for establishing a diagnosis of post-cholecystectomy cholangitis is pain within the Charcot triad.

The treatment methods used were mainly pharmacology methods, and in a small number of cases retrograde endoscopic cholangiopancreatography. There were also a few cases where invasive surgery was applied.

Results

By comparing the evolution of the non-specific inflamatory process, we have seen a higher representation of this syndrome with leukocytosis and neutrophilia within the cases hospitalized at the clinical Gastroenterology Department, with post-cholecystectomy angiocholitis ($p<0,0001$).

Thus, from the total number of 109 cases hospitalized at the Gastroenterology Department, in the case of 62 patients with post-cholecystectomy angiocholitis, with a percentage of 56.88%, the non-specific inflammatory syndrome shown within the laboratory assessments as leukocytosis and neutrophilia was dominant.

In 28 cases, with a percentage of 25.68%, laboratory investigations have shown a hepatic cytolysis syndrome and a cholestatic syndrome, and in case of 26 patients, with a percentage of 23.85%, a biliary-excretion syndrome.

As a comparison, within the batch of patients hospitalized at the Surgery Department, from the total number of 221 cases, the biliary-excretion syndrome was present in 42 cases (19%), and the hepatic cytolysis and the cholestatic syndromes was present in 72 cases (32.57%).

The hepatic cytolysis syndrome is more frequently present, in analogy with the alanine aminotransferase (ALAT/GPT), aspartate aminotransferase (ASAT/GOT), gamma-glutamyl transferase (GGT) biological parameters study, in cases hospitalized at the Gastroenterology Department.

In cases of post-cholecystectomy cholangitis within the batch hospitalized at the Surgery Department, research has shown a more frequent presence of an inflammatory syndrome with leukocytosis and neutrophilia and/or biliary excretion syndrome, and/or hepatic cytolysis, cholestatic syndrome. The imagery argumentation of the presence of modifications within the intra and extra-hepatic bile ducts was not present in all studied cases.

Contrary to the cases hospitalized at the Surgery Departments, gamma glutamyl transferases has shown high values in a lower

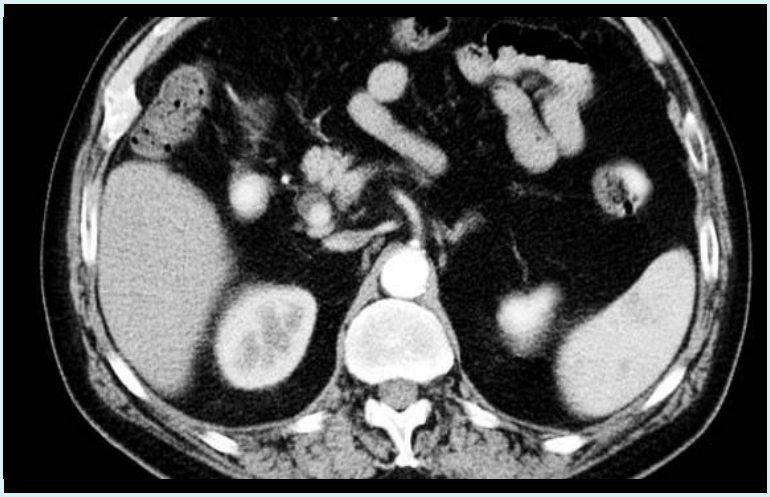

Figure 1. *Dilatation of the distal area of the bile duct and a calculus of 1.1 cm located on the intra-pancreatic choledoc*

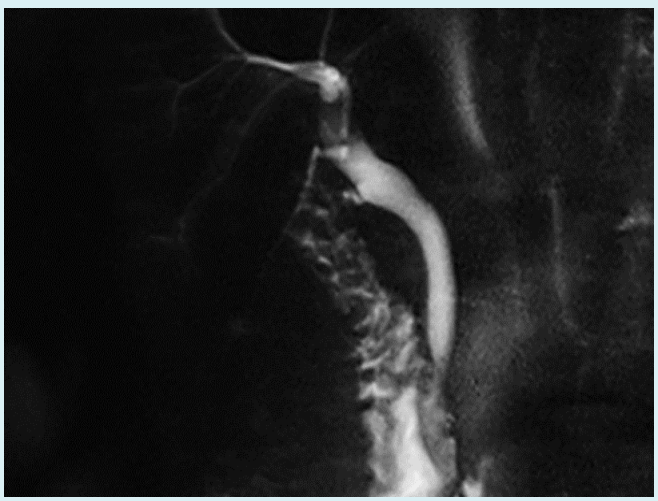

Figure 2. *Obstruction of the terminal area of the choledoch with progressive intra-pancreatic decalibration. Main bile duct stenosis in pencil tip*

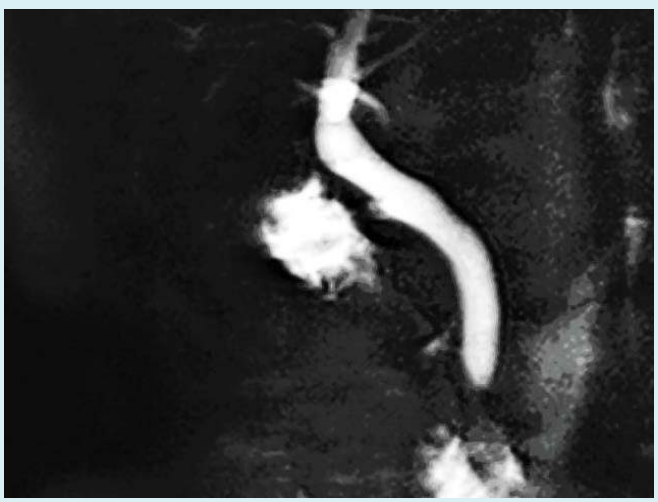

Figure 3. *Swelling of the main bile ducts throughout its entire path*



Internal Medicine

Original Papers

number of cases, and the increase was not that high. In cases hospitalized at the Surgery Department, there were increases in the gamma glutamyl transferases with values up until 10 times the normal value.

Moderate increases in gamma glutamyl transferases were registered in 16 cases, with a percentage of 14.67%, in comparison with gamma glutamyl transferases increases in 44 cases out of the total number of patients hospitalized at the Surgery Department, the percentage being of 19.90%. The hepatic cytolysis syndrome was more severe within the cases hospitalized at the Surgery Departments.

In case of patients hospitalized at the Gastroenterology Department, the non-specific inflammatory syndrome is more predominate, in 62 cases, with a percentage of 56.88%, in comparison with the cases of non-specific inflammatory syndrome present at 50 patients hospitalized with post-cholecystectomy cholangitis at the Surgery Departments (a percentage of 22.62%).

In cases of post-cholecystectomy cholangitis within the batch hospitalized at the Surgery Department, research has shown a more frequent presence of an inflammatory syndrome with leukocytosis and neutrophilia and/or biliary excretion syndrome, and/or hepatic cytolysis, cholestatic syndrome[1].

In both batches of patients, pharmacology treatments were more predominant. Out of the 221 cases from the batch of patients hospitalized at the Surgery Department, in 190 cases the main therapeutic approach was pharmacological, and in the other 31 cases endoscopic and/or surgery procedures were applied. In 8 cases, the therapeutic approach was invasive surgery. The invasive surgery approach has limited indications. Out of the 31 cases, surgery was used in only 8 cases. The indications of an invasive aggressive surgical approach were very limited, in favor of the endoscopic approach.

The results of the statistic studies confirm the significantly higher prevalence of non-specific inflammatory syndrome at patients hospitalized at the Gastroenterology Department. If we compare the paraclinical profile of patients hospitalized at these two departments (Surgery and Gastroenterology), we can see that only the non-specific inflammatory syndrome has shown significant differences statistically (way more frequent in case of patients hospitalized at the Gastroenterology Department), while the biliary-excretion, the cholestatic and hepatic cytolysis syndromes had approximately the same prevalence.

It is interesting to mention the comparison of the gamma glutamyl transferases values at the two batches of patients, thus reflecting a higher severity of the hepatic cytolysis and cholestatic syndromes at patients hospitalized at the Surgery Department, with

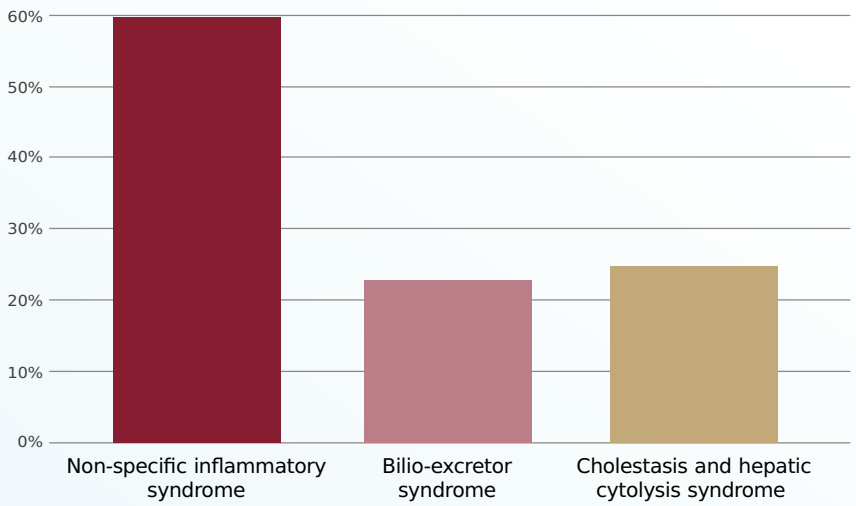

Figure 4. *The profile of laboratory modifications for patients hospitalized at the Gastroenterology Department*

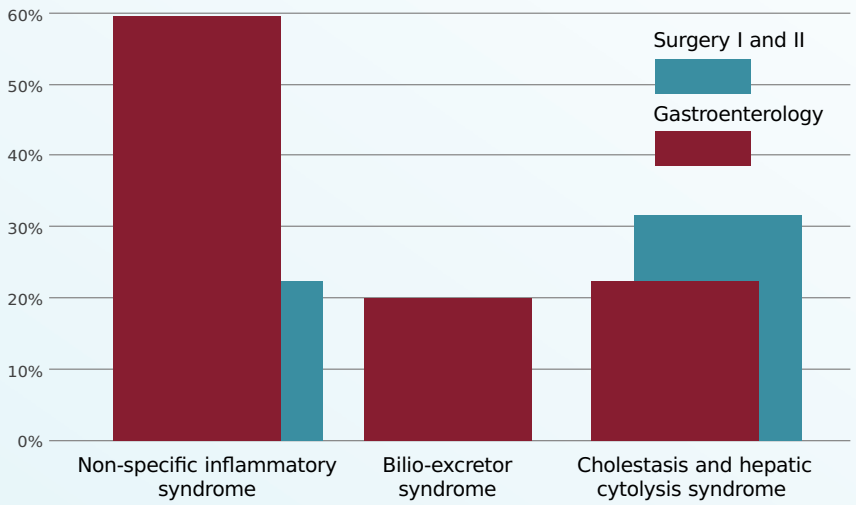

Figure 5. *Comparison between the two study batches based on the modifications of laboratory samples*

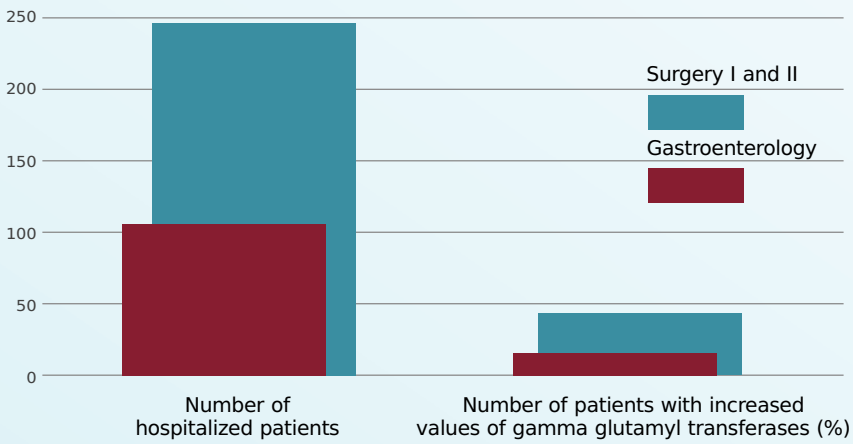

Figure 6. *Distribution of cases increased GGT for the two batches of patients*

	Number of hospitalized patients	Number of patients with increased values of gamma glutamyl transferases (%)		p*
Surgery I and II	221	44	19.90 %	0.3140
Gastroenterology	109	16	14.67%	

** - chi-square test with Yates correction*

Table 1. *Comparative study of the gamma glutamyl transferases values at the two study batches*

this diagnosis of post-cholecystectomy cholangitis, but without reaching the threshold of statistical significance.

Discussions

The most predisposing causes in the development of secondary cholangitis are residual lithiasis of the main bile duct, endoscopic stenting and strictures of the bile and hepatic ducts, malign pancreas pathology and ampullary and peri-ampullary tumoral pathologies[9,11,12].

Residual or relapsing choledochal lithiasis es the most frequent cause in triggering acute post-cholecystectomy angiocholitis.

The second cause with a significant percentage in the etiology of cholangitis is represented by malign tumoral processes: cholangiocarcinoma, pancreas head tumor, ampullary and peri-ampullary tumors.

Laboratory investigations can be suggestive in establishing the lithiasis etiology of post-cholecystectomy cholangitis. It assesses the hepatic functions, the biliary-excretion syndrome, hepatic cytolysis, inflammatory syndrome, clotting function. Direct bilirubin, total bilirubin, serum transaminases, gamma glutamyl transferases, alkaline phosphatase, number of leukocytes, prothrombin time will be dosed.

Extra-hepatic cholestasis is biologically translated through bilirubin increase, mainly direct, between 4 and 10 mg% (maxima of 15%) and increase of cholestasis enzymes (alkaline phosphatase, Gamma-glutamyl transferase, 5 nucleotidase) at values of 3 times over the normal ones, but which return to normal values within 1-2 weeks. Aspartate aminotransferase can show an increase of 2-10 times over the normal values, but, characteristically, it quickly returns to normal values within 48 hours. Pigments and bile salts appear in the urine, and the cholangitis

infectious process is accompanied by leukocytosis, VSH and fibrinogen increase, positive blood cultures. In ascending cholangitis, laboratory data will show marked acute leukocytosis, hyperbilirubinemia, especially direct, high values of tests which confirm alteration of the hepatic function (alkaline phosphatase, transaminases). A number of leukocytes higher than 20.000/ µL and a total bilirubin higher than 10 mg/dl are unfavorable independent prognostic factors in acute cholangitis[13].

Serum bilirubin is an essential indicator in the diagnosis of a jaundice. In benign mechanic jaundices, with incomplete obstruction, bilirubinemia is between 2-15mg%, rarely reaching 25 mg%. If the biliary obstruction is determined by a neoplasm condition, the values of the alkaline phosphatase will be higher than in the case of benign biliary obstruction. The blood cultures samples taken during the tremble or high fever are positive. Laboratory investigations can be suggestive in establishing the of post-cholecystectomy cholangitis diagnosis.

Reference studies found in the specialty literature highlight the importance of determining alkaline phosphatase, serum bilirubin, transaminases, lactic dehydrogenase, lipids, cholesterol, clotting factors[14].

The increase of hepatic enzymes suggests an oddian dysfunction. A history of recurrent pain episodes after cholecystectomy associated with high serum levels of hepatic or pancreatic enzymes indicate a possible papillary stenosis[15,16,17]. The presence of residual choledochal calculi involves various aspects, from an asymptomatic type to suppurative cholangitis, sepsis, multiple organs and systems dysfunction syndrome, death.

Residual choledochal lithiasis, representing the most frequent obstructive etiology in post-cholecystectomy angiocholitis, needs a therapeutic approach which is different from the conservatory pharmacological approach, namely an endoscopic or surgery approach[18].

As mentioned before, choledochal lithiasis represents the most frequent benign obstructive etiology in case of post-cholecystectomy cholangitis.

The results of the statistic studies confirm the significantly higher prevalence of non-specific inflammatory syndrome at patients hospitalized at the Gastroenterology Department.

If we compare the paraclinical profile of patients hospitalized at these two departments (Surgery and Gastroenterology), we can see that only the non-specific inflammatory syndrome has shown significant differences statistically (way more frequent in case of patients hospitalized at the Gastroenterology Department), while the biliary-excretion, the cholestatic and hepatic cytolysis syndromes had approximately the same prevalence.

It is interesting to mention the comparison of the gamma glutamyl transferases values at the two batches of patients, thus reflecting a higher severity of the hepatic cytolysis and cholestatic syndromes at patients hospitalized at the Surgery Department, with this diagnosis of post-cholecystectomy cholangitis, but without reaching the threshold of statistical significance.

In cases of post-cholecystectomy cholangitis, within the batch hospitalized at the Surgery and Gastroenterology Departments, research has shown a more frequent presence of an inflammatory syndrome with leukocytosis and neutrophilia and/or biliary excretion syndrome, and/or hepatic cytolysis, cholestatic syndrome.

Post-cholecystectomy cholangitis creates modifications of the intra-hepatic and extra-hepatic bile ducts, which are translated through imagery investigations, with their



dilatation, with or without parietal modifications, with or without obstructive injuries on the distal choledoc[19]. The main basic items in the present therapeutic approach of acute cholangitis are anti-microbial therapy and biliary decom-pression[20]. If after the initial antibiotic treatment the condition of the patient improves, bile drainage will be performed: either endoscopically - through retrograde cholangiopancreatography, or percutaneously - through transhepatic cholangiography, or, in extreme situations, invasive surgery is performed[21,22,23,24,25,26,27,28,29,30,31,32].

Conclusion

In our modern developed world, post-cholecystectomy cholangitis will show a continuously increased prevalence. An increased clinical suspicion, an early recognition based on laboratory and imagery investigations, a prompt therapy initiation, and a balanced and correct anti-microbial management, endoscopic and surgical, need the implication of complex teams of clinicians with an extensive practical experience. All these circumstances create the premise for reaching optimal results[33].

References

1. Ungur M, Babes Pa, Maghiar A, Pop Gm, Feder B. Diagnosis and Therapeutic Management in Postcholecistectomy Alithiasic Cholangitis. Mædica. 2019 Sep;14(3):247.

2. Mayumi T, Okamoto K, Takada T, et al. Tokyo Guidelines 2018: management bundles for acute cholangitis and cholecystitis. J Hepatobiliary Pancreat Sci. 2018;25(1):96-100. doi:10.1002/jhbp.519

3. Takada T. Tokyo Guidelines 2018: updated Tokyo Guidelines for the management of acute cholangitis/acute cholecystitis. J Hepatobiliary Pancreat Sci. 2018;25(1):1-2. doi:10.1002/jhbp.526

4. Kiriyama S, Kozaka K, Takada T, et al. Tokyo Guidelines 2018: diagnostic criteria and severity grading of acute cholangitis (with videos). J Hepatobiliary Pancreat Sci. 2018;25(1):17-30. doi:10.1002/jhbp.512

5. Strasberg SM. Tokyo Guidelines for the Diagnosis of Acute Cholecystitis. J Am Coll Surg. 2018;227(6):624. doi:10.1016/j.jamcollsurg.2018.09.005

6. Sokal A, Sauvanet A, Fantin B, de Lastours V. Acute cholangitis: Diagnosis and management. J Visc Surg. 2019;156(6):515-525. doi:10.1016/j.jviscsurg.2019.05.007

7. Nishino T, Hamano T, Mitsunaga Y, et al. Clinical evaluation of the Tokyo Guidelines 2013 for severity assessment of acute cholangitis. J Hepatobiliary Pancreat Sci. 2014;21(12):841-849. doi:10.1002/jhbp.189

8. Sulzer JK, Ocuin LM. Cholangitis: Causes, Diagnosis, and Management. Surg Clin North Am. 2019;99(2):175-184. doi:10.1016/j.suc.2018.11.002

9. Lan Cheong Wah D, Christophi C, Muralidharan V. Acute cholangitis: current concepts. ANZ J Surg. 2017;87(7-8):554-559. doi:10.1111/ans.13981

10. Schwed AC, Boggs MM, Pham XD, et al. Association of Admission Laboratory Values and the Timing of Endoscopic Retrograde Cholangiopancreatography with Clinical Outcomes in Acute Cholangitis. JAMA Surg.2016;151(11):1039–1045. doi:10.1001/jamasurg.2016.2329

11. Lee JM, Boll DT. Disease of the Gallbladder and Biliary Tree. In: Hodler J, Kubik-Huch RA, von Schulthess GK, eds. Diseases of the Abdomen and Pelvis 2018-2021: Diagnostic Imaging - IDKD Book. Cham (CH): Springer;

2018:49-56.
12. Beliaev A.M., Booth M., Rowbotham D., Bergin C. Diagnostic inflammatory markers in acute cholangitis. (2018) Journal of Surgical Research, 228, pp. 35-41.
13. Acute Cholangitis Management: Prevention of Organ Failure and Death. JAMA Surg. 2016 Nov 1;151(11):1045. doi: 10.1001/jamasurg.2016.2351.
14. Garancini, Mattia, et al. "Updates in the Management of Cholecystitis, Cholangitis, and Obstructive Jaundice. "Operative Techniques and Recent Advances in Acute Care and Emergency Surgery. Springer, Cham, 2019. 455-468.
15. Takada, T., Strasberg, S. M., Solomkin, J. S., Pitt, H. A., Gomi, H., Yoshida, M., ... & Büchler, M. W. (2013). TG13: Updated Tokyo Guidelines for the management of acute cholangitis and cholecystitis. Journal of Hepato-Biliary-Pancreatic Sciences, 20(1), 1-7.
16. Juza, Ryan M., and Eric M. Pauli."Endoscopic Management of Acute Biliopancreatic Disorders. "Journal of Gastrointestinal Surgery (2019): 1-14.
17. Bukur, Marko, and Jaclyn Clark. "Acute Cholangitis. "Emergency General Surgery. Springer, Cham, 2019. 151-164.
18. Williams E, Beckingham I, El Sayed G., et al. Updated guideline on the management of common bile duct stones (CBDS). Gut 2017; 66 (05) 765-782)
19. Tomizawa M, Shinozaki F, Hasegawa R, et al. Comparison of acute cholangitis with or without common bile duct dilatation. Exp Ther Med. 2017;13(6): 3497-3502.doi:10.3892/etm.2017.4401)
20. Gomi H, Takada T, Hwang TL., et al. Updated comprehensive epidemiology, microbiology, and outcomes among patients with acute cholangitis. J Hepatobiliary Pancreat Sci 2017; 24 (06) 310-318)
21. Acute Cholangitis Management: Prevention of Organ Failure and Death. JAMA Surg. 2016 Nov 1;151(11):1045. doi: 10.1001/jamasurg.2016.2351.
22. Garancini, Mattia, et al. "Updates in the Management of Cholecystitis, Cholangitis, and Obstructive Jaundice. "Operative Techniques and Recent Advances in Acute Care and Emergency Surgery. Springer, Cham, 2019. 455-468.
23. Takada, T., Strasberg, S. M., Solomkin, J. S., Pitt, H. A., Gomi, H., Yoshida, M., ... & Büchler, M. W. (2013). TG13: Updated Tokyo Guidelines for the management of acute cholangitis and cholecystitis. Journal of Hepato-Biliary-Pancreatic Sciences, 20(1), 1-7.
24. Juza, Ryan M., and Eric M. Pauli."Endoscopic Management of Acute Biliopancreatic Disorders. "Journal of Gastrointestinal Surgery (2019): 1-14.
25. Bukur, Marko, and Jaclyn Clark. "Acute Cholangitis. "Emergency General Surgery. Springer, Cham, 2019. 151-164.
26. Mulki R, Shah R, Qayed E. Early vs late endoscopic retrograde cholangiopancreatography in patients with acute cholangitis: A nationwide analysis. World J Gastrointest Endosc. 2019;11(1):41-53.
27. Du L, Cen M, Zheng X, Luo L, Siddiqui A, Kim JJ. Timing of Performing Endoscopic Retrograde Cholangiopancreatography and Inpatient Mortality in Acute Cholangitis: A Systematic Review and Meta-Analysis. Clin Transl Gastroenterol. 2020;11(3):e00158. doi:10.14309/ctg.0000000000000158
28. Hou LA, Laine L, Motamedi N, Sahakian A, Lane C, Buxbaum J. Optimal Timing of Endoscopic Retrograde Cholangiopancreatography in Acute Cholangitis. J Clin Gastroenterol. 2017;51(6):534-538. doi:10.1097/ MCG.0000000000000763
29. González-Moreno EI, Jáquez-Quintana JO, González-González JA, Maldonado-Garza HJ. Endoscopic Retrograde Cholangiopancreatography (ERCP) and Acute Cholangitis: The Sooner, the Better. J Clin Gastroenterol. 2019;53(4):318. doi:10.1097/ MCG.0000 000000000891
30. Parikh, Malav P. MD*; Wadhwa, Vaibhav MD†; Thota, Prashanthi N. MD‡; Lopez, Rocio MS§; Sanaka, Madhusudhan R. MD, FACG, FASGE‡ Outcomes Associated With Timing of ERCP in Acute Cholangitis Secondary to Choledocholithiasis, Journal of Clinical Gastroenterology: November/December 2018 - Volume 52 - Issue 10 - p e97-e102 doi: 10.1097/ MCG.00000000 00000982
31. Navuluri R, Hoyer M, Osman M, Fergus J. Emergent Treatment of Acute Cholangitis and Acute Cholecystitis. Semin Intervent Radiol. 2020;37(1):14-23. doi:10.1055/ s-0039-3402016)
32. Miura F, Okamoto K, Takada T, et al. Tokyo Guidelines 2018: initial management of acute biliary infection and flowchart for acute cholangitis. J Hepatobiliary Pancreat Sci. 2018;25(1):31-40. doi:10.1002/jhbp.509)
33. Park CS, Jeong HS, Kim KB., et al. Urgent ERCP for acute cholangitis reduces mortality and hospital stay in elderly and very elderly patients. Hepatobiliary Pancreat Dis Int 2016; 15 (06) 619- 625)