sciendo Internal Medicine 2021 vol. XVIII No. 4 - www.srmi.ro 77
10.2478/inmed-2021-0177

CLOSTRIDIUM DIFFICILE INFECTION AND BILIARY OBSTRUCTION

Marilena Stoian[1,2], Victor Stoica[1,2]
[1]University of Medicine and Pharmacy „Carol Davila", Bucharest, Romania
[2]„Dr. Ion Cantacuzino" Clinical Hospital, Bucharest, Romania

Abstract
We are presenting a case of a 38-year -old man was admitted to the hospital with biliary obstruction and Clostridium Difficile infection. The hepatic biochemical profile improved during corticosteroid therapy, which is a change more characteristic of autoimmune hepatitis than of primary sclerosing cholangitis, needs for a positive diagnostic an endoscopic retrograde cholangiopancreatography and a biopsy of gastric and duodenum mucosae. The abnormalities in the results of liver-function tests due to primary sclerosing cholangitis may have been resulted in part to the intestinal inflammation due to Crohn disease; the abnormalities improved with therapy directed at suppressing that inflammation.
Keywords: *Crohn disease, endoscopic retrograde cholangiopancreatography, primary sclerosing cholangitis, Clostridium Difficile infection.*

Rezumat
Prezentăm cazul unui bărbat în vârstă de 38 de ani, care a fost internat pentru obstrucție biliară și infecție cu Clostridium difficile. Profilul biochimic hepatic s-a îmbunătățit în timpul terapiei cu corticosteroizi, aspect care este mai caracteristic pentru hepatita autoimună decât pentru colangita sclerozantă primitivă. În vederea diagnosticului pozitiv, s-a efectuat colangiopancreatografie retrogradă endoscopică și biopsie din mucoasa gastrică și duodenală. Anomaliile rezultatelor testelor hepatice ca urmare a colangitei sclerozante primare pot fi cauzate parțial de inflamația intestinală în contextul bolii Crohn; anomaliile s-au îmbunătățit odată cu terapia ce a vizat suprimarea inflamației.
Cuvinte cheie: *boală Crohn, colangiopancreatografie retrogradă endoscopică, colangită sclerozantă primitivă, infecție cu Clostridium difficile.*



Internal Medicine

Clinical Cases

A 38-year -old man was admitted to the hospital because of evidence of biliary obstruction and 3 kg lost in weight during the last two weeks. One year before admission, the patient was admitted to another hospital because of bloody diarrhea, when the serum aspartate aminotransferase level was 100 U per liter and a test for *Clostridium Difficile* was positive.

He had not taken antibiotics before the onset of symptoms and it was prescribed one month of metronidazole. The patient condition was well until several weeks before admission, when he began to have no radiating collicative pain in the epigastrium, right upper quadrant, and periumbilical area; the pain was exacerbated by eating and was accompanied by nausea. He also began to have intermittent loose stools without frequent or voluminous diarrhea. During the two weeks before admission, his temperature rose intermittently to 38.3^{0}C.

Five days before admission, the patient had left-sided pleuritic chest pain and a dry cough. He went to another hospital, where leukocytosis with a left-ward shift was found. Findings on a radiograph of the chest suggested the presence of pneumonia of the right lower lobe; there was bilateral prominence of the interstitial markings. An abdominal ultrasonographic examination revealed no abnormalities and because the pain was constant and the no medication effective the patient was transferred to our hospital.

The patient was an advocate with no history of the use of alcohol and no family history of inflammatory bowel disease or rheumatic disorders. The temperature was 37.8^0 C, the pulse was 85, the respiration rate was 20, and the blood pressure was 120/55 mmHg. Physical examination revealed mild scleral icterus and marked tenderness over the sternum on palpation, with abdomen soft with slight tenderness in the right upper quadrant; there was no hepatomegaly. No protozoa or helminthic ova were found on microscopical examination of the stool; assay of a stool culture yielded no enteric pathogens.

The urine was positive for bile and for urobilinogen. Laboratory test were performed (Tables 1, 2, 3). Radiographs of the chest revealed bilateral prominence of the interstitial markings. An ultrasonographic examination of the abdomen showed that the liver had a normal texture and the intrahepatic ducts and the common bile duct were of normal diameter.

The gallbladder was partially collapsed; the pancreas appeared normal. Ranitidine, Cephotaxime and Acetaminophen were given, but the patient s temperature rose into the evening to 39.7^{0}C. On the second hospital day, the patient`s temperature did not exceed 39^{0}C and the abdominal pain had

Variable	On admission	Second hospital day
Hematocrit %	36.8	
White-cell count (per mm^3)	16,000	
Differential count %		
Neutrophils	86	
Lymphocytes	7	
Monocytes	5	
Eosinophils	2	
Platelet count (per mm^3)	504,000	
Prothrombin time(sec)	12.9	13.5
Partial- thromboplastin time (sec)	35.3	36.8

Table 1. *Blood Chemical and Enzyme Values*

Variable	Five days before admission	On admission
Albumin (g/dl)	3.1	2.3
Bilirubin (mg/dl)		
Total	2	3.1
Conjugated	1	2.6
Cholesterol(mg/dl)		104
Alanine aminotransferase (U/liter)	144	108
Aspartate aminotransferase(U/liter)	74	119
Alkaline phosphatase (U/liter)	601	629
Amylase		Normal
Lipase		Normal

Table 2. *Hematologic laboratory values*

Variable	Results
Test for antinuclear antibodies	Positive 1:180
Test for anti-smooth-muscle antibodies	Positive 1:80
Test for antimitochondrial antibodies	Negative
Test for hepatitis A	Negative
Test for hepatitis B	Negative
Test for hepatitis C	Negative

Table 3. *Results of laboratory tests*



Internal Medicine

Clinical Cases

ceased. A computed tomographic (CT) examination of the abdomen and pelvis performed after the oral and intravenous administration of contrast material, revealed no abnormalities.

A stool test for Clostridium Difficile toxin was positive at that time and although the illness responded to metronidazole, community-acquired Clostridium Difficile - related disease would be unusual in a young man, particularly in the absence of known predisposing factors. Only 1 to 3 percent of adults are healthy carriers of Clostridium Difficile[1,2].

The most common risk factors for the acquisition of clinical Clostridium Difficile related disease are hospitalization and the use of antibiotics; other risk factors include advanced age, previous nonsurgical gastrointestinal procedures, an immunocompromised state, and the presence of underlying factors[3, 4]. However, it was reported that Clostridium Difficile infection may be associated with a relapse of symptoms in patients with inflammatory bowel disease, in whom this infection can occur even in the absence of antibiotic use[5]. In our case metronidazole was given for one month, which is longer than the recommended length of treatment for an uncomplicated Clostridium Difficile infection[6,7].

During the initial illness, the patient also had a slightly elevated aspartate aminotransferase level, a finding that is not usually associated with *Clostridium Difficile* infection and that could be explained by a variety of acute or chronic diseases; most of them were ruled out out by his subsequent clinical course and the results of his laboratory tests.

The **differential diagnosis** in this case should focus on clinical disorders that can cause *intestinal* disease as well as *hepatobiliary* disease (Figure 1). The two major diseases or categories of disease than can explain this patient s intestinal disorder are celiac sprue and inflammatory bowel disease.

Celiac sprue is a well-recognized cause of enteric loss of protein and enteric malabsorption. There is a documented association between celiac sprue and autoimmune liver diseases, including autoimmune hepatitis, primary biliary cirrhosis, and primary sclerosing cholangitis[8-20]. Nonspecific elevations in aminotransferase levels are common and usually resolve with a gluten-free diet. Celiac sprue is an unlikely diagnosis in the current case, because this illness generally develops in adults or in children who are younger than this patient. In addition, an acute onset of marked upper gastrointestinal symptoms is atypical of celiac disease, although in this case such symptoms could be related to the liver disease.

Our patient`s illness is most consistent with

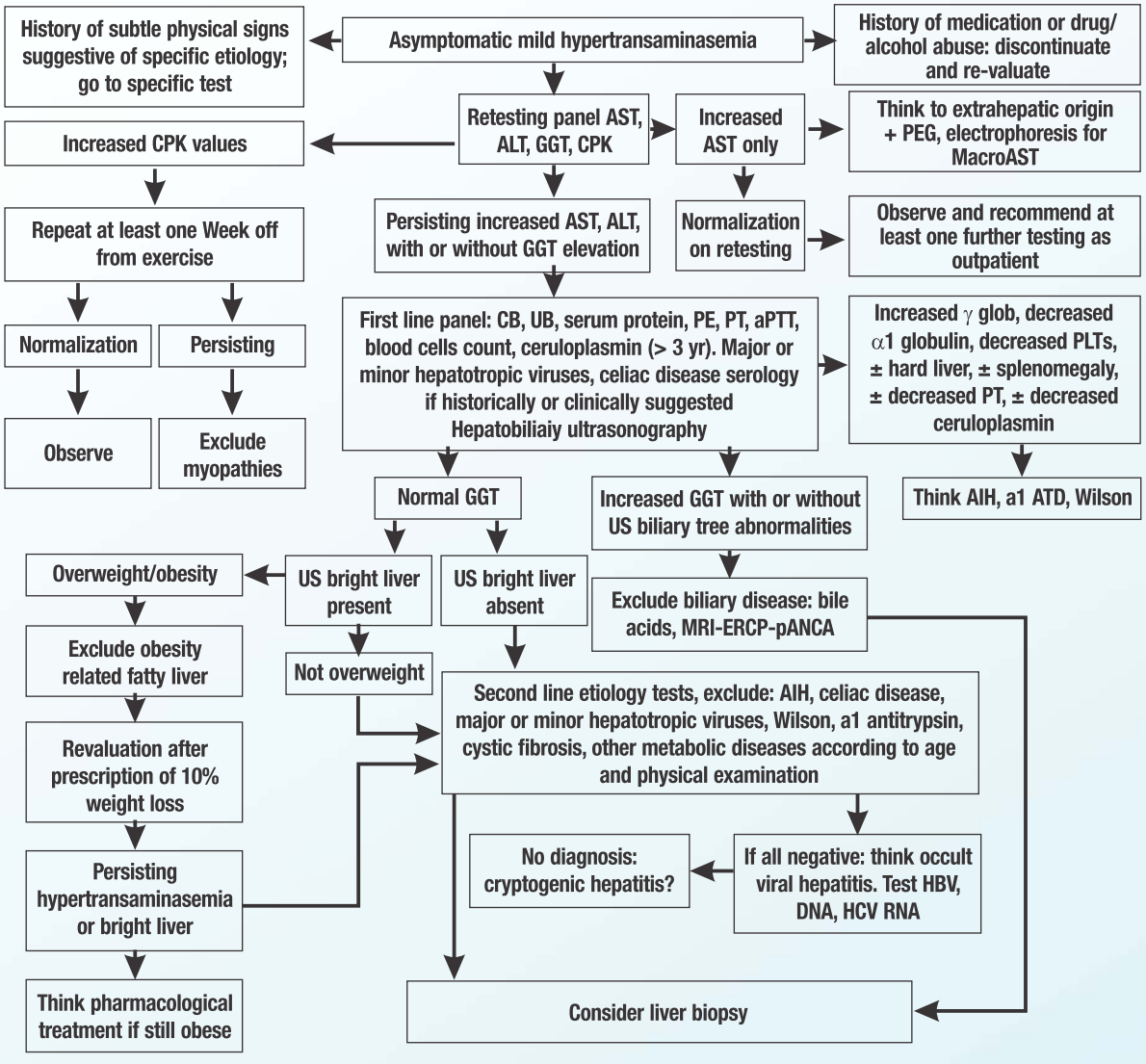

Figure 1. *Algorithm for diagnosis of hypertransaminaemia*

the diagnosis of inflammatory bowel disease. Both ulcerative colitis and Crohn`s disease are associated with intestinal protein loss and hepatobiliary disorders, including autoimmune diseases[21, 22, 23, 24]. The initial signs, symptoms, and laboratory findings that suggest inflammatory bowel disease include diarrhea, fever, wight loss, leukocytosis, thrombocytosis, and occult blood in the stool. The patient`s substernal pain may have been due to esophageal involvement. Upper gastrointestinal involvement is more common in children with inflammatory bowel disease than in adults. In one series, 80 percent of patients with Crohn`s disease and 75 percent of those with ulcerative colitis had endoscopic abnormalities such as esophagitis, gastritis, duodenitis, and upper gastrointestinal ulcers[25,26].

The findings on radiographic and laboratory evaluation of the patient`s hepatobiliary disease eliminate a number of disorders from differential diagnosis. Abdominal CT and ultrasonographic studies did not reveal evidence of stones, gallbladder disease, or biliary tract dilatation, and the liver appeared to have a normal texture. Autoimmune liver



Internal Medicine

Clinical Cases

diseases are common in both ulcerative colitis and Crohn`s disease. On the other hand, both primary sclerosing cholangitis and autoimmune hepatitis also occur in association with inflammatory bowel disease. Sclerosing cholangitis can involve the extrahepatic ducts, the intrahepatic ducts, or both. The frequency of this disorder in patients with inflammatory bowel disease is about 10 percent[24]. Autoimmune hepatitis characteristically involves the hepatic parenchyma, although there are variant overlap syndromes with features of both autoimmune hepatitis and primary sclerosing cholangitis. These disorders can be differentiated by endoscopic retrograde cholangiopancreatography, evaluation of autoimmune markers, and liver biopsy. In our case, the results of marker studies are inconclusive, but a test for perinuclear antineutrophil cytoplasmatic antibodies might have been diagnostically helpful (Table 4).

The **clinical diagnosis** of autoimmune hepatobiliary disease associated with inflammatory bowel disease is based on the patients s symptoms and the presence of a protein-losing enteropathy which are more suggestive of Crohn disease, while moderate increases in the aminotransferase levels in proportion to the increase in the bilirubin level suggesting the diagnosis of primary sclerosing cholangitis.

For the **pathological diagnosis** the first diagnostic procedure proposed was a liver biopsy, but considering the insufficiency of technical resources and no positive patient`s accord for this procedure we performed an endoscopic retrograde cholangiopancreatographic study.

It was ruled out obstruction of the extrahepatic bile ducts, a condition that can be associated with hepatic changes similar to those of primary sclerosing cholangitis. Examination of the both gastric fundus (Figure 2) and the duodenum (Figure 3) showed severe inflammation and an epithelioid granuloma in the gastric wall; there was patchy, superficial inflammation as well as deep acute and chronic inflammation. All of these findings are diagnostic of Crohn disease.

We decided to begin **treatment** with ursodiol (300 mg twice daily) and prednisone (20 mg daily), treatment administrated for 4weeks since the biochemical values return to normal, except for 5- nucleotidase value, which remained slightly elevated. The dose of prednisone was tapered during 6 months until discontinued and replaced with mesalamine.

Thirty-six months after the diagnoses were made, the patient s aminotransferase levels were still slightly elevated, and his gamma-glutamyl-transferase level was still moderate elevated. A repeat endoscopic retrograde

Marker	Positive test result	Negative test result	Result in current case
Antinuclear antibodies	Autoimmune hepatitis Primary sclerosing cholangitis		Weakly positive
Anti- smooth-muscle antibodies	Autoimmune hepatitis Primary sclerosing cholangitis		Positive
Antimitochondrial antibodies	Primary biliary cirrhosis	Autoimmune hepatitis Primary sclerosing cholangitis	Negative
Perinuclear antineutrophil cytoplasmatic antibodies	Primary sclerosing cholangitis		Not reported

Table 4. *Markers of Autoimmune Liver Disease*

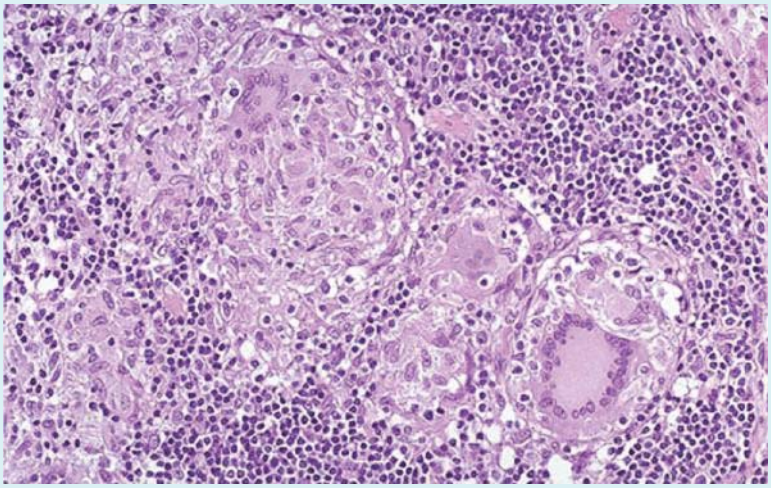

Figure 2. *Specimen of the Gastric Fundus (Hematoxylin and Eosin, x 125) There is a granulomatous reaction around a damaged gastric gland*

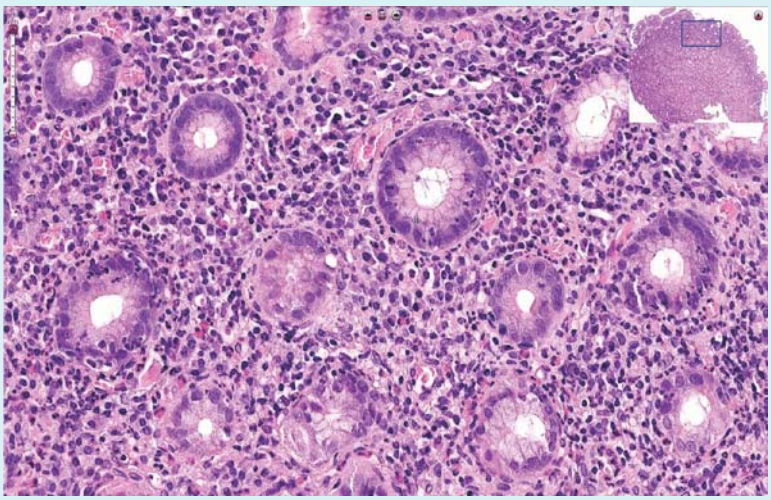

Figure 3. *Specimen of the Duodenum (Hematoxylin and Eosin x 125) The central duct is acutely inflamed and ruptured and is surrounded by acute and chronic inflammation*



cholangiopancreatogram showed no change in the degree of narrowing of the intrahepatic bile ducts. Once the synthetic function of the liver is sufficiently compromised, the only therapeutic option is transplantation. Ursodiol lowers the aminotransferase levels and improves the biochemical profile but does not affect the long-term outcome[27].

References

1. *Kaufman E, Liska D, Rubinshteyn V, Nandakumar G. Clostridium difficile bacteremia. Surg Infect (Larchmt). 2013 Dec;14(6):559-60.*
2. *Kyne L, Warny M, Qamar A, Kelly CP. Asymptomatic carriage of Clostridium difficile and serum levels of IgG antibody against toxin A. N Engl J Med 2000; 342: 390– 7.*
3. *Bignardi GE.Risk factors for Clostridium difficile infection. J Hosp Infect 1998; 40:1-15.*
4. *Søes LM, Holt HM, Böttiger B, Nielsen HV, Andreasen V, Kemp M, Olsen KE, Ethelberg S, Mølbak K. Risk factors for Clostridium difficile infection in the community: a case-control study in patients in general practice, Denmark, 2009-2011. Epidemiol Infect. 2014 Jul;142(7):1437-48.*
5. *Gryboski JD.Clostridium difficile in inflammatory bowel disease relapse.J Pediatr Gastronterol Nutr 1991;13:39-41.*
6. *Farne HA, Martin NK, Main J, Orchard T, Tyrrell-Price J. C-reactive protein is a useful predictor of metronidazole treatment failure in mild-to-moderate Clostridium difficile infection. Eur J Gastroenterol Hepatol. 2013 Jan;25(1):33-6.*
7. *Dupont HL. Diagnosis and management of Clostridium difficile infection. Clin Gastroenterol Hepatol. 2013 Oct;11(10):1216-23.*
8. *Kingham JG, Parker DR. The association between primary biliary cirrhosis and celiac disease: a study of relative prevalences. Gut. 1998;42(1):120–122*
9. *Dickey W, McMillan SA, Callender ME. High prevalence of celiac sprue among patients with primary biliary cirrhosis. J Clin Gastroenterol. 1997;25(1):328–329.*
10. *Sorensen HT, Thulstrup AM, Blomqvist P, Norgaard B, Fonager K, Ekbom A. Risk of primary biliary cirrhosis in patients with celiac disease: Danish and Swedish cohort data. Gut. 1999;44(5):736–738*
11. *Gillett HR, Cauch-Dudek K, Jenny E, Heathcote EJ, Freeman HJ. Prevalence of IgA antibodies to endomysium and tissue transglutaminase in primary biliary cirrhosis. Can J Gastroenterol. 2000;14(8):672–675.*
12. *Volta U, Rodrigo L, Granito A, et al. Celiac disease in autoimmune cholestatic liver disorders. Am J Gastroenterol. 2002;97(10):2609–2613.*
13. *Floreani A, Betterle C, Baragiotta A, et al. Prevalence of celiac disease in primary biliary cirrhosis and of antimitochondrial antibodies in adult celiac disease patients in Italy. Dig Liver Dis. 2002;34(4):258–261*
14. *Bizzaro N, Villalta D, Tonutti E, et al. IgA and IgG tissue transglutaminase antibody prevalence and clinical significance in connective tissue diseases, inflammatory bowel disease, and primary biliary cirrhosis. Dig Dis Sci. 2003;48(12):2360–2365.*
15. *Lawson A, West J, Aithal GP, Logan RF. Autoimmune cholestatic liver disease in people with celiac disease: a population-based study of their association. Aliment Pharmacol Ther. 2005;21(4):401–405*
16. *Hay JE, Wiesner RH, Shorter RG, LaRusso NF, Baldus WP. Primary sclerosing cholangitis and celiac disease. A novel association. Ann Intern Med. 1988;109(9): 713–717.*
17. *Freeman HJ, Kwan WC. Occult celiac disease associated with lymphocytic sclerosing cholangitis. Can J Gastroenterol. 1994; 8:249–252.*
18. *Venturini I, Cosenza R, Miglioli L, et al. Adult celiac disease and primary sclerosing cholangitis: two case reports. Hepatogastroenterology. 1998;45(25): 2344–2347.*
19. *Wurm P, Dixon AD, Rathbone BJ. Ulcerative colitis, primary sclerosing cholangitis and celiac disease: two cases and review of the literature. Eur J Gastroenterol*

Hepatol. 2003;15(7):815–817.
20. Al-Osaimi AM, Berg CL. Association of primary sclerosing cholangitis and celiac disease: a case report and review of the literature. Dig Dis Sci. 2004;49(3):438–443.
21. Issa M, Vijayapal A, Graham MB, et al. Impact of Clostridium difficile on inflammatory bowel disease. Clin Gastroenterol Hepatol 2007; 5: 345–51
22. Powell N, Jung SE, Krishnan B. Clostridium difficile infection and inflammatory bowel disease: a marker for disease extent? Gut 2008; 57: 1183–4
23. Khor B, Gardet A, Xavier RJ. Genetics and pathogenesis of inflammatory bowel disease. Nature 2011; 474: 307–17.
24. Heikius B, Niemela S, Lehtola J,Karttunen T, Lahde S.Hepatobiliary and coexisting pancreatic duct abnomarmalities in patients with inflammatory bowel disease.Scand J Gastroenterol 1997;32:153-61.
25. Pascarella F, Martinelli M, Miele E, Del Pezzo M, Roscetto E, Staiano A. Impact of Clostridium difficile infection on pediatric inflammatory bowel disease. J Pediatr 2009
26. Jen MH, Saxena S, Bottle A, Aylin P, Pollok RC. Increased health burden associated with Clostridium difficile diarrhoea in patients with inflammatory bowel disease. Aliment Pharmacol Ther 2011; 33: 1322–31
27. Jodorkovsky D, Young Y, Abreu MT. Clinical outcomes of patients with ulcerative colitis and co-existing Clostridium difficile infection. Dig Dis Sci 2010; 55: 415–20.