sciendo Internal Medicine 2021 vol. XVIII No. 4 - www.srmi.ro 47
10.2478/inmed-2021-0174

A CLINICAL CASE OF ACUTE POLYARTHRITIS UNMASKING SEVERE COMORBIDITY

Andra Carmina Ciotoracu[1], Mădălina Dună[1], Denisa Predețeanu[1,3], Constantin-Ioan Busuioc[1], Săvulescu Florin Alexandru[2], Bogdan Aramă[2], Ștefan Ion[2,4]
[1]Sf. Maria" Clinical Hospital, Bucharest, Romania
[2]"Dr. Carol Davila" Central Military Emergency Hospital, Bucharest, Romania
[3]"Carol Davila", University of Medicine and Pharmacy, Bucharest, Romania
[4]"Titu Maiorescu" University of Medicine, Bucharest, Romania
Corresponding author: Andra Carmina Ciotoracu
e-mail: andra_carmina7@yahoo.com

ABSTRACT
Acute polyarthritis requires a comprehensive differential diagnosis in order to establish its etiology. Moreover, sometimes it may unfold unexpected comorbidities, thus necessitating an individualized management approach.
This article describes the case of an elderly patient whose initial presentation of acute polyarthritis was interpreted as crystal induced-arthritis demonstrated by the presence of calcium pyrophosphate and lipid crystals in the synovial fluid. The clinical deterioration of the patient along with the suspicion of a systemic infection required interdisciplinary collaboration and led to his transfer to the infectious diseases department where the diagnosis of sepsis from unknown origin was added. Further investigations unmasked a large complicated pancreatic pseudocyst that eventually ruptured into the peritoneal cavity and led to the patient's death.
Keywords: *crystal induced arthritis, sepsis, septic arthritis, red man syndrome, abdominal mass.*

Abstract
Poliartrita acută necesită un diagnostic diferențial amplu în vederea identificării etiologiei sale. Mai mult, uneori poate dezvălui comorbidități neașteptate, necesitând o abordare individualizată. Acest articol descrie cazul unui pacient vârstnic a cărui prezentare inițială ca poliartrită acută a fost interpretată ca artrită indusă de cristale, demonstrată prin prezența cristalelor de pirofosfat de calciu și a cristalelor lipidice în lichidul sinovial. Deteriorarea clinică a pacientului și suspiciunea unei infecții sistemice au necesitat colaborare interdisciplinară și au determinat transferul său în departamentul de boli infecțioase, unde diagnosticul de sepsis cu punct de plecare necunoscut a fost adăugat. Investigații suplimentare au dezvăluit prezența unui pseudochist pancreatic de dimensiuni mari, complicat, care ulterior, prin perforare în cavitatea peritoneală, a determinat decesul pacientului.
Cuvinte cheie: *artrită indusă de cristale, sepsis, artrită septică, sindromul omului roșu, tumoră abdominală*

Internal Medicine

Clinical Cases

Introduction

Acute polyarthritis, defined by the involvement of at least five joints in the arthritic process, can be caused by a variety of diseases. In order to establish its etiology, extensive investigation based on the medical history of the patient, together with clinical examination, imaging and laboratory tests need to be put together. In some cases, the complex diagnostic process may unfold unexpected comorbidities, thus requiring an individualized management approach. Crystal-induced arthritis and joint infection are two of the major causes that need to be taken into consideration when facing up to a sudden onset of inflammatory arthritis characterized by swelling, local increased temperature, redness and severe pain with reduced range of motion. The presence of one does not exclude the other, as they can coexist and make the clinician's approach even more challenging.
Crystalline arthropathies are caused by the deposition of certain types of crystals (monosodium urate (MSU), calcium pyrophosphate (CPP) or lipid crystals) in the joints and the soft tissues around them. A precipitating factor such as sepsis or trauma can be responsible for the release of crystals from the site of prior deposition causing an inflammatory response and explaining thus the coexistence of different types of crystals with septic arthritis[1].

This article describes the case of an elderly patient whose initial presentation of acute polyarthritis was interpreted as crystal induced-arthritis, demonstrated by the presence of CPP and lipid crystals in the synovial fluid. The clinical deterioration of the patient along with the suspicion of a systemic infection required interdisciplinary collaboration and led to his transfer to the infectious diseases department where the diagnosis of sepsis from unknown origin was added. Further investigations unmasked a large abdominal mass that eventually ruptured into the peritoneal cavity and led to the patient's death.

Case report

We present the case of an 80 year old man, with no history of joint disease, who was hospitalized in our rheumatology department for debilitating arthritides of both hands, elbows and of the right foot, that first appeared 2 weeks prior to admission. He had a normal weight, no associated immunocompromising condition, no previous arthritis flare or pancreatitis. He denied intravenous drug abuse and reported occasional beer consumption. The only treatment he was taking on a daily basis was an angiotensin-converting enzyme inhibitor for blood pressure control. After a detailed anamnesis, the patient revealed that about 2 months



Figure 1. *Different stages of the patient's polyarthritis*

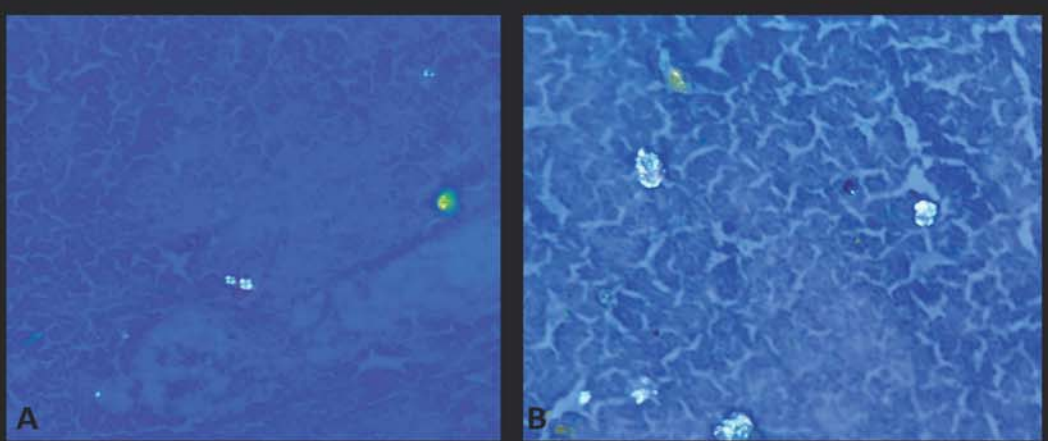

Figure 2. *Polarization microscopy of synovial fluid revealing lipid crystals with characteristic Maltese-cross configuration (A) and calcium pyrophosphate crystals (B)*

Internal Medicine

Clinical Cases

before the current hospital admission he had self-removed the fingernail from the fifth finger of the right foot after trimming it. This led to local injury, with tumefaction and redness of the area. He was diagnosed in a private dermatology office with cellulitis and treated with antibiotics. The exact course of the events was difficult to restore as the patient was not able to describe in detail what had happened, but we retain that he had been previously treated with several antibiotics, some of them being oxacillin, amoxicillin-clavulanic acid and gentamicin. Not long after finishing the antibiotic treatment, with apparent remission of the local inflammation, he developed arthritis of the right hallux. Progressively, he noticed that his hands and elbows also had begun swelling. The patient denied any urologic complaints.

The physical examination revealed Celsian clinical features of acute inflammation characterized by redness, swelling, local warmth, pain and decreased range of motion of the right hallux, Ist, IIIrd and IVth fingers of the left hand, Ist finger of the right hand and both elbows (Figure 1.A1,B1,C1).

Laboratory tests showed increased inflammatory markers (C-reactive protein 186 mg/L, fibrinogen 883 mg/dL, ESR 92 mm/h), neutrophilic leucocytosis (leukocytes 15000/µL, neutrophils 11400/µL), mild normocytic normochromic anemia (haemoglobin 12 g/dL), procalcitonin, PSA, rheumatoid factor within normal ranges and low blood uric acid concentrations. Serum protein electrophoresis revealed a low level of albumin and an increase in alpha-1 and alpha-2 fractions. Ultrasound of the hands and elbows displayed olecranon bursitis and small joints synovitis of the hands. The large joint effusion encompassed hyperechoic spots, being suggestive of microcrystals aggregates. Plain radiography of the hands and chest radiography were normal and echocardiography showed no sign of infectious endocarditis. Treatment was initiated with colchicine, dexamethasone and 2nd generation cephalosporin together with vancomycin as empiric antimicrobial therapy. After 3 days of treatment, no clinical and biological improvement was noticed. Arthrocentesis from the Ist finger of the right hand was performed and the synovial fluid, with high viscosity and a turbid appearance, was sent for analysis. Biochemical tests, aerobic and anaerobic culture and crystals analysis, using polarized light microscopy, were performed on the sample. The tests results showed normal glucose, protein and complement levels and absence of rheumatoid factor as well as morphologically different shaped crystals suggestive for CPP (Figure 2. B) and lipid crystals (Figure 2. A). Consequently, the positive diagnosis of crystal-induced arthritis (lipid droplets and



Figure 3. *Erythematous rash of the trunk and upper extremities*

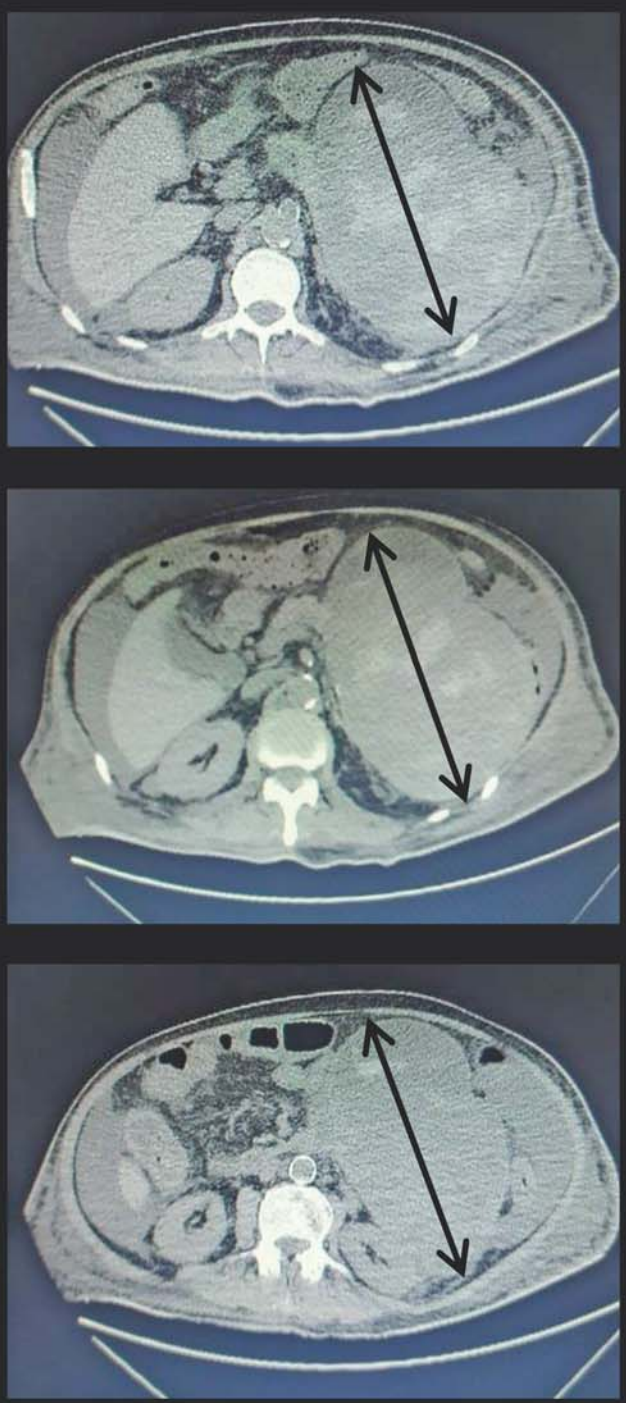

Figure 4. *CT scan revealing a large abdominal tumoral mass (black arrow)*



Internal Medicine

Clinical Cases

CPP crystals) was established. The inflammation in the soft tissues corresponding to the anterior part of the foot and small interphalangeal joints worsened and developed a fluctuant appearance (Figure 1. A2, B2, C2). During hospitalisation the patient had one episode of fever and blood cultures were performed with a negative result.

The decision to transfer the patient in a department of infectious diseases was taken in the context of his unfavourable evolution. Repeated blood cultures were performed as well as a culture test from the collection localized on the right anterior part of the foot. One of the blood cultures revealed the presence of Staphylococcus epidermidis, while the culture taken from the foot lesion was negative.

The possibility of blood culture contamination was evaluated, but considering the patient's bad evolution with persistent biological inflammation and joint tumefaction, tailored antibiotic therapy based on antibiogram was chosen. Urine culture, initially negative, when repeated in the infectious disease department was found positive for Candida parapsilosis, probably being caused by prolonged antibiotherapy. Intravenous vancomycin, meropenem and tigecycline were administered for 13 days and fluconazole for 7 days with a decrease in leucocytosis and inflammatory markers. On the 11th day of antibiotherapy the patient developed a pruritic erythematous rash of the extremities and torso (Figure 3). He was hemodynamically stable, with no chest pain, dyspnea or muscle spasm and received oral antihistaminic treatment with temporary remission. On the 13th day the rash reappeared and the diagnosis of “red man syndrome” related to vancomycin was made. The previous antibiotic treatment was stopped and replaced until the 25th day with clindamycin and rifampicin.

Despite the improvement of the clinical articular and cutaneous manifestations (Figure 1. A3, B3, C3) along with the decrease in leucocytosis and inflammatory markers, during hospitalisation the patient developed significant ascites along with a drop in haemoglobin level from 11,5 g/dL to 6 g/dL, with microcytic, hypochromic features, low serum protein levels (total protein level 4,4 g/dL, serum albumin 2,2 g/dL) and slightly elevated lipase levels (99U/L; normal range 3-67 UI/L).

Amylase and triglycerides levels were in normal range. A computed tomography (CT) examination of the thorax, abdomen and pelvis was requested and showed a large abdominal mass of 16,7/18,2/12,8 cm localized in the left hypochondrium, with no clear boundaries in relation to the pancreas and splenic flexure of the colon, with a lobulated contour of its left wall. The structure was heterogeneous, with a fluid

content of 10 HU radiodensity mixed with non-iodophilic dense areas of 60-65 HU (Figure 4). The differential diagnosis of the tumoral mass included a haemorrhagic complication of a pancreatic pseudocyst and a pancreatic cystic neoplasm. The CT also revealed a normal pancreatic duct, important pleural and pericardic effusions as well as ascites in the subphrenic space, in the peri-hepato-splenic region and also in the iliac fossae.

The patient was transferred in the surgery department, but refused further investigations. Several days after, his general condition deteriorated and he developed an acute abdomen. An emergency intervention revealed peritonitis caused by rupture of the tumoral mass in the peritoneal cavity, which eventually led to the patient's death. The post-mortem histopathological analysis of the tumoral mass revealed a necrotico-hemorrhagic lesion, with sparse inflammatory cells and yellow-brown pigment suggestive for billary pigment. No atypical cells were present in the examined tissue.

The final diagnosis of this case was of acute polyarticular crystal-induced arthritis with overlapped systemic infection caused by *Streptococcus epidermidis*. Despite the initial good evolution under antibiotherapy, the patient's clinical status progressively deteriorated and unmasked a severe comorbidity represented by a large complicated pancreatic pseudocyst. The rupture of this abdominal mass into the peritoneal cavity led to the patient's demise.

Discussion

The presented clinical case, which was initially considered severe polyarthritis in relation to the detected crystals in the synovial fluid, progressively unmasked a severe comorbidity. After correlation with the patient's clinical history and other paraclinical investigations several diagnostic hypotheses were raised.

To begin with, in both crystal- arthritis induced and septic arthritis the patient can present a sudden onset arthritis accompanied by fever, leucocytosis and increased synthesis of acute phase reactants. Thus is sometimes impossible to distinguish between them without further testing.

Various clinical manifestations are possible in crystal-induced arthritis as it can be monoarticular, oligoarticular or polyarticular and it can affect large as well as small joints. Sometimes systemic symptoms such as fever and malaise can be associated[2]. Based on the clinical manifestations, together with the increased inflammatory biomarkers, crystal induced arthritis (specifically gout) was initially presumed and low dose corticosteroid therapy and colchicine were initiated. Frequently, in elderly people, gout is known to have a polyarticular presentation[3]. Moreover, our patient was also hypertensive, a condition that can be associated with polyarticular gout[4].

Regardless of the clinical suspicion, the synovial fluid analysis did not show MSU crystals. In contrast, it revealed rhomboid shaped CPP crystals, with positive birefringence and also, lipid crystals with characteristic Maltese-cross. CPP crystal presence in the synovial fluid is diagnostic for calcium pyrophosphate disease. One study found an average age of 72 years for patients diagnosed with calcium pyrophosphate disease(5)[5], this being consistent with our patient's age. Besides CPP crystals, lipid crystals can also be responsible for acute arthritis, as it was illustrated in several case reports[6, 7]. The pathogenesis of lipid crystals accumulation in the synovial fluid is not



Internal Medicine

Clinical Cases

completely known, but some of the incriminated mechanisms are trauma, hyperlipidemia or the breakdown of the cell membranes phospholipids[8]. As it was previously hypothesized, changes in the pH or alteration of other substances in the joint space caused by the live bacteria or the destruction of the cartilage by the hydrolytic enzymes released during the septic process could represent possible explanations of the coexistence of different types of crystals in the same joint[1]. The patient had normal serum cholesterol and triglycerides levels.

Septic arthritis is a serious, life-threatening condition that can develop as a result of haematogenous seeding or as a result of a local invasive procedure such as joint aspiration or corticosteroid infiltration. Sometimes it can appear after trauma, with extension from an adjacent focus of infection. The definitive diagnosis is made by correctly identifying the responsible pathogen. Most commonly septic arthritis is monomicrobial. Nevertheless, polymicrobial cases have been reported in the setting of penetrating trauma and appear to involve more frequently small joints. The two most common causative pathogens of septic arthritis in Europe are *Staphylococcus aureus* and *Streptococcus spp.*, but in particular cases, such as immunosuppression or trauma, gram negative bacilli can also be a cause of joint infection[9, 10]. The fingernail trauma mentioned by the patient could represent a possible source of infection that was improperly managed in its initial stage.

Synovial fluid should be obtained before any treatment, its analysis being a valuable procedure that can offer guidance in the investigation of arthritis. It encompasses macroscopic evaluation, cell counts, biochemical tests, crystal identification as well as microbiology. Although white blood cell count and the percentage of polymorphonuclear cells from synovial fluid do not distinguish between septic and crystal-induced arthritis, it can help differentiate between inflammatory and non-inflammatory disease. On the other hand, synovial fluid chemistry appears to be highly unhelpful when distinguishing between septic arthritis and other causes of arthritis, as glucose and protein levels can appear normal, as in our patient's case[11].

Gram stains are based on a method of staining that helps distinguish between gram negative and gram positive bacteria and also enables visualisation of morphological characteristics such as size, shape and arrangement of the involved bacteria, being thus an important tool in choosing the empiric antibiotic treatment prior to obtaining the culture results[12]. Shmerling's paper estimated a sensitivity of synovial fluid analysis of 50-75% for Gram stain and 75-95% for culture in non-gonococcal infections

without prior antibiotic treatment[11, 13]. Post-antibiotic treatment testing could decrease synovial fluid yield, favouring false negative results in up 30-80% of cases[14].

Premature antibiotic administration before sampling for bacterial culture in septic patients can lead to prolonged hospital stay and higher mortality rate due to increased risk of *Clostridium Difficile* infection[15]. Moreover, it can be one of the reasons why culture from the synovial fluid can be persistently negative despite clinical evidence of infection. The mechanism that stands behind the reduction of the culture yield is represented by the induction of the so called "viable but non-culturable state" (VBNC) or the induction of persister cells, which are not detectable when using routine culture-based techniques. VBNC cells, despite having an intact membrane and being metabolically active, have various aspects that differentiate them from culturable cells. These aspects include changes in cell size and in membrane structure along with decreased metabolic activity, enabling a higher chemical and physical resistance[16, 17]. Although being costly and not readily available, molecular testing could represent a better technique with higher sensitivity in diagnosing joint infection, especially in the setting of prior antibiotic administration and negative culture[18]. In the discussed case, several antibiotics were administered before performing culture analysis on the samples obtained from the patient. Therefore, there is a high likelihood of false negative results, all the more that molecular testing was not performed.

It is also important to consider probe contamination when interpreting the results of a blood culture, especially when only one out of many is found positive. Thus, the treatment decision is often based on the physician's medical work experience and by correlating the result with the patient's history and physical examination, peripheral leukocyte count, clinical evolution and other culture results. In a study that evaluated 500 episodes of septicaemia, *Staphylococcus epidermidis* was a contaminant in 94% of cases (153 out of 163 cases), while *Staphylococcus aureus* was a contaminant in only 25% of cases (23 out of 91 cases)[19]. (19) Considering the fact that the patient had multiple negative blood cultures, the possibility of probe contamination was considered. Nonetheless, his general condition was deteriorating and based on clinical judgement tailored antibiotic treatment based on the antibiogram report was chosen.

As with any other drug, when prescribing antibiotics, side effects should always be taken into consideration. "Red man syndrome" is a hypersensitivity reaction frequently associated with the initial rapid infusion of 1 g of vancomycin in less than 100 minutes or at a rate higher than 10 mg/minute. Nevertheless, it can also first appear after several doses and with a slow infusion and also with the administration of other antibiotics such as ciprofloxacin, teicoplanin, amphotericinB or rifampicin. The management depends on the signs and symptoms as they can range from mild or moderate (erythema, pruritus, flushing) to severe (dyspnea, chest pain, muscle spasms, hypotension). For mild and moderate reactions interruption of the infusion and oral or intravenous antihistaminic administration are usually sufficient, while for severe reactions accompanied by hypotension and anaphylaxis fluid resuscitation and intramuscular epinephrine is required[20, 21]. In the presented case, the patient had a



moderate reaction and recovered after oral antihistaminic treatment together with the elimination of the causative agent.

The abdominal mass identified on the CT scan raised two diagnostic hypotheses that needed to be further investigated: a complicated pancreatic pseudocyst and a cystic pancreatic neoplasm.

In some cases, when the patient has a suggestive clinical history and the imaging evaluation has a typical appearance, definite diagnosis can be made. However, in many cases, CT or MRI alone is not enough[22]. In these situations, fine needle aspiration under ultrasound or CT guidance along with analysis of the cyst fluid can help in the diagnostic process. In the case of pancreatic pseudocyst rupture, pleural effusion and pancreatic ascites may develop. This is a possibility that is worth taking into consideration in our patient as the CT scan revealed both ascites and pleural effusion. Although not performed in the presented case, a paracentesis can offer valuable information based on biochemical analysis (amylase, albumin and total protein level) as well as cell count, gram stain and culture analysis. A high amylase concentration could point to the pancreatic origin of the fluid[23].

Another diagnostic entity that needs to be included in the differential diagnosis of the presented case is represented by paraneoplastic inflammatory arthritis that could be secondary to a cystic pancreatic neoplasm. In our patient, the post-mortem histopathological report from the tumoral mass excluded a neoplastic process and was consistent with a complicated pancreatic pseudocyst.

Conclusions

We reported a case of severe acute polyarthritis in an elderly man with hypertensive disease and no other known comorbidities at the time of admission. Synovial fluid analysis showed both CPP and lipid crystals that could partially explain the patient's clinical presentation. The presence of CPP crystals in an elderly person is a common finding that always needs to be taken into consideration in the differential diagnosis of each acute episode of arthritis. Nevertheless, other etiologies cannot be overlooked and must be searched through extensive paraclinical investigations. In this case, different hypotheses were raised that could be responsible for the initial presentation and for the gradual clinical deterioration. The suspicion of a systemic infection determined us to follow an interdisciplinary approach in order to provide treatment in patients' best interests. Interdisciplinary collaboration is essential and should always be a priority when managing a patient with a complex disease.

A particularity of the case is represented by the large abdominal mass revealed by the CT examination which eventually led to the patient's demise by perforating into the peritoneal cavity. Post-mortem examination was consistent with a complicated pancreatic pseudocyst, an unexpected finding with unknown origin.

References

1. Septic arthritis, gout, pseudogout and osteoarthritis in the knee of a patient with multiple myeloma. Smith, J R and Phelps, P. 1, 1972, Arthritis & Rheumatism, Vol. 15, pp. 89-96.

2. Calcium pyrophosphate crystal deposition disease: diagnosis and treatment. Rosales-Alexander, J L, Balsalobre Aznar, J and Magro-Checa, C. 2014, Open Access Rheumatol., Vol. 6, pp. 39-47.

3. Gout in the elderly. Clinical presentation and treatment. Fam, AG. 3, 1998, Drugs Aging, Vol. 13, pp. 229-243.

4. Acute polyarticular gout. Raddatz, D A, Mahowald, M L and Bilka, P J. 1983, Annals ofthe Rheumatic Diseases, Vol. 42, pp. 117-112.

5. Rosenthal, AK. Pseudogout: Presentation, natural history, and associated conditions. Crystal-Induced Arthropathies: Gout, Pseudogout, and Apatite-Associated Syndromes. s.l. : Taylor and Francis Group, 2006, p. 99.

6. Acute monoarthritis associated with lipid liquid. Reginato, A J, et al., et al. 1985, Annals of the Rheumatic Diseases, Vol. 44, pp. 537-543.

7. Acute Monoarthritis Associated with Positively Birefringent Maltese Cross Appearing Lipid Spherules in a Hyperlipidemic Diabetic Patient. Park, Y B, Lee, K S and Song, CH. 4, 1997, Yonsei Medical Journal , Vol. 38, pp. 236-239.

8. Acute monoarticular arthritis caused by Maltese cross-like crystals. Dylewski, J, Awan, Z and Roy, I. 6, 2005, CMAJ, Vol. 172.

9. Acute Septic Arthritis. Shirtliff, Mark E and Mader, Jon T. 4, s.l. : Clinical Microbiology Reviews, 2002, Vol. 15, pp. 527-544.

10. Epidemiology, Management, and Outcomes of Large and Small Native Joint Septic Arthritis in Adults. McBride, S, et al., et al. 2, 2020, Clin Infect Dis, Vol. 70, pp. 271-279.

11. Synovial fluid tests. What should be ordered? Shmerling, R H, et al., et al. 8, 1990, JAMA, Vol. 264, pp. 1009-1014.

12. A Guide to Bacterial Culture Identification And Results Interpretation. Giuliano , C, Patel, C R and Kale-Pradham, P B. 4, s.l. : 192-200, 2019, P&T, Vol. 44.

13. Synovial fluid analysis. A critical reappraisal. Shmerling, R H. 2, 1994, Rheum Dis Clin North Am., Vol. 20, pp. 503-512.

14. The value of synovial fluid assays in the diagnosis of joint disease: a literature survey. Swan, A. 6, 2002, Ann Rheum Dis, Vol. 61.

15. Implications of culture collection after the first antimicrobial dose in septic emergency department patients. Cascone, V J, et al., et al. 5, 2019, Am J Emerg Med, Vol. 37, pp. 947-951.

16. Relationship between the Viable but Nonculturable State and Antibiotic Persister Cells. Ayrapetyan, M, Williams, T and Oliver, J D. 20, 2018, Journal of bacteriology, Vol. 200.

17. The importance of the viable but non-culturable state in human bacterial pathogens. Li, L, et al., et al. 2, 2014, Front Microbiol., Vol. 258.

18. Think Twice before Prescribing Antibiotics for That Swollen Knee: The Influence of Antibiotics on the Diagnosis of Periprosthetic Joint Infection. Goh, G S and Parvizi, J. 2, 2021, Antibiotics (Basel), Vol. 10.

19. The Clinical Significance of Positive Blood Cultures: A Comprehensive Analysis of 500 Episodes of Bacteremia and Fungemia in Adults. I. Laboratory and Epidemiologic Observations. Weinstein, M P, et al., et al. Clinical Infectious Diseases, Vol. 5, pp. 35-53.

20. Red man syndrome. Sivagnanam, S and Deleu, D. 2, 2003, Crit Care, Vol. 7, pp. 119-120.

21. Vancomycin and the red-man syndrome: pharmacodynamics of histamine release. Polck, R E, et al., et al. 3, 1988, J Infect Dis, Vol. 157, pp. 502-507.

22. Imaging Diagnosis of Cystic Pancreatic Lesions: Pseudocyst versus Nonpseudocyst. Young, H K, et al., et al. 3, 2005, RadioGraphics, Vol. 25, pp. 671-685.

23. Prakash, K. Pancreatic Ascites and Pleural Effusion, Pancreatitis - Treatment and Complications. https://www.intechopen.com/books/pancreatitis-treatment-and-complications/pancreatic-ascites-and-pleural-effusion. [Online] 03 2012.