DOI: 10.2478/cipms-2022-0022 Curr. Issues Pharm. Med. Sci., Vol. 35, No. 3, Pages 116-122

sciendo

Current Issues in Pharmacy and Medical Sciences

Formerly ANNALES UNIVERSITATIS MARIAE CURIE-SKLODOWSKA, SECTIO DDD, PHARMACIA

journal homepage: http://www.curipms.umlub.pl/

Atrial fibrillation ablation: the position of computed tomography in pre-procedural imaging

Milena Stachyra[1], Andrzej Glowniak[2*], Elzbieta Czekajska-Chehab[3]

[1] Department of Cardiology, S. Wyszynski Hospital, Lublin, Poland
[2] Department of Cardiology, Medical University of Lublin, Poland
[3] Department of Radiology, Medical University of Lublin, Poland

ARTICLE INFO

Received: 15 May 2022
Accepted: 04 August 2022

Keywords:
atrial fibrillation ablation, pulmonary veins isolation, computed tomography, ovality index.

ABSTRACT

Atrial fibrillation (AF) is the most common supraventricular arrhythmia. Despite significant advances in its treatment, it still remains one of the leading causes of cardiovascular morbidity and mortality. In the last two decades, pulmonary vein isolation (PVI) was developed as the most effective treatment option. The reported effectiveness of a single ablation procedure ranges from 40% to 69% with single, and up to 88% with repeated procedures, with acceptable safety profile. The PubMed database was searched, using terms including 'atrial fibrillation ablation', 'pulmonary vein isolation', 'computed tomography', 'pulmonary vein anatomy' and 'ovality index'. Papers were reviewed for relevance and scientific merit. Different imaging techniques are used for pre-procedural assessment of left atrial (LA) anatomy, of which computed tomography (CT) is the most common. It allows assessing pulmonary vein (PV) anatomy, the LA wall thickness in different regions and the left atrial appendage (LAA) anatomy, together with excluding the presence of intracardiac thrombi. Pre-procedural PVs imaging is important regardless of the selected ablation technique, however, cryoballoon (CB) ablation seems to be particularly anatomy-dependent. Additionally, CT also permits assessment of several PVs characteristics (geometry, dimensions, angulations, the ostium area, orientation and ovality index (OI), which are essential for the patients' qualification and designing the strategy of AF ablation. In this paper, we have reviewed the role of CT imaging in patients undergoing ablation procedure due to recurrent/symptomatic atrial fibrillation. Moreover, we discussed the relevant literature.

Atrial fibrillation (AF) is the most common supraventricular arrhythmia – increasing five-fold the risk of stroke and doubling the risk of death [1]. Over the past 20 years, catheter ablation has become the recognized treatment option, superior to antiarrhythmic drugs, and the electrical isolation of all pulmonary veins (PVs) is considered a cornerstone of AF ablation, both in patients with preserved and reduced left ventricular ejection fraction [2-15]. The exact data regarding the left atrial (LA) anatomy are crucial for the adequate choice of the most suitable ablation technique, prediction of the expected long-term outcome and recognition of possible risk factors [16]. Computed tomography (CT) is a commonly used tool for assessing LA anatomy and its derivatives. CT scan allows calculating the LA size and shape, estimating the wall thickness and visualizing the left atrial appendage (LAA), which allows excluding possible thrombi. Moreover, CT provides detailed information regarding the number, geometry and dimensions of pulmonary veins, as well as the presence of any anatomical variations.

* **Corresponding author**
e-mail: andrzejglowniak@umlub.pl

LEFT ATRIAL ANATOMY

There is a large diversity in the LA anatomical structure, and this variability mainly regards the PVs configuration and the anatomy of the LAA. Computed tomography, particularly with three-dimensional (3D) imaging, is considered the preferable tool for detailed LA assessment [17,18]. The complete information that is derived regarding the atrial wall thickness in specific regions of the left atrium and the relationship with adjacent structures allows increasing safety and achieving better outcome of the ablation procedure, with lowered risk of possible complications. Atrio-esophageal

© 2022 Author(s). This is an open access article distributed under the Creative Commons Attribution-NonComercial-No Derivs licence (http://creativecommons.org/licenses/by-nc-nd/3.0/)

fistula can be a lethal complication following catheter ablation of atrial fibrillation [19,20].

Three major types of relationship between the esophagus and posterior LA have been observed (type 1 – close to the left-sided PVs; type 2 – oblique course from the left superior PV to the right inferior PV; type 3 – close to the right-sided PVs) (Fig. 1). The esophageal and atrial walls are fairly thin. According to Lemola *et al*., the mean thicknesses of the posterior LA and anterior esophageal walls are 2.2±0.9 and 3.6±1.7 mm. What is more, in 98% of all patients, there is a fat layer between the esophagus and the posterior LA. As this layer is often discontinuous, pre-procedural CT scanning is important for deciding the location of the ablation lesions around the PV ostia and LA and for avoiding the potential risk of esophageal injury [21-23].

Figure 1. 3D volume rendering. The esophagus course close to the left common pulmonary vein (type 1)

The ridge of Marshall, located between the left atrial appendage and the left superior pulmonary vein (LSPV) and the (usually thinner) ridge between right-sided pulmonary veins are the crucial structures having potential influence on the AF ablation parameters and long-term outcome. Potential anatomy-dependent difficulties with obtaining catheter stability in these places may result in incomplete ablation lines or delivery of lesions too deep in the vein, which can lead to pulmonary vein stenosis [24-26].

Comprehensive knowledge of the atrial anatomy can reduce the incidence of adverse events, both major (like rare, although frequently fatal atrio-esophageal fistula) and minor (like usually transient phrenic nerve injury). Pre-procedural CT imaging with precise calculation of atrial wall thickness in strategic regions like the mitral isthmus, LAA ridge, LA roof and posterior wall, helps to adequately titrate the power of radiofrequency (RF) energy applications in specific areas. Moreover, CT image can aid in evaluating the anatomical features of structural remodeling, and therefore allows identifying patients with high probability of post-ablation AF recurrence. There is, for example, vast data suggesting larger atrial dimensions/volume is associated with higher risk of AF recurrence after ablation [27].

Apart from the dimensions, the shape of the LA roof also has an important role; in patients with more flattened atrial roof, usually more additional applications beyond the pulmonary veins are needed [28].

INTRACARDIAC THROMBUS

Pre-procedural visualization of LAA to exclude the presence of intracardiac thrombi is a prerequisite for the safe ablation procedure. Catheter maneuvers within the LA can lead to detachment and fragmentation of possible embolic material, which can result in thromboembolic events (TEs) such as transient ischemic attacks (TIAs) and strokes. Even though transesophageal echocardiography (TEE) still remains the gold standard for LAA thrombi detection, CT scanning has proved useful. Still, while Dorenkamp at al. reported its good specificity and negative predictive value (NPV, both of 98%), they also noted its poor sensitivity (20%), and therefore have questioned its reliability for LAA thrombi detection [29]. However, according to a recent study that used only CT for excluding the presence of thromboembolic material, the effectiveness of AF ablation without increasing the risk of TEs was enhanced – the authors reported no TEs in 70 consecutive patients undergoing CBA procedure [30]. Furthermore, several well-populated studies [31-34] reveal that CT shows similar accuracy to TEE in LAA thrombi detection. Indeed, in a propensity-matched multicenter analysis comparing pre-procedural use of TEE versus CT (which enrolled 1147 patients), no differences were found in the incidence of periprocedural strokes between the two methods [31]. In addition, both the sensitivity and NPV of the multi-detector computed tomography (MDCT) was rated 100%.

As it is particularly recommended to exclude the presence of LA/LAA thromboembolic material in patients with low to medium risk of TEs, the American Society of Echocardiography recommends performing CT scans rather than TEE (as a safer alternative) in patients with oropharyngeal and esophageal disorders. It is also indicated in patients experiencing difficulties/intolerance of esophageal intubation [35].

LEFT ATRIAL APPENDAGE

CT imaging allows assessing the anatomy, volume and type of LAA take-off (higher/lower). There are four morphological variants of LAA: cactus, chicken-wing, cauliflower and windsock. Several studies have evaluated the relationship between its shape and the incidence of thromboembolic events. Increased trabeculations and smaller LAA orifice dimensions are associated with more frequent TEs. This observation confirms the earlier claim, that cauliflower LAA morphology promotes the occurrence of TIA and strokes [36,37]. However, other studies demonstrate that

LAA morphology does not have impact on TEs incidence [38,39]. These authors have identified higher LAA take-off and AF recurrence as the only predictors of periprocedural thromboembolic events.

LAA dimensions may also influence TE risk. Accordingly, some authors have observed that LAA volume (larger than 8.8ml according to Zheng *et al*., and >9.99 ml by Du *et al*.) increases the likelihood of AF recurrences after antral RF ablation [40,41]. Furthermore, Patel *et al*. and Demir *et al*. demonstrated that 30,4% of all patients that underwent CT scan before ablation procedure had atypical left atrial anatomy (diverticula or accessory appendages) [42,43] (Fig. 2), while the wall of the left atrium diverticula (LAD) was much thinner than that of adjacent LA (0.89±0.46 versus 2.39±0.83 mm). In addition, research has indicated that most LAD are located close to a PV or LAA ostium [44]. Detailed information regarding these morphological variations enables safe maneuvering of the catheters.

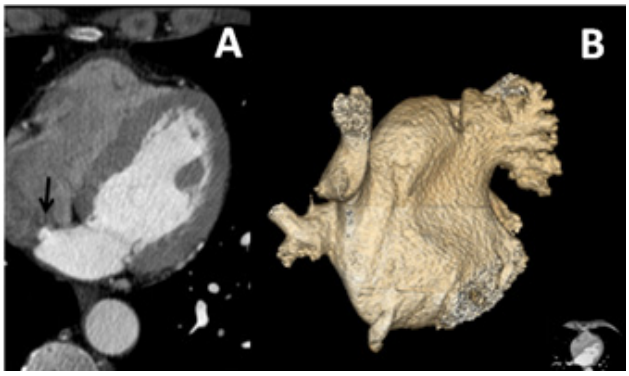

Figure 2. A – axial view, B – 3D volume rendering. Left atrial diverticulum on the border of the inferior wall and interatrial septum

PERICARDIAL FAT IMAGING

Recent reports suggest an important relationship between the presence and distribution of pericardial fat and the AF incidence, as well as the frequency of arrhythmia recurrence after ablation procedure. Herein, pericardial fat is associated with the prevalence of AF and symptom burden [45]. Furthermore, it has an influence on LA volume and directly affects the effectiveness of the ablation procedure in long-term follow-up [46,47].

INTERATRIAL SEPTUM

The access to the left atrium via transseptal puncture is a crucial part of AF ablation procedures, due to its possible life-threatening complications, including aortic or pericardial injury, with subsequent cardiac tamponade in the worst-case scenario. Pre-procedural CT imaging allows assessing the structure, thickness and possible anomalies of the interatrial septum (IAS), such as patent foramen ovale (PFO), congenital abnormalities, tumors or tumoral-like processes that develop on the IAS and atrial septal aneurysm (ASA) – defined by detecting a minimum 10-mm protrusion of the LA beyond the IAS into the right atrium (RA) (Fig. 3). Kosehan *et al*. observed that in 8.6% of all patients that had undergone cardiac CT scan, PFO was revealed, while 2.3% were diagnosed with atrial septal defect (ASD), and ASA accompanied ASD in three patients [48,49]. Of note, in some cases, the presence of PFO can facilitate the LA access.

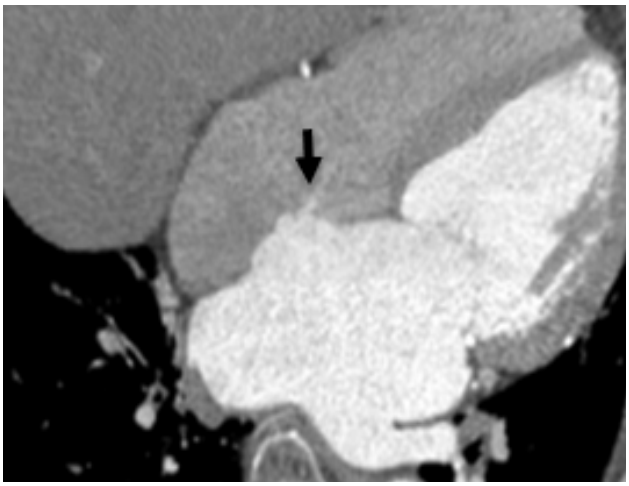

Figure 3. Oblique 2D reconstruction. The interatrial septal aneurysm with left to right atrium leak

Ziong *et al*. considers CT to be a practical and efficient alternative to transesophageal echocardiography for PFO diagnosis [50]. Indeed, pre-procedural CT scan allows to accurately plan this element of the procedure and to decide whether to apply intracardiac echocardiography (ICE) or TEE in cases of anticipated difficulties.

PULMONARY VEINS ANATOMY

In recent years, cryoballoon ablation (CBA) has become a widely-used approach in the invasive treatment of atrial fibrillation. In terms of safety and long-term effects, CBA is comparable with classical point-by-point radiofrequency (RF) ablation [51-57]. Moreover, the CBA procedure duration is significantly shorter, with lower number of repeated procedures and with less reconnected veins [58-65]. However, the AF ablation with cryoballoon technique is more dependent upon pulmonary veins anatomy. In addition, the long-term effectiveness of this technique depends on durable PVs isolation, which requires optimal cryoballoon catheter adhesion in the PV ostium. What is more, currently, one size of cryoballoon catheter (28mm) is in practical use, while the shape and dimensions of pulmonary veins are diverse.

According to Marom *et al.,* LA venous drainage is characterized by greater variability of the right-sided pulmonary veins, compared to the left side. In their work, they distinguished 6 patterns of right pulmonary veins and 2 types of left PVs outflow. They also observed a more frequent propensity to atrial arrhythmias in patients who had right middle pulmonary vein [66].

Literature data demonstrate that 70% of the population has 4 major pulmonary veins. Moreover, approximately 90% of all individuals have two pulmonary vein ostia on the right side, but in 6%, a larger number (3 to 5) is present, and a right-sided single ostium occurs in 3% of the general population. Observational studies confirm much lower variability of venous drainage pattern on the left side. Depending on the studied population, two ostia occur in 59-86% of all

people, and a common left pulmonary trunk was observed in 14-41% of all patients [67].

PULMONARY VEINS GEOMETRY

Pulmonary vein ovality index (OI) is an attractive, ingenuous parameter evaluated in several studies. It is defined as a ratio of the maximum (D_{max}) and minimum (D_{min}) diameter of the pulmonary vein ostium, and is most often calculated with the following formula: $OI = D_{max}/D_{min}$ [68] (Fig. 4.). The left-sided pulmonary veins (LSPVs) have higher ovality indice – they are more oval than right-sided pulmonary veins (RSPVs), and the left inferior PV (LIPV) is the most flattened vein [69,70].

Figure 4. Evaluation of the pulmonary vein ostium dimensions in CT – oblique short axis plane

Sorgente *et al*. state that the degree of occlusion during cryoballoon PVI is dependent on the ovality index only for LSPVs, and in patients with higher OI on the left side, more frequent AF recurrences were observed following CBA [71]. This relationship, however, was not demonstrated for right-sided pulmonary veins [72]. It seems obvious that the more circular ostium facilitates seamless catheter adhesion, and consequently creation of bidirectional electrical conduction block.

In the recently published study by Boussoussou *et al*., the authors revealed that RSPV diameter is associated with a higher rate of successful right-sided first-pass isolation [73]. Additionally, according to another recent paper, only the larger LA volume index and variant PVs anatomy are independently associated with increased risk of AF recurrence [74]. The PV ostium orientation in the frontal plane may also have effect on complete vein closure. As reported by Sorgente at al., less horizontal pulmonary veins orientation is related with a greater degree of occlusion [71].

The available studies, including our recently published paper, indicate that the presence of common left pulmonary trunk is not a contraindication to cryoballoon ablation [70,71]. In patients with this anatomical variant, similar long-term results were obtained to groups with normal branching [69]. In a similar vein, interested results were published by Ronsoni *et al*. – as indicated in their study, left common pulmonary vein was associated with lower rate of arrhythmia recurrence [75].

One of the possible mechanisms underlying AF ablation failure is the electrical conduction over the Marshall bundle and epicardial connections between the right-sided PV carina and right atrium (RA). According to Hanaki *et al*., a shorter interatrial distance for right-sided PVs and a smaller PV ostium for left-sided PVs are associated with AF recurrences. The authors postulated in this case that additional carina ablation may be necessary [76].

Pulmonary vein geometry is an important parameter, since CBA can be dependent on PVs anatomy. It is well known that the biggest challenge during PVI procedure is to achieve right inferior pulmonary vein isolation. This is due to the fact that the ostium of rigt inferior pulmonary vein (RIPV) is located not only close, but also posterior to the interatrial septum, and often causes difficulties in precise catheter maneuvering.

Kajiama *et al*. confirmed that shorter length of the pulmonary vein trunk from ostium to the bifurcation is associated with the need for multiple attempts to achieve adequate vessel occlusion. Interestingly, in the case of LSPV, longer PV ostium distance to the branching (>26.1 mm), thinner left lateral ridge (<4.7 mm) and higher ovality index (>50.5%) are factors predicting poor CBA outcome [72].

According to Baran *et al*., the area of pulmonary veins ostium also correlates with the long-term effect of cryoballoon ablation [77]. The bigger size may impede the vessel closure and additional catheter maneuvers or repeated cryoenergy applications may be needed. At the same time, it can increase the risk of both phrenic nerve palsy and pulmonary vein stenosis, resulting from cryoenergy delivery deep in the vein.

Another study, performed with a second-generation cryoballoon, demonstrated that the angle between the right inferior and right superior pulmonary vein is an important parameter related to CBA outcome. Optimal conditions for obtaining effective vein occlusion and isolation occur at angulation between 40,1° and 79,7° [78]. Another report demonstrates that ventral-caudal orientation of left superior pulmonary vein and ventral-caudal LIPV orientation are associated with AF recurrence [79].

CONCLUSIONS

Anatomical parameters of the left atrium assessed preprocedurally by MDCT are important for adequate patient qualification and safety of AF ablation procedure. Additionally, with detailed information regarding the LA anatomy, we can predict possible difficulties and precisely plan the procedure strategy. The morphology of the left atrium and pulmonary veins also allows anticipating the long-term ablation outcomes. Additionally, computed tomography is a useful tool for evaluation of possible PVI complications.

ORCID iDs

Milena Stachyra https://orcid.org/0000-0002-2606-4438
Andrzej Głowniak https://orcid.org/0000-0001-5398-4179
Elżbieta Czekajska-Chehab https://orcid.org/0000-0002-4053-7713

REFERNCES

1. Chugh SS, Havmoeller R, Narayanan K, Singh D, Rienstra M, Benjamin EJ, et al. Worldwide epidemiology of atrial fibrillation: a global burden of disease 2010 study. *Circulation*. 2014;129:837-47.
2. Malhi N, Hawkins NM, Andrage JG, Krahn AD, Deyell MW. Catheter ablation of atrial fibrillation in heart failure with reduced ejection fraction. *J Cardiovasc Electrophysiol*. 2018;29:1049-58.
3. Hindricks G, Potpara T, Dagres N, Arbelo E, Bax JJ, Blomström-Lundqvist C, et al. 2020 ESC Guidelines for the diagnosis and management of atrial fibrillation developed in collaboration with the European Association for Cardio-Thoracic Surgery (EACTS). *Eur Heart J*. 2021;42:373-498.
4. Kuck KH, Brugada J, Furnkranz A, Metzner A, Ouyang F, Chun KR, et al. Cryoballoon or radiofrequency ablation for paroxysmal atrial fibrillation. *N Engl J Med*. 2016;374:2235-45.
5. Su WW, Reddy VY, Bhasin K, Champagne J, Sangrigoli RM, Braegelmann KM, et al. Cryoballoon ablation of pulmonary veins for persistent atrial fibrillation: Results from the multicenter STOP Persistent AF trial. *Heart Rhythm*. 2020;17(11):1841-7.
6. Packer DL, Mark DB, Robb RA, Monahan KH, Bahnson TD, Poole JE, et al. CABANA Investigators. Effect of catheter ablation vs antiarrhythmic drug therapy on mortality, stroke, bleeding, and cardiac arrest among patients with atrial fibrillation: the CABANA randomized clinical trial. *JAMA*. 2019;21:1261-74.
7. Turagam MK, Garg J, Whang W, Sartori S, Koruth JS, Miller MA, et al. Catheter ablation of atrial fibrillation in patients with heart failure: a meta-analysis of randomized controlled trials. *Ann Intern Med*. 2019;170:41-50.
8. Kirchhof P, Camm AJ, Goette A, Brandes A, Eckardt L, Elvan A, et al. EAST-AFNET 4 Trial Investigators. Early rhythm-control therapy in patients with atrial fibrillation. *N Engl J Med*. 2020;383:1305-16.
9. Wazni OM, Dandamudi G, Sood N, Hoyt R, Tyler J, Durrani S, et al. STOP AF First Trial Investigators. Cryoballoon ablation as initial therapy for atrial fibrillation. *N Engl J Med*. 2021;384:316-24.
10. Andrade JG, Wells GA, Deyell MW, Bennett M, Essebag V, Champagne J, et al. Cryoablation or drug therapy for initial treatment of atrial fibrillation. *N Engl J Med*. 2021;384:305-15.
11. Di Biase L, Mohanty P, Mohanty S, Santangeli P, Trivedi C, Lakkireddy D, et al. Ablation Circulation versus amiodarone for treatment of persistent atrial fibrillation in patients with congestive heart failure and an implanted device: results from the AATAC multicenter randomized trial. *Circulation*. 2016;133:1637-44.
12. Prabhu S, Taylor AJ, Costello BT, Kaye DM, McLellan AJA, Voskoboinik A, et al. Catheter ablation versus medical rate control in atrial fibrillation and systolic dysfunction: the CAMERA-MRI study. *J Am Coll Cardiol*. 2017;70:1949-61.
13. Marrouche NF, Brachmann J, Andresen D, Siebels J, Boersma L, Jordaens L, et al. CASTLE-AF Investigators. Catheter ablation for atrial fibrillation with heart failure. N Engl J Med. 2018;378:417-27.
14. Kuniss M, Pavlovic N, Velagic V, Hermida JS, Healey S, Arena G, et al. Cryoballoon ablation *vs*. antiarrhythmic drugs: first-line therapy for patients with paroxysmal atrial fibrillation. *Europace*. 2021;23(7):1033-41.
15. Steinberg C, Champagne J, Deyell MW, Dubuc M, Leong-Sit P, Calkins H, et al. CIRCA-DOSE Study Investigators. Prevalence and outcome of early recurrence of atrial tachyarrhythmias in the cryoballoon vs irrigated radiofrequency catheter ablation (CIRCA-DOSE) study. *Heart Rhythm*. 2021;18(9):1463-70.
16. Hayashi T, Murakami M, Saito S, Iwasaki K. Characteristics of anatomical difficulty for cryoballoon ablation: insights from CT. *Open Heart*. 2022;9(1):e001724.
17. Thai WE, Wai B, Truong QA. Preprocedural imaging for patients with atrial fibrillation and heart failure. *Curr Cardiol Rep*. 2012; 14:584-92.
18. Angulo Hervias E, Guillén Subirán ME, Yagüe Romeo D, Castán Senar A, Seral Moral P, Núñez Motilva ME. Multidetector computed tomography in planning the treatment of atrial fibrillation. *Radiologia* (Engl Ed). 2020;62(2):148-59.
19. Sandhu A, Zipse MM, Borne RT, Aleong RG, Tompkins C, Schuller J, et al. Esophageal position, measured luminal temperatures, and risk of atrioesophageal fistula with atrial fibrillation ablation. *Pacing Clin Electrophysiol*. 2019;42(4):458-63.
20. Kapur S, Barbhaiya C, Deneke T, Michaud GF. Esophageal injury and atrioesophageal fistula caused by ablation for atrial fibrillation. *Circulation*. 2017;136(13):1247-55.
21. Lemola K, Sneider M, Desjardins B, Case I, Han J, Good E, at al. Computed tomographic analysis of the anatomy of the left atrium and the esophagus: implications for left atrial catheter ablation. *Circulation*. 2004;110(24):3655-60.
22. Tsao HM, Wu MH, Higa S, Lee KT, Tai CT, Hsu NW, at al. Anatomic relationship of the esophagus and left atrium: implication for catheter ablation of atrial fibrillation. *Chest*. 2005;128(4):2581-7.
23. Starek Z, Lehar F, Jez J, Scurek M, Wolf J, Kulik T, Zbankova A. Esophageal positions relative to the left atrium; data from 293 patients before catheter ablation of atrial fibrillation. *Indian Heart J*. 2018;70(1):37-44.
24. Narui R, Tokuda M, Matsushima M, Isogai R, Tokutake K, Yokoyama K, et al. Incidence and factors associated with the occurrence of pulmonary vein narrowing after cryoballoon ablation. *Circ Arrhythm Electrophysiol*. 2017;10(6):e004588.
25. Matsuda J, Miyazaki S, Nakamura H, Taniguchi H, Kajiyama T, Hachiya H, et al. Pulmonary vein stenosis after second-generation cryoballoon ablation. *J Cardiovasc Electrophysiol*. 2017;28(3):298-303.
26. Tokutake K, Tokuda M, Yamashita S, Sato H, Ikewaki H, Okajima E, et al. Anatomical and procedural factors of severe pulmonary vein stenosis after cryoballoon pulmonary vein ablation. *JACC Clin Electrophysiol*. 2019;5(11):1303-15.
27. Beinart R, Abbara S, Blum A, Ferencik M, Heist K, Ruskin J, et al. Left atrial wall thickness variability measured by CT scans in patients undergoing pulmonary vein isolation. *J Cardiovasc Electrophysiol*. 2011;22(11):1232-6.
28. Hof I, Chilukuri K, Arbab-Zadeh A, Scherr D, Dalal D, Nazarian S, et al. Does left atrial volume and pulmonary venous anatomy predict the outcome of catheter ablation of atrial fibrillation? *J Cardiovasc Electrophysiol*. 2009;20:1005-10.
29. Dorenkamp M, Sohns C, Vollmann D, Lüthje L, Seegers J, Wachter R, et al. Detection of left atrial thrombus during routine diagnostics work-up prior to pulmonary vein isolation for atrial fibrillation: Role of transesophageal echocardiography and multi-detector computed tomography. *Int J Cardiol*. 2013;163:26-33.
30. Mosleh W, Sheikh A, Said Z, Ahmed MA, Gadde S, Shah T, et al. The use of cardiac-CT alone to exclude left atrial thrombus before atrial fibrillation ablation: Efficiency, safety and cost analysis. *Pacing Clin Electrophysiol*. 2018;41(7):727-33.
31. Hong SJ, Kim JY, Kim JB, Sung JH, Wook Kim D, Uhm JS, et al. Multidetector computed tomography may be an adequate screening test to reduce periprocedural stroke in atrial fibrillation ablation: a multicenter propensity – matched analysis. *Heart Rhythm*. 2014;11(5): 763-70.
32. Bilchick KC, Mealor A, Gonzalez J, Norton P, Zhuo D, Mason P, et al. Effectiveness of integrating delayed computed tomography angiography imaging for left atrial appendage thrombus exclusion into the care of patients undergoing ablation of atrial fibrillation. *Heart Rhythm*. 2016;13(1):12-9.
33. Kottmaier M, Jilek C, Berglar S, Reents T, Bourier F, Semmler V, et al. Exclusion of left atrial thrombus by dual-source cardiac computed tomography prior to catheter ablation for atrial fibrillation. *Clin Res Cardiol*. 2019;108(2):150-6.
34. Zhai Z, Tang M, Zhang S, Fang P, Jia Y, Feng T, Wang J. Transoesophageal echocardiography prior to catheter ablation could be avoided in atrial fibrillation patients with a low risk of stroke and without filling defects in the late-phase MDCT scan: A retrospective analysis of 783 patients. *Eur Radiol*. 2018;28(5):1835-40.

35. Pathan F, Hecht H, Narula J, Marwick TH. Roles of transechophageal echocardiogaphy and cardiac computed tomography for evaluation of left atrial thrombus and associated pathology: A review and critical analysis. *JACC Cardiovasc Imaging*. 2018;11(4):616-27.
36. Khurram IM, Dewire J, Mager M, Maqbool F, Zimmerman SL, Zipunnikov V, et al. Relationship between left atrial appendage morphology and stroke in patients with atrial fibrillation. *Heart Rhythm*. 2013;10(12):1843-9.
37. Lee Y, Park HC, Lee Y, Kim SG. Comparison of morphologic features and flow velocity of the left atrial appendage among patients with atrial fibrillation alone, transient ischemic attack, and cardioembolic stroke. *Am J Cardiol*. 2017;119(10):1596-604.
38. Wu L, Liang E, Fan S, Zheng L, Du Z, Liu S, et al. Relation of left atrial appendage morphology determined by computed tomography to prior stroke or to increased risk of stroke in patients with atrial fibrillation. *Am J Cardiol*. 2019;123(8):1283-6.
39. Nedios S, Kornej J, Koutalas E, Bertagnolli L, Kosiuk J, Rolf S, et al. Left atrial appendage morphology and thromboembolic risk after catheter ablation for atrial fibrillation. *Heart Rhythm*. 2014;11(12):2239-46.
40. Zheng GA, Lin CY, Weng L, Chen JD. Left atrial appendage volume is a valuable predictor of atrial fibrillation recurrence after radiofrequency catheter ablation. *Zhonghua Xin Xue Guan Bing Za Zhi*. 2017;45(11):924-9.
41. Du W, Dai M, Wang M, Gong Q, Ye TQ, Wang H, Luo CD. Large left atrial appendage predicts the ablation outcome in hypertensive patients with atrial fibrillation. *J Electrocardiol*. 2020;63:139-44.
42. Patel SN, French A, Mathias H, Lyen S, Hamilton MC, Manghat NE. Presence of left atrial diverticula, accessory appendages, and normal variant pulmonary venous anatomy diagnosed using MDCT and adverse outcomes following radiofrequency catheter ablation therapy in patients with drug-refractory atrial fibrillation: an exploratory study. *Clin Radiol*. 2013;68(8):762-9.
43. Demir GG, Güneş HM, Seker M, Savur Ü, Güler GB, Güler E, et al. Is the presence of left atrial diverticulum associated with recurrence in patients undergoing catheter ablation for atrial fibrillation? *Arch Med Sci Atheroscler Dis*. 2019;11(4):25-31.
44. Peng LQ, Yu JQ, Yang ZG, Wu D, Xu JJ, Chu ZG, et al. Left atrial diverticula in patients referred for radiofrequency ablation of atrial fibrillation: assessment of prevalence and morphologic characteristics by dual-source computed tomography. *Circ Arrhythm Electrophysiol*. 2012;5(2):345-50.
45. Wong CX, Ganesan AN, Selvanayagam JB. Epicardial fat and atrial fibrillation: current evidence, potential mechanisms, clinical implications, and future directions. *Eur Heart J*. 2017;38(17): 1294-302.
46. Wong CX, Abed HS, Molaee P, Nelson AJ, Brooks AG, Sharma G, et al. Pericardial fat is associated with atrial fibrillation severity and ablation outcome. *J Am Coll Cardiol*. 2011;57(17):1745-51.
47. Kim TH, Park J, Park JK, Uhm JS, Joung B, Lee MH, Pak HN. Pericardial fat volume is associated with clinical recurrence after catheter ablation for persistent atrial fibrillation, but not paroxysmal atrial fibrillation: an analysis of over 600-patients. *Int J Cardiol*. 2014;176(3):841-6.
48. Kosehan D, Akin K, Koktener A, Cakir B, Aktas A, Teksam M. Interatrial shunt: diagnosis of patent foramen ovale and atrial septal defect with 64-row coronary computed tomography angiography. *Jpn J Radiol*. 2011;29(8):576-82.
49. Yasunaga D, Hamon M. MDCT of interatrial septum. *Diagn Interv Imaging*. 2015;96(9):891-9.
50. Xiong L, Zeng Y, Gan T, Yan F, Bai J, Shi Y, et al. Assessing patent foramen ovale on coronary computed tomographic angiography: a comparison with transesophageal echocardiography. *Jpn J Radiol*. 2022;40(7):689-95.
51. Kiedrowicz R. Fire or ice in the treatment of atrial fibrillation? What do the results of the fire or ice trial tell us? *WDR*. 2016;41(4):37-40.
52. Takamiya T, Nitta J, Inaba, Sato A, Inamura Y, Kato N, et al. Cryoballoon versus radiofrequency ablation for paroxysmal atrial fibrillation in hemodialysis patients. *Heart Vessels*. 2020;35(12): 1709-16.
53. Wang Y, Wang W, Yao J, Chen L, Yi S. Second-generation cryoballoon *vs*. contact-force sensing radiofrequency catheter ablation in atrial fibrillation: a meta-analysis of randomized controlled trials. *J Interv Card Electrophysiol*. 2021;60(1):9-19.
54. Buiatti A, von Olshausen G, Barthel P, Schneider S, Luik A, Kaess B, et al. Cryoballoon vs. radiofrequency ablation for paroxysmal atrial fibrillation: an updated meta-analysis of randomized and observational studies. *Europace*. 2017;19(3):378-84.
55. Matta M, Anselmino M, Ferraris F, Scaglione M, Gaita F. Cryoballoon vs. radiofrequency contact force ablation for paroxysmal atrial fibrillation: a propensity score analysis. *J Cardiovasc Med* (Hagerstown). 2018;19(4):141-47.
56. Murray MI, Arnold A, Younis M, Varghese S, Zeiher AM. Cryoballoon versus radiofrequency ablation for paroxysmal atrial fibrillation: a meta-analysis of randomized controlled trials. *Clin Res Cardiol*. 2018;107(8):658-69.
57. Inaba O, Metzner A, Rottner L, Mathew S, Lemes C, Maurer T, et al. Radiofrequency or cryoballoon ablation for index pulmonary vein isolation: What is the impact on long-term clinical outcomes after repeat ablation? *J Cardiovasc Electrophysiol*. 2020;31(5):1068-74.
58. Glowniak A, Tarkowski A, Fic P, Wojewoda K, Wojcik J, Wysokinski A. Second-generation cryoballoon ablation for recurrent atrial fibrillation after an index procedure with radiofrequency versus cryo: different pulmonary vein reconnection patterns but similar long-term outcome – results of a multicenter analysis. *J Cardiovasc Electrophysiol*. 2019;30:1005-12.
59. Ali AN, Riad O, Tawfik M, Opel A, Wong T. Newer generation cryoballoon vs. contact force-sensing radiofrequency ablation catheter in the ablation of paroxysmal atrial fibrillation. *Herzschrittmacherther Elektrophysiol*. 2021;32(2):236-43.
60. Wieczorek M, Sassani K, Hoeltgen R. Comparison of pulmonary vein reconnection patterns after multielectrode phased radiofrequency- and cryoballoon ablation of atrial fibrillation. *BMC Cardiovasc Disord*. 2020;20(1):197.
61. Gunawardene MA, Hoffmann BA, Schaeffer B, Chung DU, Moser J, Akbulak RO, et al. Influence of energy source on early atrial fibrillation recurrences: a comparison of cryoballoon vs. radiofrequency current energy ablation with the endpoint of unexcitability in pulmonary vein isolation. *Europace*. 2018;20(1):43-9.
62. Buist TJ, Adiyaman A, Smit JJ, Ramdat Misier AR, Elvan A. Arrhythmia-free survival and pulmonary vein reconnection patterns after second-generation cryoballoon and contact-force radiofrequency pulmonary vein isolation. *Clin Res Cardiol*. 2018;107(6):498-506.
63. Chen CF, Zhong YG, Jin CL, Gao XF, Liu XH, Xu YZ. Comparing between second-generation cryoballoon vs open-irrigated radiofrequency ablation in elderly patients: Acute and long-term outcomes. *Clin Cardiol*. 2020;43(5):500-7.
64. Mörtsell D, Arbelo E, Dagres N, Brugada J, Laroche C, Trines SA, et al. ESC-EHRA Atrial Fibrillation Ablation Long-Term Registry investigators. Cryoballoon vs. radiofrequency ablation for atrial fibrillation: a study of outcome and safety based on the ESC-EHRA atrial fibrillation ablation long-term registry and the Swedish catheter ablation registry. *Europace*. 2019;21(4):581-9.
65. Sørensen SK, Johannessen A, Worck R, Hansen ML, Hansen J. Radiofrequency versus cryoballoon catheter ablation for paroxysmal atrial fibrillation: durability of pulmonary vein isolation and effect on atrial fibrillation burden: The RACE-AF randomized controlled trial. *Circ Arrhythm Electrophysiol*. 2021;14(5):e009573.
66. Marom EM, Herndon JE, Kim YH, McAdams HP. Variations in pulmonary venous drainage to the left atrium: Implications for radiofrequency ablation. *Radiology*. 2004;230(3):824-9.
67. Wannasopha Y, Oilmungmool N, Euathrongchit J. Anatomical variations of pulmonary venous drainage in Thai people: multidetector CT study. *Biomed Imaging Interv J*. 2012;8(1):e4.
68. Mulder BA, Al-Jazairi MIH, Arends BKO, Bax N, Dijkshoorn LA, Sheikh U, et al. Pulmonary vein anatomy addressed by computed tomography and relation in paroxysmal atrial fibrillation. *Clin Cardiol*. 2019;42 (4):438-43.
69. Schmidt M, Dorwarth U, Straube F, Daccarett M, Rieber J, Wankerl M, et al. Cryoballoon in AF ablation: Impact of PV ovality on AF recurrence. *Int J Cardiol*. 2013;167(1):114-20.

70. Stachyra M, Szczasny M, Tarkowski A, Mianowana M, Wojewoda K, Wysokinska K, et al. Impact of pulmonary vein ovality index on cooling kinetics and acute success of atrial fibrillation ablation with the third-generation cryoballoon cathether. *Adv Interv Cardiol*. 2021;17(4):403-9.
71. Sorgente A, Chierchia GB, Asmundis C, Sarkozy A, Namdar M, Capulzini L, et al. Pulmonary vein ostium shape and orientation as possible predictors of occlusion in patients with drug-refractory paroxysmal atrial fibrillation undergoing cryoballon ablation. *Europace*. 2011;13:205-12.
72. Kajiyma T, Miyazaki S, Matsuda J, Watanabe T, Niida T, Takagi T, et al. Anatomic parameters predicting procedural difficulty and balloon temperature predicting successful applications in individual pulmonary veins during 28mm second-generation cryoballoon ablation. *Jacc Clin Electrophysiol*. 2017;3(6):580-8.
73. Boussoussou M, Szilveszter B, Vattay B, Kolossváry M, Vecsey-Nagy M, Salló Z, et. al. The effect of left atrial wall thickness and pulmonary vein sizes on the acute procedural success of atrial fibrillation ablation. *Int J Cardiovasc Imaging*. 2022;38:1601-11.
74. Istratoaie S, Roșu R, Cismaru G, Vesa ȘC, Puiu M, Zdrenghea D, et.al. The impact of pulmonary vein anatomy on the outcomes of catheter ablation for atrial fibrillation. *Medicina* (Kaunas). 2019;55(11):727.
75. Ronsoni RM, Silvestrini TL, Essebag V, Lopes RD, Lumertz Saffi MA, Luz Leiria TL. Association of the left common ostium with clinical outcome after pulmonary vein isolation in atrial fibrillation. *Indian Pacing Electrophysiol J*. 2021;21(2):95-100.
76. Hanaki Y, Yoshida K, Baba M, Hasebe H, Takeyasu N, Nogami A, Ieda M. Interatrial distance predicts the necessity of additional carina ablation to isolate the right-sided pulmonary veins. *Heart Rhythm*. 2020;1(4):259-67.
77. Baran J, Piotrowski R, Sikorska A, Kowalik I, Krynski T, Stec S, et al. Impact of pulmonary vein ostia anatomy on efficacy of cryoballoon ablation for atrial fibrillation. *Heart Beat J*. 2016;1:65-70.
78. Matsumoto Y, Muraoka Y, Funama Y, Mito S, Masuda T, Sato T, et al. Analysis of anatomical features of pulmonary veins on preprocedural cardiac CT images resulting in incomplete cryoballoon ablation for atrial fibrillation. *J Cardiovasc Comput Tomogr*. 2019;13(2):118-27.
79. Kocyigit D, Yalcin MU, Gurses KM, Selin A, Turk G, Canpolat U, et al. Pulmonary vein orientation is independently associated with outcomes following cryoballoon-based atrial fibrillation ablation. *J Cardiovasc Comput Tomogr*. 2018;12(4):281-5.