sciendo

DOI: 10.2478/aoj-2008-0023

Treatment of severe bimaxillary protrusion with miniscrew anchorage: treatment and complications

Hiroshi Mimura

Specialist practice, Tokyo, Japan

Background: Problems involving excessive face height and severe bimaxillary protrusion are usually treated with orthognathic surgery. When this form of treatment is rejected, retraction and intrusion of the anterior teeth using skeletal anchorage afforded by miniscrews may be employed.
Aims: To describe the treatment of severe bimaxillary protrusion with the aid of miniscrews and to discuss the complications encountered during treatment.
Methods: Following extraction of the four first premolars, miniscrews were placed bilaterally in both jaws to permit maximum retraction of the anterior teeth, and intrusion of the posterior and upper anterior teeth.
Results: The upper incisors were retracted 12 mm and intruded 5 mm over 20 months. The mandible rotated forward and upward, the face height reduced and the facial aesthetics improved. During treatment an irregular ridge of bone developed labial to the upper incisors, bone was deposited in the incisive fossae and the apices of the upper incisors were resorbed. An alveoloplasty was carried out to recontour the labial bone and the incisive fossae.
Conclusions: Absolute anchorage provided by miniscrews may become an effective alternative to orthognathic surgery for treatment of severe bimaxillary protrusion. During extensive retraction, the teeth may contact structures not normally encountered during conventional orthodontic treatment.
(Aust Orthod J 2008; 24: 156–163)

Received for publication: April 2008
Accepted: July 2008

Introduction

Endosseous implants can provide skeletal anchorage which greatly reduces the need for patient cooperation.[1–15] Initially, dental implants[1–5] and miniplates[6,8,10] were used, but because of their greater size they require more extensive surgery to insert and remove and so have fewer applications than miniscrews. Screw implants were initially used to provide absolute anchorage for anterior-posterior tooth movement,[8,9] but it is now acknowledged that miniscrews are very effective in facilitating intrusion of both anterior and posterior teeth.[10–13]

This report describes the treatment of an adult patient with a bimaxillary protrusion, increased anterior face height and gummy smile. The patient required considerable retraction of the anterior teeth to reduce the facial progathism, intrusion of the upper anterior teeth to reduce the gummy smile and intrusion of the posterior teeth to autorotate the mandible and improve the vertical jaw relationship. Complications encountered during treatment are discussed.

Case report

A 36 year-old woman presented for treatment complaining of rotated upper central incisors. At 11 years of age she had been treated with fixed appliances and Kloehn-type cervical traction, but no extractions. She had a convex profile, bimaxillary protrusion, a long face with a receding chin and a gummy smile (Figure 1). She had an Angle Class I malocclusion with crowding of the upper and lower incisors (Figure 2).

© Australian Society of Orthodontists Inc. 2008



Figure 1. (a) Pretreatment profile. (b) Pretreatment full face, smiling.



Figure 2. Pretreatment intra-oral photographs.

All teeth except the third molars were present. The cephalometric analysis showed that she was skeletal 2 with a high mandibular plane angle. The upper incisors were upright with the roots positioned close to the labial cortical plate of the maxilla, while the lower incisors were proclined with the roots lying close to or in the lingual cortical plate of the mandible (Figure 3). The positions of these teeth may have been due to the earlier treatment. There was no evidence of root resorption and the upper and lower gingivae and mucosa were of normal appearance.

Treatment objectives

The treatment of choice was to correct the skeletal discrepancies, the gummy smile and the bimaxillary protrusion with a combination of orthognathic surgery and orthodontic treatment. The patient, however, fearful of surgery and the associated risks, rejected it. The alternative proposal was to extract the four first premolars and, using miniscrews, retract the anterior teeth without loss of anchorage. Intrusion of the posterior teeth would allow upward rotation of the mandible and a more prominent chin, while intrusion of the upper incisors would reduce the gummy smile.

Treatment

Following the premolar extractions, a 0.018 inch pre-adjusted edgewise appliance and transpalatal arch were fitted and 0.014 inch NiTi archwires used to level and align the arches. One month later 0.016 inch NiTi archwires were placed and after a further month 0.016 x 0.022 inch NiTi archwires were

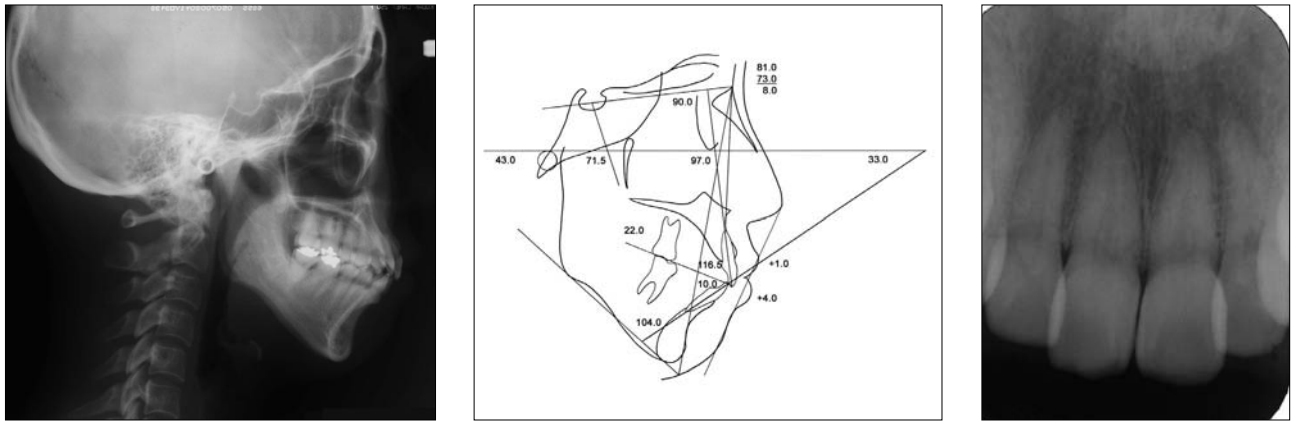

Figure 3. (a) Pretreatment lateral cephalometric radiograph. (b) Pretreatment tracing. (c) Pretreatment periapical radiograph of the upper incisors.

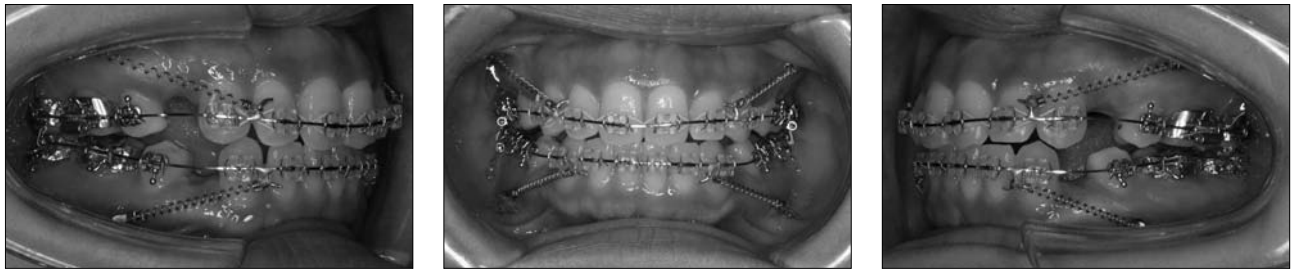

Figure 4. Intra-oral photographs, three months from the start of active treatment. Note the absence of any bony labial ridge.

inserted. At this time ISA miniscrews (Biodent, Tokyo, Japan) were also implanted bilaterally high in the buccal sulci beneath the zygomatic buttresses, and as low as possible in the mandibular buccal sulci. The screws were placed so that the force vectors from them would result in retraction and intrusion of the anterior teeth. Initially, elastometric chain provided the retraction force between the abutments and the canines, but a month later closed coil NiTi springs (Sentalloy, GAC, Tokyo, Japan) delivering 150 grams of force were used to retract the upper and lower anterior teeth (Figure 4). One month later the lower miniscrews loosened and fell out, and were replaced with Dual-Top miniscrews (Jeil Medical, Seoul, Korea).

After 10 months of treatment, the force from the NiTi spring was raised to 200 grams per side and at 13 months elastomeric chain was stretched vertically from the lower implants to the lower archwire on each side to intrude lower molars and increase the upward rotation of the mandible. The upper molars were not intruded because of the steep occlusal plane angle, but the upper incisors were intruded to correct the cant of the occlusal plane and compensate for the forward movement of the mandible as it rotated upward. At 16 months into treatment palatal movement of the anterior teeth ceased, so the retraction force was increased by using a heavy elastic module from each implant to soldered hooks on the upper archwire, and elastomeric chain from the upper canines to the upper molars. At this stage of treatment an irregular ridge labial to the upper incisors had become very prominent (Figure 5). It was covered by healthy mucosa. The cephalometric radiograph taken at this time revealed that the upper incisors had been retracted 11 mm and intruded 4 mm, leaving behind a thick labial cortical plate and shallow incisive fossae. A point was difficult to locate and appeared to have moved forward (Figure 6). The lower labial cortical plate also appeared thicker than normal. The soft tissue profile was much improved, although the upper lip was still slightly protrusive,



Figure 5. Intra-oral photographs, 16 months from the start of treatment. Note the prominent ridge of labial bone.

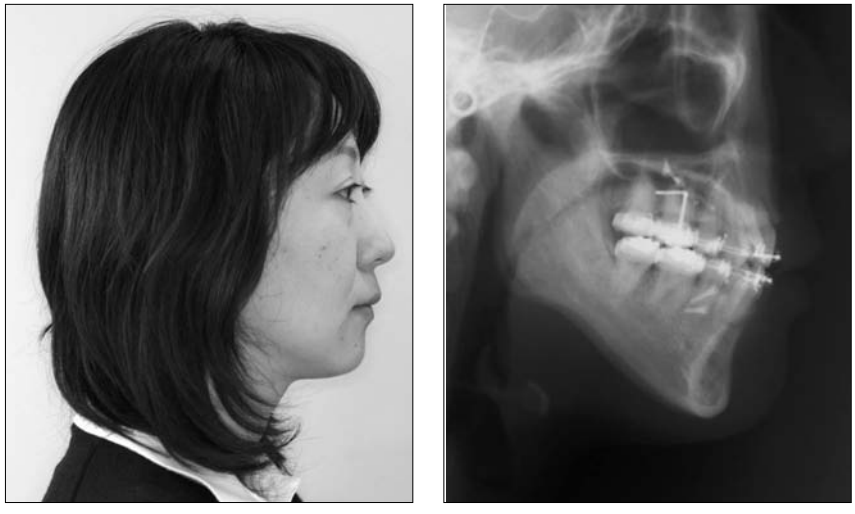

Figure 6. (a) Presurgical profile photograph, approximately 17 months from the start of treatment. (b) Presurgical lateral cephalometric radiograph.

possibly because of bone deposited in the incisive fossae and the prominent ridge of labial bone (Figure 6).

After consultation with the patient and an oral surgeon, an alveoloplasty was performed to remove the irregular cortical bone overlying the roots of the upper anterior teeth, and the new bone deposited in the incisive fossae. The miniscrews were also removed. The roots of the upper anterior teeth were not exposed during this procedure (Figure 7). Following the surgery, the bone followed a smooth continuous curve from the alveolar crest to the anterior nasal spine and the upper lip appeared less protrusive. A further month of treatment followed with short vertical elastics to improve the interdigitation, and the appliances were then removed and retainers fitted.

Results

The active treatment time was 1 year and 8 months and in that time only two round and two rectangular wires were used in each arch. There were marked improvements in the facial aesthetics and smile. The pretreatment gummy smile had been eliminated, the lower face height reduced and both lips were positioned behind the E-line (Figure 8). The teeth were aligned and an ideal occlusion was obtained (Figure 9). The cephalometric analysis confirmed that FMA had decreased and that the mandible had rotated upwards (Figure 10). The improvement in the ANB angle was achieved by a combination of an increase in the SNB angle as the mandible rotated upwards and a reduction in the SNA angle. The alveoloplasty may have contributed to this. The upper central incisors were retracted 12 mm and intruded 5 mm (Figure

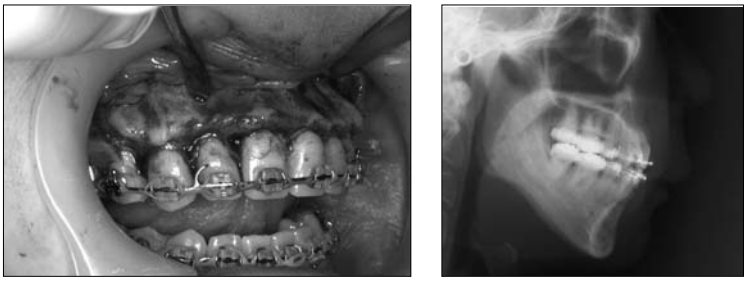

Figure 7. (a) Surgical intra-oral photograph showing the prominent ridge of labial bone. (b) Lateral cephalometric radiograph showing the re-contoured ridge and incisive fossae.



Figure 8. (a) Post-treatment profile. (b) Post-treatment full face, smiling.



Figure 9. Post-treatment intra-oral photographs.

10). The roots of the upper incisors showed resorption, especially the mesial surfaces of the central incisors. An Ortho-CT image (3DX multi-image micro CT, J Morita, Manufacturing Company, Osaka, Japan) showed that the apices of the central incisors were in close proximity to the ring of cortical bone forming the incisive canal (Figure 11).

Discussion

The usual treatment for patients with a long face and a downward and backward rotation of the mandible is a surgical repositioning the maxilla and mandible to a more normal relationship.[14,15] Previous reports have described the correction of cases using implants to intrude the buccal segments and allow the

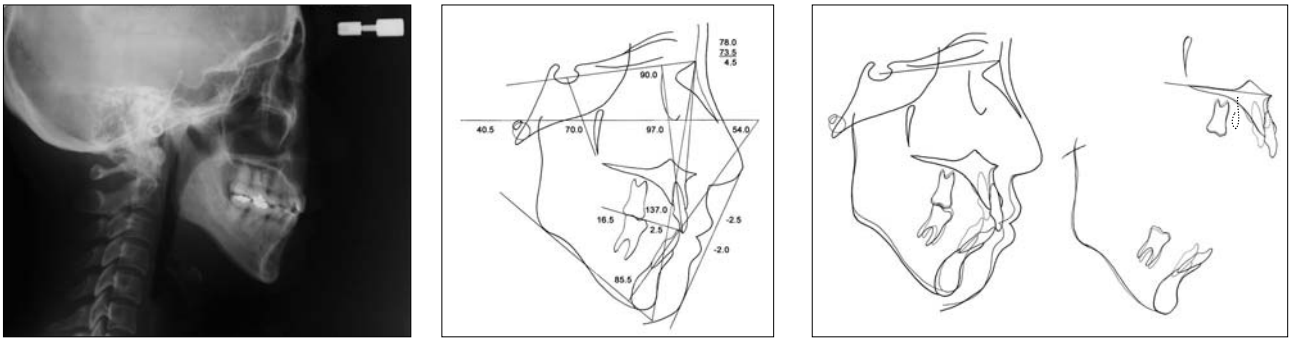

Figure 10. (a) Post-treatment lateral cephalometric radiograph. (b) Post-treatment tracing. (c) Superimposed tracings showing the autorotation and change in soft tissue profile, and superimposed tracings before (dark line) and after treatment (light line) and before surgery (dotted line).

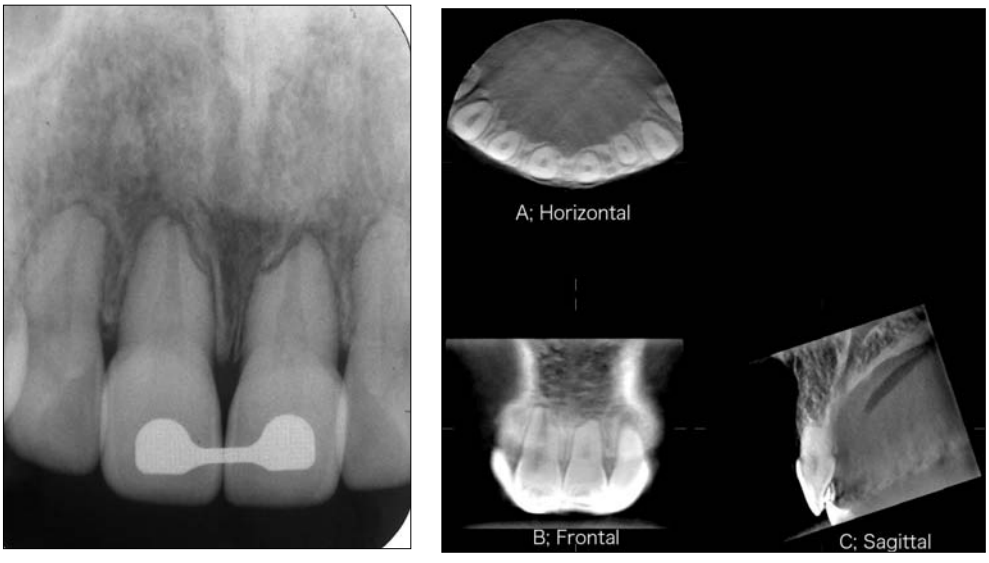

Figure 11. (a) Post-treatment periapical radiograph. (b) Ortho CT view: A, the incisive canal appears as a round translucent zone between upper central incisors; B, apical resorption of both central incisors; C, the upper incisors appear to be positioned on the palatal cortical plate close to the incisive canal. The planes in the above images cut through the area with the greatest resorption on mesial root surface of the upper left central incisor.

mandible to rotate upward and forward, thus reducing the anterior face height.[6,7,10,11,13] This was achieved in this case and, in addition, the implants were used to retract the upper and lower incisors and intrude the upper incisors, eliminating the gummy smile in the process.

These changes occurred over 20 months, but it seems that the maxillary alveolar process failed to remodel as the upper anterior teeth were intruded and retracted, leaving behind a prominent labial ridge of bone. This did not happen in the mandible despite similar rapid movement. Unusual bony changes in the maxillary alveolar process during orthodontic treatment have been reported by others.[18] Inaba et al. reported an unusual bony change when the upper lateral incisors were approximated after the central incisors were lost 10 years previously.[18] In this case the lateral incisors were moved 6 mm mesially and 7 mm palatally over 12 months and a 'bone hernia' developed labially between the two incisors. The bony outgrowth, or 'hernia', and the accompanying palatal concavity suggest that a fold may have developed in the periosteum as the incisors were approximated. It appears that tissue remodelling failed to keep pace with the tooth movement.

The additional bone deposited in the incisive fossae may be explained by periosteal tension as the upper anterior teeth were retracted.[19–21] In the present case, it could be postulated that the periosteum was tensed and drawn away from the fossae as the anterior teeth

were retracted and intruded and new bone was deposited in the fossae. Initially, retraction of the anterior teeth did not produce the expected improvement in facial appearance because of the ridge of crestal bone and bone deposited in the incisive fossae. Alveoloplasty, however, improved the profile and smile (Figures 6 and 8).

Root resorption is one of the major complications of orthodontic tooth movement. The upper incisors are particularly prone to root resorption, which occurs to some extent in almost every patient.[22–24] In this case, all the upper incisors, but especially the central incisors, underwent significant root resorption. The length of treatment does not appear to have been a significant factor because the duration of treatment was 20 months, which can be considered optimum. However, the amount of root movement may have been especially significant.[26–28] The apices were moved palatally more than 10 mm and, in the case of the central incisors, the mesial surfaces probably contacted the cortical bone forming the incisive canal. Kaley and Phillips[29] reported a 20 times increase in the risk of severe root resorption of the upper incisors if their roots were forced against the lingual cortical plate during treatment. The Ortho-CT image of the present case indicates that similar resorption can occur when the apices of the incisors contact the incisive canal. This is unlikely to happen during conventional orthodontic treatment, but when absolute anchorage is used the tooth roots can be moved much greater distances and contact structures they would not normally contact.

Continuous heavy forces also increase the risk of root resorption.[30] The accepted wisdom is that light continuous forces should be used to move teeth within the physiologic tolerances of the tissues. In the present case, the anterior teeth were retracted with NiTi springs, delivering 200 grams per side: a total force of 400 grams or 66.7 grams per tooth (six anterior teeth). This was considered to be a light force, so when tooth movement stopped, presumably because the roots contacted the cortical bone forming the incisive canal, the force was increased to over 500 grams by changing to heavy elastomeric modules.

Conclusions

Miniscrews, which provide absolute anchorage, enable the incisors to be retracted and intruded much greater distances than with conventional treatment, and whole arches can be intruded with a degree of predictability.

A note of caution must be sounded when absolute anchorage is used as the teeth may contact structures not normally encountered during conventional orthodontic treatment, and increase the risk of root resorption.

Extensive and rapid movement of the upper anterior teeth in adults may be associated with unexpected bony changes, which may require surgery to correct.

Corresponding author

Dr Hiroshi Mimura
2-15-11-6, Yato-cho
Nishi-Tokyo
Tokyo, 188-0001
Japan
Phone: +81 424 24 3987
Fax: +81 424 24 3983
Email: mimura@m-ortho.com

References

1. Creekmore TD, Eklund MK. The possibility of skeletal anchorage. J Clin Orthod 1983;17:266–9.
2. Turley PK, Kean C, Schur J, Stefanac J, Gray J, Hennes J, Poon LC. Orthodontic force application to titanium endosseous implants. Angle Orthod 1988;58:151–62.
3. Ödman J, Lekholm U, Jemt T, Brånemark P-I, Thilander B. Osseointegrated titanium implants: a new approach in orthodontic treatment. Eur J Orthod 1988;10:98–105.
4. Prosterman B, Prosterman L, Fisher R, Gornitsky M. The use of implants for orthodontic correction of an open bite. Am J Orthod Dentofacial Orthop 1995;107:245–50.
5. Roberts WE, Helm FR, Marshall KJ, Gongloff RK. Rigid endosseous implants for orthodontic and orthopedic anchorage. Angle Orthod 1989;59:247–56.
6. Umemori M, Sugawara J, Mitani H, Nagasaka H, Kawamura H. Skeletal anchorage system for open-bite correction. Am J Orthod Dentofacial Orthop 1999;115:166–74.
7. Sugawara J, Baik UB, Umemori M, Takahashi I, Nagasaka H, Kawamura H, Mitani H. Treatment and post-treatment dentoalveolar changes following intrusion of mandibular molars with application of a skeletal anchorage system (SAS) for open bite correction. Int J Adult Orthodon Orthognath Surg 2002;17:243–53.
8. Kanomi R. Mini-implant for orthodontic anchorage. J Clin Orthod 1997;31: 763–67.
9. Park H, Bae S, Kyung H, Sung J. Microimplant anchorage for treatment of skeletal class I bialveolar protrusion. J Clin Orthod 2001;35:417–22.
10. Yao CC, Wu CB, Wu HY, Kok SH, Chang HF, Chen YJ. Intrusion of the overerupted upper left first and second molars by mini-implants with partial-fixed orthodontic appliances: a case report. Angle Orthod 2004;74:550–.7
11. Kuroda S, Katayama A, Takano-Yamamoto T. Severe anterior open-bite case treated using titanium screw anchorage. Angle Orthod 2004;74:558–67.

12. Kuroda S, Sugawara Y, Deguchi T, Kyung HM, Takano-Yamamoto T. Clinical use of miniscrew implant as orthodontic anchorage: success rates and postoperative discomfort. Am J Orthod Dentofacial Orthop 2007;131:9–15.
13. Kuroda S, Sugawara Y, Takamura N, Takano-Yamamoto T. Anterior open bite with temporomandibular disorder treated with titanium screw anchorage: evaluation of morphological and functional improvement. Am J Orthod Dentofacial Orthop 2007;131:550–60.
14. Bell WH, Creekmore TD, Alexander RG. Surgical correction of the long face syndrome. Am J Orthod 1977;71:40–67.
15. Epker BN, Fish LC. Surgical-orthodontic correction of open-bite deformity. Am J Orthod 1977;71:278–99.
16. Goldberg D, Turley PK. Orthodontic space closure of the edentulous maxillary first molar area in adults. Int J Adult Orthodon Orthognath Surg 1989;4:255–66.
17. Melsen B, Agerbaek N, Markenstram G. Intrusion of incisors in adult patients with marginal bone loss. Am J Orthod Dentofacial Orthop 1989;96:232–41.
18. Inaba K, Fukawa T, Yamazaki Y. Occurrence of bone hernia during closure of an incisal space in an adult. Orthodontic Waves 2007;66:15–20.
19. Harkness EM, Trotter WD. Growth of transplants of rat humerus following circumferential division of the periosteum. J Anat 1978;126:275–89.
20. Dorfl J. Migration of tendinous insertions. II. Experimental modifications. J Anat 1980;131:229–37.
21. Meikle MC. Remodelling the dentofacial skeleton: the biologic basis of orthodontics and dentofacial orthopedics. J Dent Res 2007;86:12–24.
22. DeShields RW. A study of root resorption in treated Class II division 1 malocclusions. Angle Orthod 1969;39:231–45.
23. Kennedy DB, Joondeph DR, Osterburg SK, Little RM. The effect of extraction and orthodontic treatment on dentoalveolar support. Am J Orthod 1984;84:183–90.
24. Newman WG. Possible etiological factors in external root resorption. Am J Orthod 1975;67:522–39.
25. Brezniak N, Wasserstein A. Root resorption after orthodontic treatment: Part 1. Literature review. Am J Orthod Dentofacial Orthop 1993;103:62–6.
26. Sameshina GT, Sinclair PM. Predicting and preventing root resorption: Part I. Diagnostic factors. Am J Orthod Dentofacial Orthop 2001;119:505–10.
27. Sameshina GT, Sinclair PM. Predicting and preventing root resorption: Part II. Treatment factors. Am J Orthod Dentofacial Orthop 2001;119:511–15.
28. Mirabella AD, Artun J. Risk factors for apical root resorption of maxillary anterior teeth in adult orthodontic patients. Am J Orthod Dentofacial Orthop 1995;108: 48–55.
29. Kaley J, Phillips C. Factors related to root resorption in edgewise practice. Angle Orthod 1991;61:125–31.
30. Brudvik P, Rygh P. Transition and determinants of orthodontic root resorption-repair sequence. Eur J Orthod 1995; 17:177–188.