© 1987 Australian Orthodontic Journal, Melbourne, Australia

sciendo DOI: 10.2478/aoj-1987-0013



A re-assessment of serial extraction

Stanley G. Jacobs B.D.Sc.(Melb),F.D.S.R.C.S.(Eng),D.Orth.R.C.S.(Eng),F.R.A.C.D.S.
Melbourne, Australia

Abstract: Serial extraction procedures have been of interest to dentists for many years. This article defines the procedures, explains the rationale, indicates signs of developing disharmony, describes the criteria for suitable cases and explores mixed dentition analysis. It mentions some of the developmental and growth changes that are pertinent, details the extraction sequences, warns of precautions to be observed, outlines some advantages and disadvantages of the procedure and reviews and discusses some of the literature. It concludes that the procedure can no longer be recommended especially if it is not possible to complete the management with competent fixed appliance treatment.

Reference: Aust.Orthod.J. 10(2): 90-97 (1987)

MeSH words: Serial extraction
Key words: Serial extraction; mixed dentition analysis; eruption sequence

Definition

Serial extraction can be defined as the correctly timed, planned removal of certain deciduous and permanent teeth in mixed dentition cases with dento-alveolar disproportion, i.e. teeth to supporting bone size imbalance, in order to:
(a) alleviate crowding of incisor teeth;
(b) allow unerupted teeth to guide themselves into improved positions (canines in particular);
(c) lessen (or eliminate) the period of active appliance therapy.

RATIONALE

The rationale of the method assumes that it is possible to predict at an early age that there will be a lack of space in the future permanent dentition to accommodate all of the permanent teeth in even alignment.

Signs of developing disharmony between tooth and supporting bone size

One may see:
(a) in either arch (but much more commonly in the mandible) that erupting lateral incisors have caused premature exfoliation of one or both deciduous canines. The incisors usually assume fair alignment usurping space intended for the canines. Unilateral loss of a deciduous mandibular canine usually results in a shift of the mandibular centre-line to that side;
(b) in the mandible erupting lateral incisors partially blocked out to the lingual. They maintain their position until the deciduous canines are exfoliated or they may attempt to rotate into the lateral incisor space;
(c) in the maxilla that the position of the lateral incisors is affected:
(i) the unerupted maxillary lateral incisors are usually found lingual to the erupted central incisors. If the deciduous canine maintains its position, which it usually does i.e. it is not often exfoliated, the erupting maxillary lateral incisor will be held to the lingual and will lock behind the mandibular incisors. Active treatment i.e. an appliance, to correct its position will then be needed. Following the lingual locking of the lateral incisor the permanent maxillary canine can migrate mesially resulting in the need for retraction by an appliance;
(ii) occasionally the maxillary lateral incisor erupts to the labial e.g. in a class II division 2 malocclusion or it may attempt to rotate into the maxillary lateral incisor space in a manner similar to the mandibular lateral incisor rotation;
(d) a noticeable lack of alveolar bone on the labial side of one mandibular central incisor, i.e. the crown of the mandibular central incisor is longer because it is more labial;
(e) various combinations of the above either unilaterally or bilaterally;
(f) gum flaps over deciduous second molars or permanent first molars;
(g) impacted permanent first molars;
(h) stacking of permanent maxillary molars (a staircase effect), i.e. the molars are distally inclined on a panoramic radiograph.
Dale (1985) has described and illustrated these signs comprehensively.

Criteria for a suitable case

The type of case most favourable for serial extraction is a Class 1 malocclusion showing a severe disharmony between tooth size and jaw size. The severity of the crowding should be such that an analysis of the mixed dentition would indicate a discrepancy of at least eight to ten mm excess tooth material in the unmutilated mandibular arch. Another way of phrasing these criteria would be to state that serial extraction should only be undertaken in cases that will not need further treatment i.e. it should not be done if there is an overjet or reverse overjet, increased overbite or open bite, rotation, gross malposition, crossbite etc.

Mixed dentition analysis

The clinician must determine both the available arch length and the space required. Available space is measured on plaster casts using a Boley gauge or fine dividers and soft brass wire as has been described by Tweed (1966), Graber (1972) and Dale (1985).

The required space is a combination of:
(a) the maximum diameter of well aligned teeth (both erupted and unerupted) plus, according to some authorities e.g. Tweed (1966),
(b) the cephalometric correction necessary.
The size of the unerupted teeth can be determined either by:
(a) measuring the size of the unerupted teeth directly from accurate periapical radiographs or
(b) employing Moyers mixed dentition analysis (Moyers 1973). This entails measuring the size of the four mandibular incisors and then using a chart which provides probabilities of the widths of the maxillary and mandibular canines and first and second premolars. It has been suggested that the seventy-five percent level of probability be used. Perhaps the four mandibular incisors are used to provide probabilities of the maxillary canine and premolar sizes because:
(i) maxillary lateral incisors are often diminutive or even absent and
(ii) maxillary lateral incisors may not have erupted yet when consideration is given whether to commence serial extraction.

Changes in arch width and length

The question to be answered in the mixed dentition when the incisors are erupting is how much more space will be created to relieve any existing crowding?
Space is created by:
(a) a favourable variation in the size ratio between the deciduous and permanent posterior teeth;
(b) intercanine width growth;
(c) a more favourable inclination of permanent incisors.

(a) *Tooth size relationships*

The variation in size between deciduous posteriors is such that on average the deciduous canine and first and second molars are larger than the permanent canine and first and second premolars by 1·7mm in each lower quadrant and by 0·9mm in each upper quadrant. Nance (1947) termed this difference the leeway.

The mandibular leeway space is more apparent than real because of the terminal plane relationship seen in most mixed dentitions. Usually there is an end to end cuspal contact of permanent first molars. With exchange of teeth the available leeway space enables the mandibular molars to come forward to create the correct interdigitation. Since half the mandibular leeway space is lost in the process there is seldom more than one mm of arch length in each buccal segment to assist in arch alignment - insignificant to help moderately severe crowding, i.e. eight to ten mm crowding, in the suggested suitable case.

(b) *Intercanine width growth*

According to Moorrees and Reed (1965) intercanine width enlargement is minimal before the emergence of the permanent teeth (0·2 mm). The main growth phase (3·0 mm) occurred in both jaws of both sexes during the incisor transition. This increment levelled off after full eruption of the lateral incisors. In the maxilla a second increase (1·5 mm) was noted after the emergence of the permanent canines.

(c) *Incisor inclination*

The permanent maxillary and mandibular incisors are more proclined than their deciduous predecessors, and this creates a little more space in the arches.
These changes have been described by Graber (1972) and Dale (1985).

TECHNIQUE

The technique of serial extraction usually involves a period of incisor adjustment followed by a period of canine adjustment.
(a) In the period of incisor adjustment all deciduous canines are removed.
(i) All deciduous mandibular canines are removed after eruption of the permanent mandibular lateral incisors.
(ii) Some practitioners remove the deciduous maxillary canines *after* eruption of the maxillary lateral incisors. Others prefer to remove them, if it is deemed necessary, *before* the eruption of the maxillary lateral incisors.
No space maintainers are required.

Generally there is an improvement in the alignment of the incisors as they unravel into the space created by removal of the deciduous canines as seen in *Figures 1* and *2*. In *Figure 2* the deciduous maxillary canines were extracted before the lateral incisors had erupted. If the deciduous maxillary canines had been left in situ it is unlikely that the lateral incisors would have erupted in the line of the arch. However, in *Figure 3* there are spaces between the maxillary anteriors and thus it can be deduced that the rotations are due to a congenital/ hereditary malposition of the lateral incisors. So it is not surprising that the position of the lateral incisors did not improve when the deciduous canines were removed, as can be seen in the bottom study model.

The period of incisor adjustment creates space for their alignment by relieving crowding which, as Tulley and

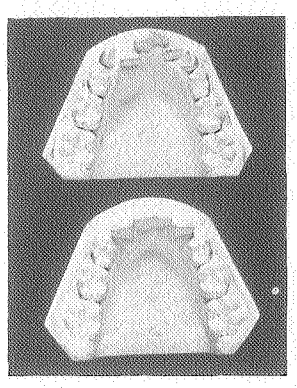

Figure 1. Improved alignment of permanent lateral incisors following extraction of deciduous canines

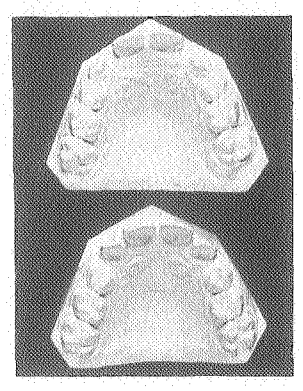

Figure 2. Uncrowded permanent lateral incisors in the line of the arch following deciduous canines removal

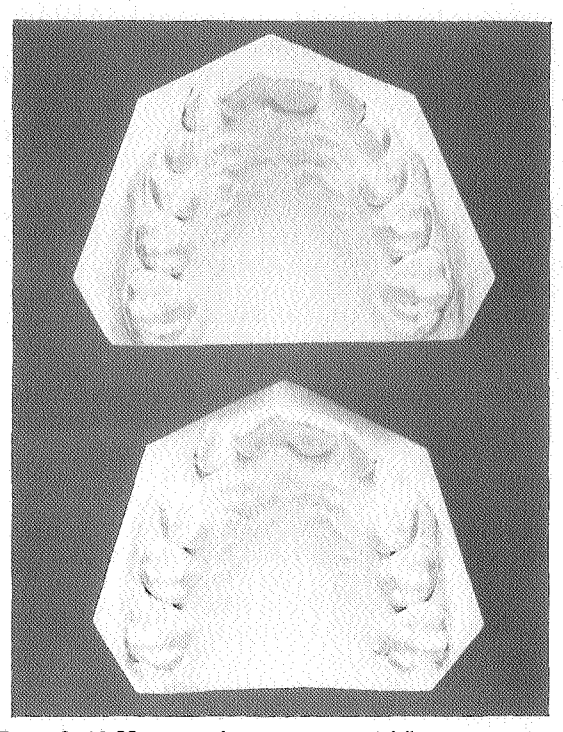

Figure 3. 12.22 position has not improved following extraction of the deciduous canines

Campbell (1970) say, 'has deliberately been transferred to the permanent canine region.'
(b) In the period of canine adjustment all first premolars are removed.

Discussion will involve:
(i) some general comments about the extraction of first premolars in serial extraction cases;
(ii) mandibular first premolar extraction, followed by;
(iii) maxillary first premolar extraction and finally;
(iv) further comments about the mandibular first premolar extraction.

Some general comments

The aim during this phase of treatment is to remove all first premolars before the canines erupt to ensure the most favourable adjustment of the canines into the spaces created.
The most favourable adjustment is obtained if a canine can erupt into the space rather than drift into it. The most favourable time for removal of the first premolar depends on the eruption sequence of the canine and first premolar, *as determined by radiographs*. There are ***three possibilities***:

1. canine erupting after the first premolar;
2. canine erupting at the same time as the first premolar;
3. canine erupting ahead of the first premolar.

• Possibility 1.
If the radiographs show that the canine will erupt after the first premolar, the deciduous first molar is allowed to exfoliate naturally. The first premolar is permitted to erupt and then it is removed. This situation occurs almost always in the maxilla and much less frequently in the mandible.
• Possibility 2.
If the canine's eruption rate equals that of the first premolar the deciduous first molar is removed to accelerate the eruption of the first premolar before the canine. After the eruption of the premolar the first premolar is removed.
• Possibility 3.
Canine ahead of first premolar is an eruption sequence which occurs infrequently in the maxilla but occurs in the mandible in seventy-five percent of patients according to Lo and Moyers (1953).

Mandibular first premolar extraction

If the mandibular canine is erupting ahead of the mandibular first premolar either of two courses of action can be followed:
(a) in a combined procedure extract deciduous mandibular first molars and surgically remove the unerupted permanent first premolars or
(b) to avoid the surgical procedure an alternative plan is
(i) to extract the deciduous mandibular first molars and
(ii) approximately six months later remove the deciduous mandibular second molars.
This allows the unerupted first premolars to move distally in the alveolar trough as the canine erupts. The mandibular first premolar erupts over the unerupted second premolar and the mandibular first premolar is removed upon eruption. If the deciduous mandibular second molar is removed it is wise to place a lingual arch in order to prevent the permanent mandibular first molar from moving mesially. This eruption sequence does not allow the best adjustment of the mandibular canine and necessitates placing an appliance. Since a large number of extractions (up to sixteen in total) would be necessary few orthodontists are keen on the surgical procedure outlined above nor do they extract deciduous mandibular second molars often.

Maxillary first premolar extractions

Because mesial drift of buccal segments occurs quickly in the maxilla, especially in crowded cases, a space maintainer must usually be fitted when maxillary first premolars are extracted. Since the maxillary canine is larger than the first premolar it follows that if there is only a small space between the lateral incisor and the first premolar the practitioner must be particularly careful to preserve all the space of the extracted first premolar. Some dentists extract the maxillary first premolars about twelve months before the canine's estimated eruption date. Others wait until the canine has almost erupted because they have had the experience of waiting for years with a space maintainer in the patient's mouth until the canine erupts. It is apt to say that "the maxillary first premolar is the best space maintainer". Occasionally maxillary canines have to be uncovered because they are so slow to erupt. In addition, removable space maintainers are occasionally lost and then the question of who pays for the replacement may become a source of friction between the orthodontist and patient.

The 23 moved very slowly in the patient illustrated in *Figures 4 (a), (b)* and *(c)*. The orthopantomogram (OPG*) shown in *Figure 4(b)* was taken forty-one months

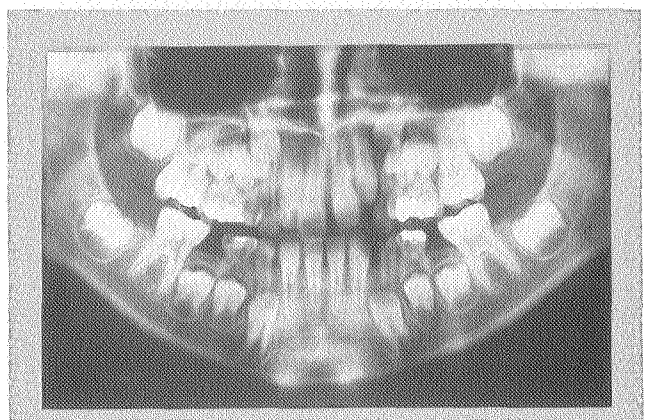

Figure 4(a). The case at commencement

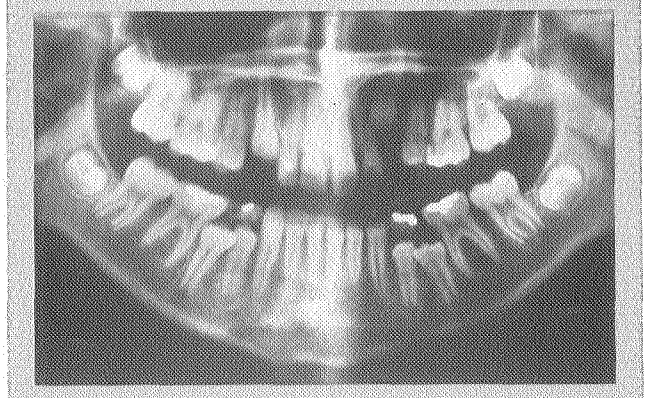

Figure 4(b). 23 has moved little in forty-one months

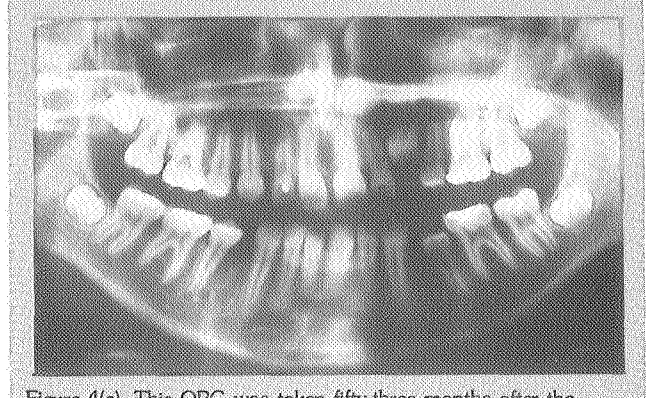

Figure 4(c). This OPG was taken fifty-three months after the OPG in Figure 4a. The 23 still had not erupted

* Siemens, Erlangen, W. Germany.

after the first exposure and the OPG of *Figure 4(c)* was taken fifty-three months after the OPG of *Figure 4(a)*. The 23 moved very little in that time span. The 13 erupted normally but 23 had to be uncovered. The patient ***wore space maintainers for three years and one month, lost two of the space maintainers in the process, had eight extractions and a surgical exposure*** of 23. So a considerable amount of time and money was expended on this apparently straight forward case.

Another valid reason for extracting the first premolar late rather than as soon as the tip of the cusp of the first premolar is evident is that if the first premolar is contacting or almost contacting the lateral incisor and the arch is in a pleasing alignment, this arrangement may be acceptable and extraction of the canine can be considered. The risk of the canine erupting unfavourably and the use of a space maintainer for a considerable period of time is then avoided. However, if the maxillary first premolar is rotated disto-lingually so that its broad mesial surface is apparent, as is the case in *Figure 5*, this is considered to be aesthetically displeasing and the premolar would not be preserved. The extraction of maxillary canines is not recommended often but there is a place for it. The labially excluded canines of the patient in *Figure 6* were extracted and a removable appliance was used for a few weeks to advance 12, with an adequate result.

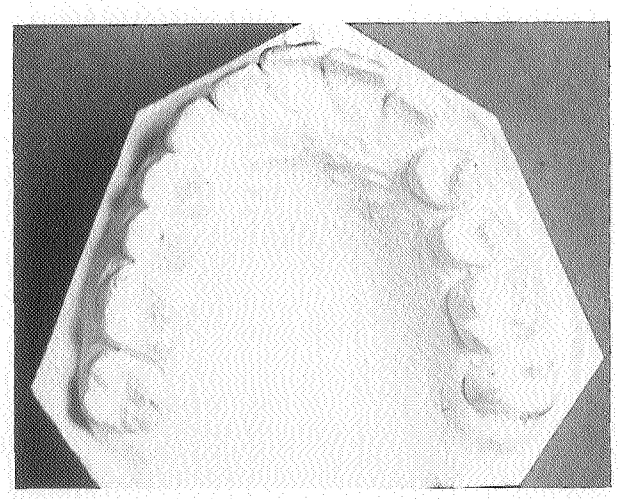

Figure 5. Unacceptable rotation of 24

Mandibular first premolar extractions - further comments

As said above, enucleation of the unerupted first premolar is not practised often. However, even if the canine erupts ahead of the first premolar (as occurs in seventy-five per cent of patients) and consequently the incisors re-crowd, as can be seen when comparing the middle and the bottom casts in *Figure 7*, first premolar extractions often allow much improved alignment of imbricated incisors, especially if they are not rotated. Some people have coined a rather disparaging title for this procedure of extracting mandibular first premolars with the aim of self correction of incisor crowding - they term it 'driftodontics'. Buccal segment drift is not as marked in the mandible as it is in the maxilla but even so, the space must be watched carefully and measurements must be taken at regular intervals. The patient of *Figure 8* was an exception for she did require a lingual arch because of too rapid space loss subsequent to first premolar extractions. The lingual arch was cemented in place immediately after

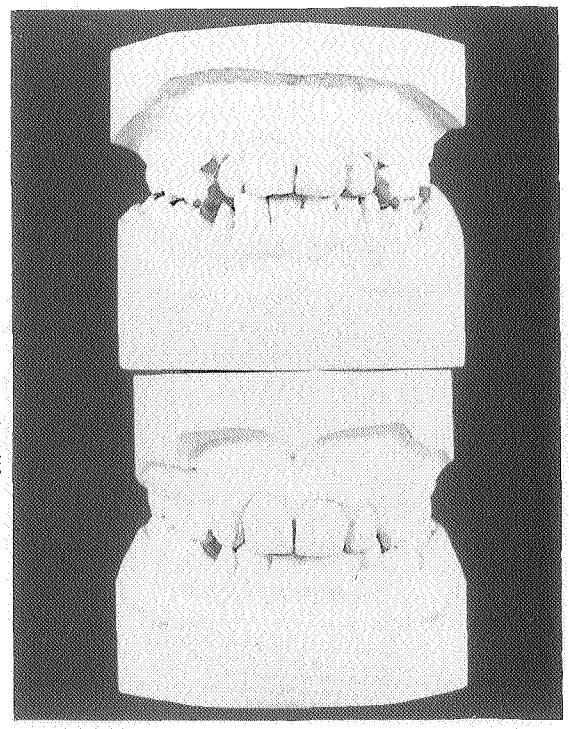

Figure 6. 13.23 were extracted for this patient. A removable appliance was used to move 12 labially

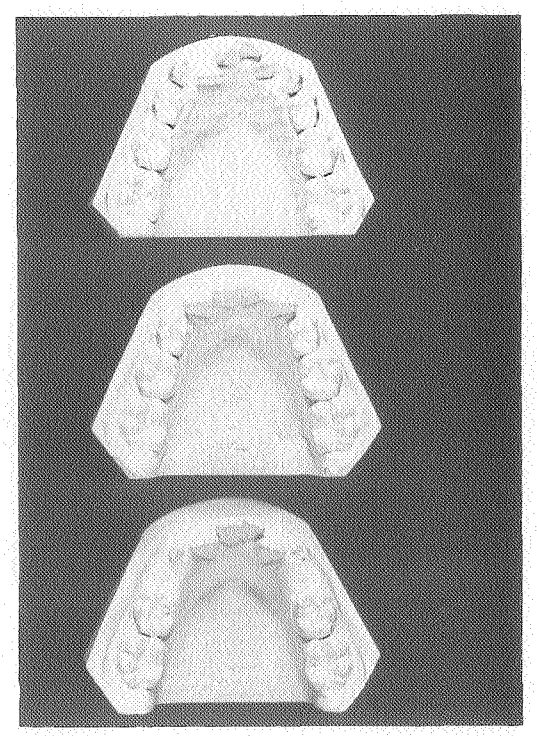

Figure 7. Crowding reappearing as canines erupt

the middle cast impression was taken. As a result the anteriors have aligned well, as is evidenced in the bottom model.

Modifications of the mandibular extraction sequence

Modifications of the mandibular extraction sequence have been suggested because the results have often been unsatisfactory when deciduous canines were extracted before deciduous first molars. All too frequently it is seen that the mandibular permanent canine, which develops at a lower level than the first premolar, accelerates to erupt

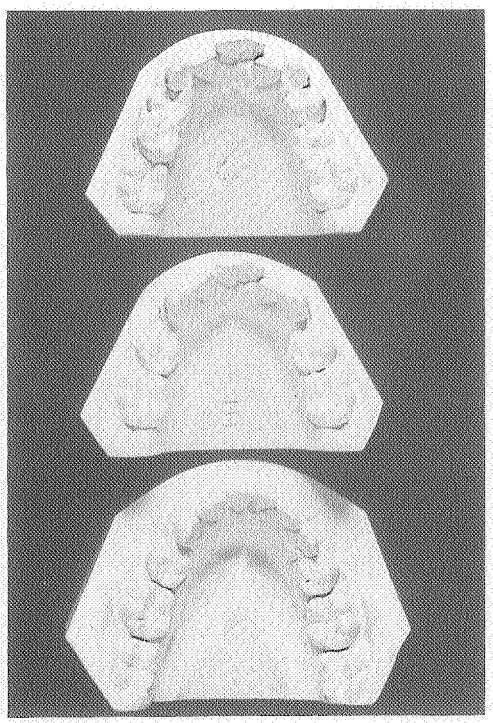

Figure 8. Too rapid space loss following first premolars extraction necessitated placement of a lingual arch at the visit when the middle cast was taken

before the first premolar. This leads to recurrence of crowding of the mandibular incisors.

The deciduous mandibular canines of the patient in *Figures 9(a)* and *(b)* were extracted before the deciduous mandibular first molars. In *Figure 9(a)* the canines are developing at a lower level than the first premolars and in *Figure 9(b)* they are erupting ahead of the first premolars.

To reduce the possibility of the mandibular canine erupting before the first premolar and to reduce the number of radiographs necessary to determine the eruption sequence it may be better treatment to always extract the deciduous mandibular first molars at the time of extraction of the deciduous canines. But even this modification is often unsuccessful. For the patient whose OPGs are shown in *Figures 10(a)* and *(b)*, deciduous mandibular canines and first molars were extracted together but once again the permanent canines have spurted past the first premolars.

Tweed (1966) said that the removal of the deciduous canines as the first step in the self-correction of irregularities of the incisors, particularly the lower incisors, is more often than not a serious error. Where this procedure is followed, as a rule, the mandibular canines erupt more rapidly than the first premolars beneath the deciduous first molars. (However, this eruption sequence occurs in seventy- five per cent of all children as has been pointed out above.)

The extraction sequence that Tweed recommended was:

(a) at approximately eight years of age extract all deciduous first molars. Unless there is unhealthy soft



Figure 9(a). Permanent mandibular canines developing at a lower level than the first premolars

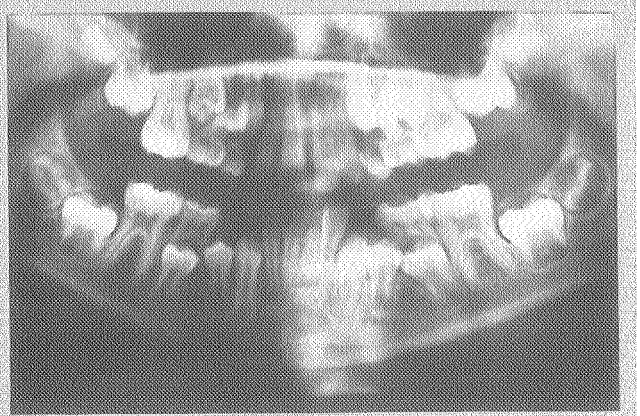

Figure 9(b). Deciduous mandibular canines were extracted first, then the deciduous first molars. The permanent mandibular canines are erupting ahead of the first premolars

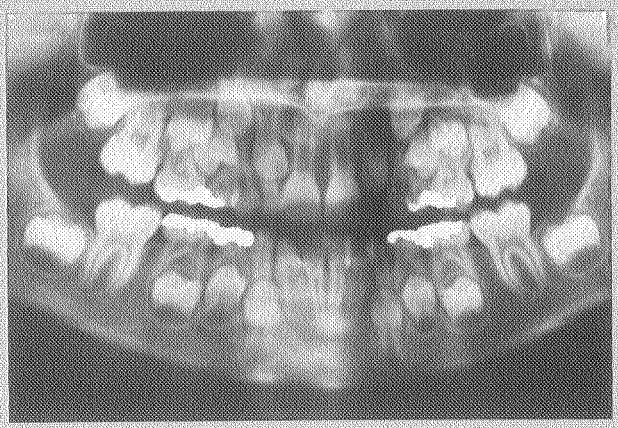

Figure 10(a). Permanent mandibular canines are developing at a lower level than the first premolars

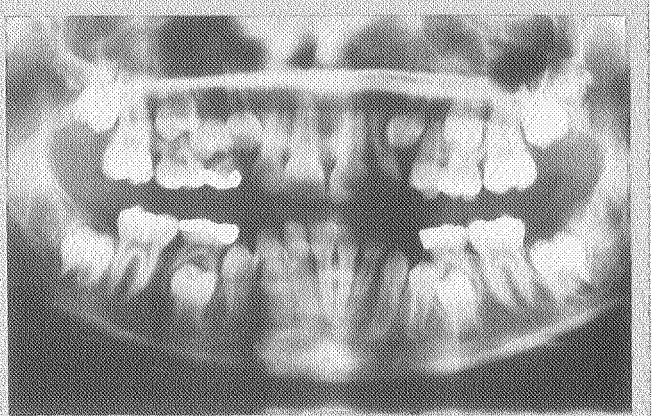

Figure 10(b). Deciduous mandibular canines and first molars were extracted together but the permanent canines are erupting ahead of the first premolars

tissue involvement around the lower incisors or blocked out maxillary incisors it is preferable to maintain the deciduous canines to retard eruption of the permanent canines;
(b) some four to ten months following extraction of all the deciduous first molars the first premolars will have erupted to gum level. They should not be removed until their crowns are through alveolar bone. At this time all first premolars are removed, along with all deciduous canines. If this is done at least four to six months prior to the eruption of the canines when they erupt they usually migrate into good position.
To overcome problems associated with unfavourable eruption sequences and to counteract varying degrees of crowding, i.e. from minor to severe amounts of dento-alveolar disproportion, many extraction sequences have been suggested such as:

(a) C,D,4;
(b) C + D,4;
(c) D,C + 4;
(d) C,D + enucleation of 4;
(e) C,D,E,4;
(f) C,D,no permanent tooth extraction;
(g) occasionally some or all second premolars are substituted for first premolars.

Where:
- C is the deciduous canine
- D is the deciduous first molar
- E is the deciduous second molar
- 4 is the first premolar).

This list indicates that there is no ideal extraction sequence and that serial extraction treatment is not an uncomplicated procedure.

▶ PRECAUTIONS

(a) The operator must *always check* that the permanent successors are:
(i) present;
(ii) of good quality;
(iii) of adequate morphology i.e. size and shape;
(iv) in the proper position
- before a sound, well formed and properly positioned first premolar is removed.

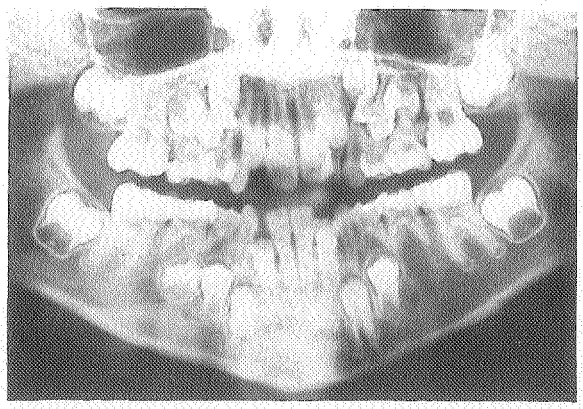

Figure 12. OPG shows 35 missing

(i) ***Present***
There cannot be many greater mistakes in dentistry than to remove sound teeth in order to make space for teeth that are not present. It must always be confirmed by radiographs that second premolars, in particular, are present. *Figure 11* shows the results of a serial extraction procedure with the unusual feature that 34 is present at completion, not 35. The OPG of *Figure 12* gives the answer why this is so - 35 is congenitally absent.

(ii) ***Of good quality***
Some second premolars and first molars are hypoplastic. In addition, if the first molar has gross caries, a deep restoration or has had any form of endodontic treatment it too should be judged to have a satisfactory life expectancy before a sound first premolar is extracted in preference to it.

(iii) ***Adequate morphology***
The patient whose casts are shown in *Figure 13,* has had a serial extraction procedure.
There are tiny second premolars and a peg 22 resulting in excessive space being present and poor occlusal contacts.

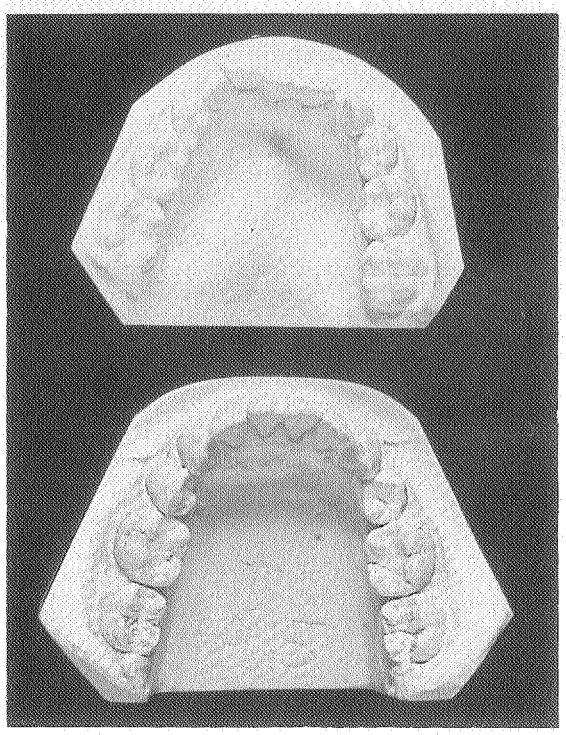

Figure 11. 34 present after serial extraction procedure



Figure 13. Small 15.25 and peg 22 result in excessive space being present

(iv) *In a good position to erupt*
(1) Not infrequently canines (especially maxillary canines) are impacted and one must be aware of this. Thus as stated above, the first premolars should not be extracted until the canines are prominent bulges. Maxillary canines are usually palpable at age nine.
(2) Occasionally second premolars are very rotated as is 45 in *Figure 11* and fixed appliances would be needed to correct the situation.

(b) *Extractions should not be executed too early.* This is because:
(i) growth changes are difficult to predict and there are marked variations between individuals;
(ii)scar tissue may be formed which will impede rather than accelerate the eruption of the underlying tooth.

(c) *The differences in size between the teeth in the arch must be considered.* Usually first premolars are extracted and
(i) maxillary canines are larger than first premolars and therefore maxillary space maintenance is usually required;
(ii) maxillary first premolars are larger than second premolars but the second premolars are often rotated and take up more space than estimated;
(iii) mandibular second premolars are larger than first premolars so sufficient space must be available for them. In addition, if the second premolars are rotated they require even more room.

▶ DISADVANTAGES

(a) Serial extraction may cause an increase of the overbite. The procedure is best avoided in class II division 2 malocclusions.
(b) It is unpleasant for a child to have four teeth extracted each time on three or four occasions, i.e. up to sixteen teeth - an important consideration.
(c) If extractions are carried out too early the results may be
(i) space loss and/or
(ii) delayed eruption of permanent successors and/or
(iii) elimination of the opportunity to:
(1) extract other teeth which may become doubtful (particularly permanent first molars) or
(2) delay banding for social or educational reasons if the serial extraction procedure does not produce a satisfactory result i.e. once permanent teeth are removed the patient is committed to immediate appliance therapy otherwise space loss would occur.

DISCUSSION and LITERATURE REVIEW

According to Pålsson (1956) a French pedodontist Bunon (1743) was the first to discuss a serial extraction type procedure. In the last three decades Tweed (1966), Mayne (1969), Graber (1972) and Dale (1985) have made particularly significant contributions in this area.

Some of Tweed's thoughts have already been mentioned. At the time (1966) he stated that he did not know any other person or institution who had complete records of all patients treated over the previous fifteen years. He presented the cephalometric readings of one hundred serial extraction cases and illustrated his work with full records of many of the cases.

Tweed said that, following the extractions, the mandibular incisors tipped an amount varying from 5° labially to 21·5° lingually; the average was 4 degrees lingually. The length of the guidance period varied from sixteen to one hundred and twenty months, the average being forty-one months. He suggested that radiographs of the extraction sites should be taken four monthly until the canines are fully erupted or until active treatment has started.

Gottlieb (1971a) wrote a thoughtful 'Editor's Corner' about serial extraction. He discussed the recommendations that Tweed (1966) and Mayne (1969) had made. Gottlieb counselled the need for caution in making decisions too early. He declared 'You will try hard to remember a case in which orthodontic treatment could not be accomplished because serial extraction had not been done. On the other hand .... probably remember a case or cases in which orthodontic treatment was less than satisfactory because serial extraction had been done improperly.'

Gottlieb (1971b) then went on to analyse a case he had treated with a serial extraction procedure followed by fixed appliances. There were eleven extractions (of seven deciduous and four permanent teeth) with a six year period of pre-orthodontic guidance during which the patient wore upper and lower space maintainers for sixteen months. Fixed appliances were in place for thirteen months. Gottlieb illustrated the period of pre-orthodontic guidance with four sets of lateral jaw radiographs, two lateral cephalometric radiographs, two sets of study models and many photographs.

The patient was seen fifty times in pre-orthodontic guidance (and this number probably does not include the visits in which extractions were done and radiographs taken). On reviewing these visits Gottlieb said that these were about twice as many visits as the case required.

Graber (1972) is another who has written a review of serial extraction. He stressed the need for active decision making at all stages of the procedure. He quotes Dewel as saying at a meeting in 1958 that 'By this procedure ... teeth ...are not first required to assume positions of extreme irregularity and then subjected to extensive orthodontic movement with extraction to establish acceptable occlusal relations. They are, instead, permitted to take these positions in the first place.'

Graber also stated that orthodontic therapy in extraction cases requires a degree of orthodontic skill and training well beyond the level of general practice. He said that serial extraction requires the knowledge, ability and clinical experience of the specialist who ultimately must complete the therapy in almost all cases. The operator must have the skill and training to cope with the problems of overbite, axial inclination, space closure, torque, rotations, paralleling and the complexities of the appliance necessary to achieve the best possible result for the patient. Graber declared that both patients and parents must be aware that serial extraction is a continuing program of orthodontic guidance over a period of four or five years.

Graber listed the stages in serial extraction therapy as:
(a) removal of deciduous canines. This is carried out between eight and nine years of age in patients with an average developmental pattern;

(b) removal of first deciduous molars. They are generally removed twelve months after the deciduous canines, i.e. between nine and ten years in the average developmental pattern;

(c) removal of the erupting first premolars. He said that sooner rather than later removal is better and that it serves no purpose to wait for the full eruption of the premolar teeth.

He declared that observation appointments at three monthly intervals are advisable. He stated that holding arches in either jaw are necessary only in extreme arch length deficiency cases. He said that there are very few times when, with proper guidance and optimal self adjustment, the teeth align themselves making mechanotherapy unnecessary. Treatment procedures usually do not exceed six to twelve months of mechanotherapy i.e. in the average serial extraction case mechanotherapy is reduced at least fifty per cent in terms of time and effort.

Lee (1980) presented seven patients aged six to eight years, who had crowded mandibular incisors. The crowding eventually resolved without treatment. He suggested that the presence of deciduous canines encourages optimal development of the mandible in the

canine area, which is important for the arrangement of the mandibular incisors. He did not present any measurements. Lee said that the rationale for extracting deciduous canines to alleviate crowding of mandibular incisors is questionable.

Mills (1982 pp.105-108) said that the technique of serial extraction has a limited application. His principal objections were:
(a) extraction of deciduous canines causes a slight mesial drift of the buccal segments and therefore a slight overall crowding in the arch;
(b) it requires monitoring at reasonably frequent intervals approximately every three months - and this is liable to use up the patient's co-operation;
(c) it is uncommon for the procedure to produce perfect alignment. A shortened period of appliance therapy is likely to be necessary when all the teeth have erupted. This is less likely to be successful if the patient's co-operation has already been exhausted;
(d) the extraction of twelve teeth on three separate occasions is an ordeal for any child.

Mills stated that he had never been responsible for the extraction of deciduous first molars as part of a serial extraction procedure. He also said that after the maxillary first premolars are removed it is essential to fit a maxillary space maintainer. He labelled the practice of eliminating crowding by the early extraction of deciduous first molars and the surgical removal of the developing first premolars as 'barbarous'.

Earlier in his book Mills (1982 p.15) presented photographs of his daughter at age seven years when she seemed very crowded and at eleven years when the child's teeth were in acceptable alignment without any treatment.

Dale (1985), drawing in particular on the work of Moorrees, Fanning and Grøn (1963), showed how the clinician has been provided with a scientific basis for prediction in relation to:
(a) the development of the dentition;
(b) the guidance of occlusion, including serial extraction, and
(c) the timing of treatment.

He said that the unerupted permanent tooth stands still until half its root is formed. Therefore extraction of the deciduous predecessor should be delayed until half of the root of the permanent successor is formed. He also wrote that teeth emerge into the oral cavity when three quarters of their roots are formed and he gave average times for the development of quarter stages of root length.

One way of contrasting British to North American attitudes to serial extraction is to see how much space they devote in their textbooks to this topic. On the British side Tulley and Campbell (1970) devoted two and one quarter pages out of two hundred and eighty three i.e. less than one per cent of the space in their book and Mills (1982) three pages in two hundred and forty six, i.e. a little more than one per cent. In contrast Graber (1972) devoted forty out of eight hundred and ninety two pages which is almost five per cent and Dale (1985) wrote one hundred and eight pages in a volume of eight hundred and ninety eight, i.e. 12 per cent.

SUMMARY and CONCLUSION

The rationale for serial extraction has been described. The usual unfavourable eruption sequence in the mandible has been emphasised as have various extraction procedures to counteract:
(i) this unfavourable eruption sequence and
(ii) varying amounts of crowding.

The pre-orthodontic guidance period may:
(a) be lengthy. Tweed (1966) said on average forty-one months;
(b) be uncomfortable (often twelve or more teeth are extracted);
(c) subject the patient to a large number of radiographs;
(d) be costly because of the number of visits, the records taken and the time for their analysis, the need for so many extractions, and the possible use of space maintainers and
(e) prejudice the patient's attitude to future mechanotherapy by exhausting his ability to cooperate.

Counterbalancing these unfavourable aspects is:
(a) the reduction in the duration of mechanotherapy, a saving in time of approximately six to nine months according to Tweed (1966) and up to fifty percent of the treatment declared Graber (1972) and
(b) the suggestion that the stability of the result is enhanced and the retention time reduced if teeth are given the opportunity to erupt into even alignment rather than being allowed to erupt into malalignment and then commencing treatment to correct the irregularities.

In conclusion, the serial extraction procedure is no longer one which can be recommended *especially* if there is no opportunity for the treatment to be completed with fixed appliances.

Acknowledgment

I would like to thank Ms Kerryn Inglis of the Department of Restorative Dentistry for cheerfully typing this paper.

REFERENCES

DALE,J.G. (1985)
Guidance of occlusion: serial extraction
In: Graber,T.M.,Swain,B.F. (Eds.) Orthodontics Current Principles and Techniques
St. Louis: C.V. Mosby, 259-366
GOTTLIEB, E.L. (1971a)
The editor's corner
J.Clin.Orthod. v(ii): 591-596
GOTTLIEB,E.L. (1971b)
The editor's casebook
J.Clin.Orthod. v(ii): 597-607
GRABER, T.M. (1972)
Orthodontics Principles and Practice
3rd ed. Philadelphia: W.B. Saunders, 709-748
LEE, K.P. (1980)
Behaviour of erupting crowded lower incisors
J.Clin.Orthod. xiv(1):24-33
LO, R.T. and MOYERS, R.E. (1953)
Studies in the etiology and prevention of malocclusion
Am.J.Orthod. 39: 460-467
MAYNE, W.R. (1969)
Serial extraction
In: Graber,T.M.(Ed) Current Orthodontic Concepts and Techniques
Philadelphia: W.B.Saunders: 179-274
MILLS, J.R.E. (1982)
Principles and Practice of Orthodontics
Edinburgh: Churchill Livingstone
MOORREES,C.F.A., FANNING,E.A. and GRØN,A.M. (1963)
The consideration of dental development in serial extraction
Angle Orthod. 33:44-59
MOORREES,C.F.A. and REED,R.B. (1965)
Changes in dental arch dimensions expressed on the basis of tooth eruption as a measure of biological age
J.Dent.Res. 44:129-141
MOYERS, R.E. (1973)
Handbook of Orthodontics
3rd ed. Chicago: Year Book
Medical Publishers Inc.:369-379
NANCE, H.N. (1947)
The limitations of orthodontic treatment I and II
Am.J.Orthod. 33 (4):177-223, 33 (5):253-301
PALSSON, F. (1956)
Föregangare till den s.k. serieextraktionen
Odont.Rev. 7:118-135
TULLEY,W.J. and CAMPBELL,A.C. (1970)
A manual of practical orthodontics
3rd ed. Bristol: John Wright and Sons, 112-113
TWEED, C.H. (1966)
Clinical Orthodontics Vol 1 and 2
St. Louis: C.V. Mosby

Correspondence to:
Dr Stanley Jacobs
Kenneth Adamson Department of Orthodontia
Royal Dental of Melbourne
711 Elizabeth Street
Melbourne Victoria 3000