



The Effect of Oral Acetaminophen on Open Arterial Duct Closure in Premature Infants Less Than 32 Weeks

Noor Mohammad Noori¹, Alireza Teimouri¹, Abdollah Dehvari¹, Somayeh Bagheie¹, Hossein Ansari¹

Abstract

Background: In most term neonates, the ductus arteriosus closes functionally on the first day of life, and a permanently open ductus arteriosus is abnormal.

Objectives: To evaluate the effect of oral acetaminophen on patent arterial duct (PDA) closure in premature infants less than 32 weeks.

Methods: This randomized clinical trial was performed on 140 preterm neonates with gestational age less than 32 weeks and birth weight less than 1,500 g, admitted to the neonatal intensive care unit of Ali Enbe Abitalib Hospital in Zahedan between 2019 and 2021. The neonates were randomly divided into two groups, with and without acetaminophen administration. In the intervention group, acetaminophen drops were started during the first 24 hours after birth and were administered for five days. In both groups, echocardiography was performed five days after birth. Finally, the data were analyzed in SPSS software.

Results: About 140 neonates with gestational age of ≤ 32 weeks and weight at birth $\leq 1,500$ g were admitted for the study. The neonates were equally divided into two groups and acetaminophen medication assigned for one of the groups. Of the 70 neonates who did not receive acetaminophen administration, 75.7% had PDA closure spontaneously; this pattern was 94.3% in patients who had treatment with acetaminophen. This effect of treatment was significant ($X^2=9.468$, $p=0.002$).

Conclusion: The study showed significant improvement in PDA in neonates receiving paracetamol. This can have a significant impact on the treatment approach to preterm neonates.

Keywords

Paracetamol, open arterial duct, preterm

Introduction

The arterial duct diverts blood away from the lungs during fetal life. It serves as the arterial connection between the aorta and the pulmonary artery. During normal cardiovascular embryological development, the arterial duct is formed by the sixth pair of embryonic arches.^[1] After preterm birth, the ductus arteriosus frequently stays open, and in 34% of very low birth weight (LBW) infants (Gestational age [GA] < 28 weeks as well as birth weight [BW] $< 1,000$ g) the ductus suddenly closed on the third day of life. However, it usually functionally closes in no less than a day in full-term babies.^[2]

The causes of duct closure after birth are numerous, and it has been shown that the increase in arterial blood oxygen pressure that occurs with ventilation of the lungs after birth leads to duct closure.^[3] The hemodynamic consequences of longer term PDA include excessive pulmonary circulation, which increases the risk of respiratory failure, pulmonary edema, and decreased alveolar growth associated with chronic lung disease; and systemic hypoperfusion, which may lead to renal failure and necrotizing enterocolitis.^[4] The treatment of PDA in preterm neonates has been the subject of debate

and controversy for many decades. Treatment options include fluid restriction, pharmacological intervention with nonsteroidal anti-inflammatory drugs (NSAIDs) or paracetamol, or closing the duct by surgical ligation or heart catheterization.^[5]

PDA closure, regardless of the type of method, also comes with risks. There is not always a consensus as to what gives the best prognosis for newborns, whether to wait or to close the PDA. Although pharmacological therapy appears to be less harmful, it is not without risks. As a result, efforts have been made to find a drug that, in addition to being effective, is safe.^[6]

Studies have shown that indomethacin was the drug of choice until 2010. Starting that year, and coinciding with the publication of the national consensus, ibuprofen replaced it.

Despite the similar efficacy between these two medications, indomethacin has been associated with a higher incidence of serious adverse reactions, such as acute and chronic renal failure, hyperkalemia, brain damage, and necrotizing enterocolitis.^[7]

In 2017, there was a need for analgesia in newborns with PDA closure, and as such, the first use of acetaminophen in this pathology appeared. It was considered to be beneficial to use only one drug for both purposes.^[8] Several studies have shown that acetaminophen has an efficacy similar to that of ibuprofen^[9] but with a lower incidence of acute renal failure, oliguria,^[9] platelet dysfunction, gastrointestinal bleeding, hyperbilirubinemia,^[10] and necrotizing enterocolitis.^[11]

Therefore, the present study was conducted to evaluate the effect of oral acetaminophen in the closure of PDA in preterm neonates

*Corresponding author: Alireza Teimouri, PhD, Zahedan University of Medical Sciences, Zahedan, Sistan and Baluchestan IRAN (ISLAMIC REPUBLIC OF); E-mail address: alirezateimouri260@gmail.com

¹Zahedan University of Medical Sciences, Zahedan, Sistan and Baluchestan IRAN (ISLAMIC REPUBLIC OF)

born in Ali Ebne Abitalib Hospital in Zahedan, the capital city of the Sistan and Baluchestan Province, Iran.

Methods

This clinical trial (IRCTID: IRCT20200218046538N1) was a double-blinded study conducted on 140 neonates with GA of ≤ 32 weeks and BW $\leq 1,500$ who were admitted to the NICU of Ali Ebne Abitalib hospital, Zahedan, Iran, between 2019 and 2021.

1. Exclusion criteria

Preterm neonates suffering from congenital heart defects, for which the opening of the ductus arteriosus is vital, such as pulmonary atresia with intact ventricular septum, the presence of major congenital abnormalities or chromosomal abnormalities, a history of using nonsteroidal anti-inflammatory drugs during pregnancy by the mother, the presence of hydrops fetalis or primary pulmonary hypertension in newborns, Apgar >5 minutes, PDA with symptoms, the presence of vomiting or hematemesis in the first three days after birth, glucose-6-phosphate dehydrogenase deficiency in the blood based on pre-hospitalization tests, death during study for any reason, those discharged against medical advice, and those who needed ibuprofen treatment were excluded from the study. Presence of life-threatening infections, grade 4-3 of intraventricular hemorrhage in the first 24 hours, urinary output less than mg/kg/h 1 in the past 8 hours, serum creatinine level higher than 1.8 mg/dl, platelet count $<50,000$ and hyperbilirubinemia that requires blood exchange, active necrotizing enterocolitis, intestinal perforation, liver dysfunction, gastrointestinal bleeding, retinopathy, bronchopulmonary dysplasia, parents' lack of consent to participate in the study were also causes for exclusion from the study.

2. Sample size and sampling method

All preterm neonates with a GA of <32 weeks and a BW $<1,500$ g, born in Ali Ibn Abi Talib (AS) hospital, Zahedan, who met the criteria for entering the study, were included in the study after obtaining parental consent and were randomly assigned. They were divided into two study groups using colored cards. It should be noted that the minimum sample size required for the study was determined by using the following formula; $N = \frac{p_1(1-p_1) + p_2(1-p_2)}{(p_1-p_2)^2} * f(\alpha, \beta)$; When; $f(\alpha, \beta) = 7.84$, $P_1 = 0.67(12)$ and $P_2 = 0.815(13)$ that resulted in 70 people in each group.

3. Method of conducting the study

Patients are placed in groups A and B using a table of random numbers. In group A, acetaminophen oral drops (acetaminophen Hakim Oral Drops, 100 mg/ml, Hakim Pharmaceutical Co., Tehran, Iran) at the rate of 15 mg/kg dose were administrated. They received each dose at six-hour intervals for five days.

Group B contained the newborns who were not administered acetaminophen.

Echocardiography was performed by a pediatric cardiologist using a GE Vivid 3 ultrasound machine (General Electric Healthcare)

in the neonatal intensive care unit at the end of the fifth day after birth for both groups. PDA criteria in echocardiography included the ratio of left atrium diameter to aortic root being more than 1.3 mm and the diameter of the internal canal more than 1.5 mm.

4. Statistical analysis

Data were analyzed by SPSS 24. Quantitative and qualitative data were described by mean and standard deviation, respectively. Chi-square and Mann-Whitney U tests were used to compare qualitative and quantitative variables, respectively, and logistic regression was used to find the odds for PDA closure in neonates that underwent treatment. All statistical analysis applied considered significance to be 0.05.

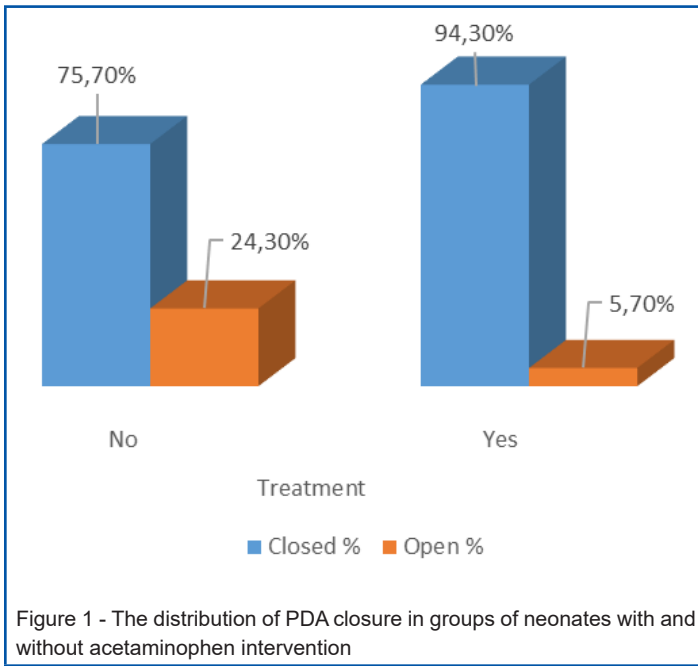
Results

The purpose of this study was to determine the effect of oral acetaminophen in the closure of PDA in premature infants. First the PDA size was measured before grouping; the analysis revealed that the size of PDA was same in the two groups of premature neonates. PDA size before treatment was 2.80 ± 0.042 and 2.81 ± 0.048 in groups of A and B, respectively (MWU=2172.00, $p=0.245$). The preterm neonates who were treated with acetaminophen were assigned to group A and the others (without treatment) to group B. Of preterm neonates who were treated by acetaminophen, about 94.3% experienced PDA closure. That was higher than those without treatment.

Table 1 reveals that all study variables had free distribution when analyzed with non-parametric testing. Table 2 shows nonparametric testing to compare the study variables between groups of premature neonates. These variables, such as weight ($p=0.844$), GA ($p=0.714$), Apgar in the first minute ($p=0.86$) and the fifth minute ($p=0.991$), left atrial to aortic root ratio (LA/Ao) ($p=0.627$) and PDA size ($p=0.247$) before treatment were similar in preterm neonates who were treated with acetaminophen compared with those who were not treated, but PDA size after treatment changed significantly, such that the mean PDA size after treatment was 0.6 ± 1.2 and 0.16 ± 0.67 in preterm neonates without and with treatment, respectively ($p=0.004$).

Figure 1 shows the association between groups of the preterm neonates and PDA status after treatment. Of the 70 neonates who were not referred for treatment, 75.7% had PDA closure spontaneously; this pattern was 94.3% in patients who were treated with acetaminophen. This effect of treatment was significant ($\chi^2=9.468$, $p=0.002$).

Table 3 shows logistic regression odds ratio (OR) analysis to assess the effect of certain factors on PDA closure in preterm neonates. The results revealed that treatment exposure had a significant effect on closure of PDA. The preterm neonates who received acetaminophen treatment had regular odds of 5.292 times more often than preterm neonates who did not receive acetaminophen treatment ($p=0.004$). When the odds are adjusted by other factors, the resultant odds of PDA closure increased to 6.394



($p=0.004$). The regular OR of LA/Ao was less than 1.0 and indicates that as the LA/Ao increases, the PDA closure is less likely to occur.

Table 4 shows the changes of some variables in those preterm neonates who were administered acetaminophen. This table shows that Apgar 1 (MWU=49.00, $p=0.033$), Apgar 5 (MWU=54.00, $p=0.047$), and PDA size before treatment (MWU=44.50, $p=0.023$) were significant.

Discussion

Paracetamol is an attractive option in cases in which COX inhibitors are contraindicated or ineffective.^[14]

The present study results show that from the preterm neonates who were not referred to treatment by acetaminophen, about three-quarters had spontaneous PDA closure; this pattern was about 94.3% in those who underwent treatment by acetaminophen. Preterm neonates that underwent treatment had 5.3 times greater odds to experience PDA closure than those who were not affected by treatment.

Aikio et al.^[15] has investigated the effect of early use of acetaminophen on reducing the incidence of residual patent arterial duct without side effects. From this study it is concluded that early administration of acetaminophen will increase the incidence of PDA closure.

Terrin et al.^[16] in a review reported that paracetamol administration to treat PDA had a significant effect on PDA closure and reduced the number of interventions without severe side effects, similar to Höck et al.^[17] The present study did not observe any side effects, which is dissimilar to Dash et al.,^[18] which demonstrated high intestinal bleeding after paracetamol medication.

To confirm the effectiveness of paracetamol treatment in PDA closure, similar outcomes were recorded by Harkin et al.^[19]: that

Table 1 - Normality test for quantities variables

Variables	Mean	SD	K.S	P-value
Weight	1251.32	199.05	0.132	<0.001
Age	30.07	1.53	0.213	<0.001
Apgar in the first minute	7.39	0.76	0.25	<0.001
Apgar in the fifth minute	8.61	0.64	0.308	<0.001
LA/Ao	1.58	0.09	0.116	<0.001
PDA size before treatment	2.80	0.05	0.086	0.013
PDA size after treatment	0.42	1.00	0.512	<0.001

Table 2 - Comparing some variables in preterm infants based on treatment

Variables	Treatment	Mean	SD	Mean Rank	MWU	P-value
Weight (gr)	No	1249.79	205.44	69.83	2403.00	0.844
	Yes	1252.86	193.92	71.17		
Gestational Age (week)	No	30.03	1.55	69.27	2364.00	0.714
	Yes	30.11	1.53	71.73		
Apgar in the first minute	No	7.40	0.75	71.06	2411.00	0.86
	Yes	7.37	0.78	69.94		
Apgar in the fifth minute	No	8.6	0.67	70.54	2447.50	0.991
	Yes	8.61	0.62	70.46		
LA/Ao	No	1.58	0.09	72.15	2334.50	0.627
	Yes	1.57	0.09	68.85		
PDA size before treatment	No	2.80	0.04	66.53	2172.00	0.247
	Yes	2.81	0.05	74.47		
PDA size after treatment	No	0.67	1.20	76.56	2025.50	0.004
	Yes	0.16	0.67	64.44		

MWU: Mann-Whitney U test.

paracetamol induced early closure of the PDA without detectable side effects.

Aikio et al.^[15] and Bagheri et al.^[20] administered paracetamol to a group of newborns with PDA. They reported that the outcomes of echocardiography on day 4 showed PDA closure was higher in the treated compared to untreated groups.

Schindle et al.^[21] aimed to investigate the safety profile of paracetamol used to close PDA during the early postnatal period. They concluded that early paracetamol treatment significantly reduced the number of neonates requiring intervention for PDA.

With a little reflection on the results of Dash et al.,^[18] this is a surprisingly different result for the effects of paracetamol, but it should be noted that this study evaluates only preterm infants with mean GA of 31.6 weeks. Dissimilar findings reported by Asbagh et al.^[23] found that PDA closure was not affected by acetaminophen administration. In this study, 32 preterm neonates were entered into the study (thus, sample size was low in each group). That is the reason for having different results from many literatures and the present study results.

Table 3 - Logistic regression analysis on affective variables on PDA status after treatment

Variables (Reference group)	Regular Odds ratio				Adjusted Odds ratio			
	β	Wald	Sig.	OR	β	Wald	Sig.	OR
Sex (male)	0.090	0.036	0.849	1.094	-0.391	0.465	0.495	0.677
Weight	0.002	2.556	0.11	1.002	0.001	0.616	0.432	1.001
Gestational Age	0.376	6.078	0.014	1.457	0.371	2.925	0.087	1.449
Apgar at the first minute	0.503	2.463	0.117	1.654	0.966	3.134	0.077	2.626
Apgar at the fifth minute	0.239	0.417	0.518	1.27	-0.803	1.753	0.185	0.448
Parity 2 (parity 1)	0.049	0.007	0.931	1.05	-0.542	0.664	0.415	0.582
Parity 3 or more (parity 1)	0.548	0.884	0.347	1.73	0.459	0.453	0.501	1.582
LA/Ao	-1.893	0.474	0.491	0.151	-3.558	1.279	0.258	0.028
Treatment (No)	1.666	8.098	0.004	5.292	1.855	8.462	0.004	6.394

Table 4 - comparison between preterm neonates with PDA treatment with oral acetaminophen

Variables	PDA closure	Mean	SD	Mean Rank	MWU	P-value
Weight	Yes	1259.85	194.99	36.29	80.00	0.201
	No	1137.5	149.3	22.50		
Gestational Age	Yes	30.18	1.53	36.52	65.00	0.093
	No	29.00	1.15	18.75		
Apgar at the first minute	Yes	7.42	0.77	36.76	49.00	0.033
	No	6.50	0.58	14.75		
Apgar at the fifth minute	Yes	8.65	0.62	36.68	54.00	0.047
	No	8.00	0.01	16.00		
LA/Ao	Yes	1.57	0.09	34.95	96.00	0.383
	No	1.61	0.07	44.50		
PDA size before treatment	Yes	2.80	0.05	34.17	44.5.00	0.023
	No	2.86	0.02	57.38		

MWU: Mann-Whitney U test

A recent review compared oral paracetamol against intravenous ibuprofen in PDA closure and suggested that paracetamol was as effective as ibuprofen, with less gastrointestinal bleeding and lower serum creatinine levels.^[14] Yang et al.^[9] showed similar PDA closure rates between oral paracetamol and ibuprofen, but observed fewer side effects in neonates receiving paracetamol, with a lower prevalence of oliguria. As a result of this study, paracetamol showed less toxicity, and urinary plasma prostaglandin E2 levels were lower in this group. In the present study, it was observed that none of the variables, including gestational age, weight at birth, Apgar in minutes 1 and 5, birth order, and LA/Ao, were comparable between the groups of neonates. Additionally, none of the neonates treated with acetaminophen experienced any adverse side effects that affected their gastrointestinal or urinary systems.

Nemerofsky et al.^[12] conducted a prospective observational study on 65 neonates with very low BW (<1,500 g) found that spontaneous ductal closure occurred at 7 days of age in 31% of neonates with BW <1000 g and 67% of neonates with BW >1,000 g. For neonates with BW <1,000 g, spontaneous closure occurred without intervention before discharge in 47% of cases. In another recent observational study, 100% of 32 very low BW neonates who were not treated had

spontaneous closure of PDA (66% before and 34% after hospital discharge)^[24] compared with the present study that observed about 75% PDA closure in the neonates without treatment.

Benitz et al.^[25] found that among 63 treated neonates (7 primary ligation, 56 indomethacin), the ductus closed after primary treatment with indomethacin in 38 neonates; ligation was performed after indomethacin in 15, and 10 were discharged with PDA.

A left-to-right ductal shunt causes increased pulmonary blood flow and ductal steal from the systemic circulation and thus can have adverse effects on premature infants, although a causal relationship is not well defined.^[25, 26] Although our results do not prove that treatment for PDA is never necessary, they indicate that most neonates with persistent PDA beyond the third day after birth, particularly those with BW >1,000, can be expected to do well without treatment specifically intended to achieve ductal closure.^[25-27] In preterm infants, spontaneous PDA closure occurs less frequently. PDA in preterm neonates is thought to be the result of generalized immaturity of the smooth muscle and biochemical oxygen sensing mechanisms. The time it takes to achieve closure is inversely proportional to GA at birth.^[26, 28] To be sure, the preterm ductus is transcriptionally different from vessels at term.^[27] Failure

to close is correlated with the absence or rudimentary formation of intimal cushions in preterm ductus arteriosus (DA). Similarly, preterm vessels lack the vasa vasorum and have fewer layers of contractile smooth muscle cells.^[28] This can bring about incomplete post-pregnancy narrowing without the ischemia-driven renovating basic to long-lasting conclusion. Extrinsic factors that make vessel closure more difficult are also present in preterm DAs. Preterm DAs exposed to sustained bidirectional, right-to-left, or low-velocity blood flow were more likely to remain patent and were resistant to pharmacologic therapy, as demonstrated by echocardiographic studies.^[29] This highlights the role that hemodynamic forces and pulmonary vascular resistance play in regulating DA tone. Additionally, research on the function of platelets has produced contradictory findings. In some, very preterm neonates showed an association between low platelet count and delayed spontaneous or pharmacologic PDA closure; however, platelet transfusions did not speed up PDA closure in preterm neonates with thrombocytopenia.^[30] It was argued that platelet function, not number, was the key regulator of preterm PDA status.^[31] In a retrospective cohort study conducted by Vaidya et al.^[13] on preterm neonates less than 30 weeks, single course acetaminophen treatment resulted in a lower successful PDA closure rate. In addition, they found that both GA>26 weeks and PDA size ≤0.2cm were associated with higher probability of successful PDA closure following acetaminophen. Based on all above-mentioned studies and the present study, it would seem that administering acetaminophen has a significant effect on PDA closure in preterm neonates. In this study, there was no specific limitation other than the lack of consent of some patients to carry out the plan, which was resolved due to the high load of patients.

REFERENCES

1. Jasani B, Weisz DE, McNamara PJ. Evidence-based use of acetaminophen for hemodynamically significant ductus arteriosus in preterm infants. *Semin Perinatol* 2018; 42(4):243–52.
2. De Klerk JC, Engbers AG, Van Beek F, et al. Spontaneous closure of the ductus arteriosus in preterm infants: a systematic review. *Front Pediatr* 2020; 8:541.
3. Fink D, Nitzan I, Bin-Nun A, et al. Ductus arteriosus outcome with focus on the initially patent but hemodynamically insignificant ductus in preterm neonates. *J Perinatol* 2018; 38(11):1526–31.
4. Hundscheid T, Onland W, Overmeire B Van, et al. Early treatment versus expectant management of patent ductus arteriosus in preterm infants: a multicentre, randomised, non-inferiority trial in Europe (BeNeDuctus trial). *BMC Pediatr* 2018; 18:262. doi: 10.1186/s12887-018-1215-7
5. Faim DRO, Tiago JAM, Castelo RJS, et al. Patent ductus arteriosus closure: Experience from a tertiary referral center. *Rev Paul Pediatr* 2020; 39:e2020013. doi: 10.1590/1984-0462/2021/39/2020013
6. El-Mashad AE, El-Mahdy H, Amrousy D El, et al. Comparative study of the efficacy and safety of paracetamol, ibuprofen, and indomethacin in closure of patent ductus arteriosus in preterm neonates. *Eur J Pediatr* 2017; 176:233–40. doi: 10.1007/s00431-016-2830-7
7. Bardanzellu F, Neroni P, Dessi A, et al. Paracetamol in patent ductus arteriosus treatment: efficacious and safe? *Biomed Res Int* 2017; 2017:1438038. doi: 10.1155/2017/1438038.
8. Al-lawama M, Alamkori I, Abdelghani T, et al. Oral paracetamol versus oral ibuprofen for treatment of patent ductus arteriosus. *J Int Med Res* 2018; 46:811–8. doi: 10.1177/0300060517722698

Conclusion

The present study concluded that a significant gap existed between the rates of PDA closure of treated and untreated neonates by acetaminophen. It means that acetaminophen would be a significant accelerator of PDA closure, especially in preterm neonates in the early days of their lives.

Future studies with a larger sample size and with comparable treatment strategies for medical management of PDA closure are needed to identify the most effective and safest treatment with highest probability of successful closure.

Acknowledgements

The authors would like to acknowledge the parents of the newborns.

Conflict of interests

The authors would like to declare no conflicts of interest.

Authors' contribution

NMN: supervising the study in all stages and drafting the manuscript, AD: supervising the study in all stages, SB: data collection, HA: data analysis, AT: data analysis, literature and drafting the manuscript.

9. Yang B, Gao X, Ren Y, et al. Oral paracetamol vs. oral ibuprofen in the treatment of symptomatic patent ductus arteriosus in premature infants: A randomized controlled trial. *Exp Ther Med* 2016; 12:2531–6. doi: 10.3892/etm.2016.3676
10. Dang D, Wang D, Zhang C, et al. Comparison of oral paracetamol versus ibuprofen in premature infants with patent ductus arteriosus: a randomized controlled trial. *PLoS ONE* 2013; 8:e77888. doi: 10.1371/journal.pone.0077888
11. Karabulut B, Paytoncu S. Efficacy and safety of oral paracetamol vs. oral ibuprofen in the treatment of symptomatic patent ductus arteriosus in premature infants. *Pediatr Drugs* 2019; 21:113–21.
12. Nemerofsky SL, Parravicini E, Bateman D, et al. The ductus arteriosus rarely requires treatment in infants > 1000 grams. *Am J Perinatol* 2008; 25:661–6.
13. Vaidya R, Knee A, Paris Y, et al. Predictors of successful patent ductus arteriosus closure with acetaminophen in preterm infants. *J Perinatol* 2021; 41(5):998–1006.
14. Ohlsson A, Shah PS. Paracetamol (acetaminophen) for patent ductus arteriosus in preterm or low birth weight infants. *Cochrane Database Syst Rev* 2018; (4).
15. Aikio O, Harkin P, Saarela T, et al. Early paracetamol treatment associated with lowered risk of persistent ductus arteriosus in very preterm infants. *J Matern-Fetal Neonatal Med* 2014; 27(12):1252–6.
16. Terrin G, Conte F, Oncel MY, et al. Paracetamol for the treatment of patent ductus arteriosus in preterm neonates: A systematic review and meta-analysis. *Arch Dis Child: Fetal Neonatal Ed* 2016; 101(2):F127–36.

17. Höck M, Brunner B, Rier V, et al. Prophylactic low-dose paracetamol administration associated with lowered rate of patent ductus arteriosus in preterm infants: Impact on outcome and pain perception. *Pediatr Neonatol* 2020; 61(1):84–91.
18. Dash SK, Kabra NS, Avasthi BS, et al. Enteral paracetamol or intravenous indomethacin for closure of patent ductus arteriosus in preterm neonates: A randomized controlled trial. *Indian Pediatr* 2015; 52(7):573–8. doi: 10.1007/s13312-015-0677-z
19. Härkin P, Härmä A, Aikio O, et al. Paracetamol accelerates closure of the ductus arteriosus after premature birth: A randomized trial. *J Pediatr* 2016; 177:72–7.
20. Bagheri MM, Bahman-Bijari B, Torabi-Nejad MH, et al. Is prophylactic parenteral paracetamol effective to diminish incidence of PDA in preterm neonates? A randomized trial. *Iran J Pediatr* 2018; 28(4).
21. Schindler T, Smyth J, Bolisetty S, et al. Early Paracetamol (EPAR) trial: A randomized controlled trial of early paracetamol to promote closure of the ductus arteriosus in preterm infants. *Neonatology* 2021; 118:274–81. doi: 10.1159/000515415
22. Davidson JM, Ferguson J, Ivey E, et al. A randomized trial of intravenous acetaminophen versus indomethacin for treatment of hemodynamically significant PDAs in VLBW infants [published online ahead of print, 2020]. *J Perinatol*. doi: 10.1038/s41372-020-0694-1
23. Asbagh PA, Zarkesh MR, Nili F, et al. Prophylactic treatment with oral paracetamol for patent ductus arteriosus in preterm infants: A randomized clinical trial. *Tehran Univ Med J* 2015; 73(2).
24. Herrman K, Bose C, Lewis K, et al. Spontaneous closure of the patent ductus arteriosus in very low birth weight infants following discharge from the neonatal unit. *Arch Dis Child: Fetal Neonatal Ed* 2009; 94(1):F48–50.
25. Benitz WE. Treatment of persistent patent ductus arteriosus in preterm infants: time to accept the null hypothesis? *J Perinatol* 2010; 30(4):241–52.
26. Semberova J, Sirc J, Miletin J, et al. Spontaneous closure of patent ductus arteriosus in infants \leq 1500 g. *Pediatr* 2017; 140(2).
27. Goyal R, Goyal D, Longo LD, et al. Microarray gene expression analysis in ovine ductus arteriosus during fetal development and birth transition. *Pediatr Res* 2016; 80(4):610–8.
28. Hamrick SE, Sallmon H, Rose AT, et al. Patent ductus arteriosus of the preterm infant. *Pediatr* 2020; 146(5).
29. Olsson KW, Jonzon A, Sindelar R. A high ductal flow velocity is associated with successful pharmacological closure of patent ductus arteriosus in infants 22–27 weeks gestational age. *Crit Care Res Pract* 2012; 2012:715265.
30. Kumar J, Dutta S, Sundaram V, et al. Platelet transfusion for PDA closure in preterm infants: A randomized controlled trial. *Pediatr* 2019; 143(5):e20182565.
31. Kahvecioglu D, Erdeve O, Akduman H, et al. Influence of platelet count, platelet mass index, and platelet function on the spontaneous closure of ductus arteriosus in prematurity. *Pediatr Neonatol* 2018; 59(1):53–7.