sciendo Internal Medicine 2023 vol. XX No. 4 - www.srmi.ro 97
10.2478/inmed-2023-0272

COMPLEMENT BLOCKADE, A NEW THERAPEUTIC APPROACH IN MALIGNANT HYPERTENSION

Camelia-Adriana Achim[1], Cătălina Voicu-Titere[2], Georgiana Aurelia Nae[3], Daniela-Gabriela Florescu[2], Rareș-Vasilica Moisa[2] , Gener Ismail[1]
[1] "Carol Davila" University of Medicine and Pharmacy, Bucharest, Romania
[2] Department of Nephrology, Fundeni Clinical Institute, Bucharest, Romania
[3] Department of Nephrology, County Emergency Hospital Giurgiu, Giurgiu, Romania

Abstract
Atypical hemolytic uremic syndrome (aHUS) represents a major challenge due to its rare nature and severe impact on patients, characterized by microangiopathic hemolytic anemia, thrombocytopenia, and acute renal failure. This paper describes the case of a 41-year-old patient diagnosed with aHUS in the context of malignant arterial hypertension and severe renal impairment, manifested by anuria and significant azotemic retention syndrome. The complex management of the case, including the use of Eculizumab, a complement inhibitor, highlighted significant therapeutic benefits, especially in improving hematological parameters. Despite a positive response, challenges related to dosing, monitoring treatment efficacy, and maintaining remission without relapses emphasize the need for adapted therapeutic strategies and a deeper understanding of the disease mechanisms. This case also highlights the importance of individualized approaches and consideration of the possible benefits of dose adjustments based on specific clinical and pharmacological parameters, as well as continuous evaluation of treatment efficacy and safety, in the context of such a variable and potentially devastating syndrome as aHUS.
Keywords: *atypical hemolytic uremic syndrome, Eculizumab.*

Rezumat
Sindromul hemolitic uremic atipic (SHUa) reprezintă o provocare majoră ca urmare a naturii sale rare și impactului sever asupra pacienților, caracterizat prin anemie hemolitică microangiopatică, trombocitopenie și insuficiență renală acută. Această lucrare descrie cazul unui pacient de 41 de ani diagnosticat cu SHUa în contextul hipertensiunii arteriale maligne și insuficienței renale severe, manifestată prin anurie și sindrom semnificativ de retenție azotată. Managementul complex al cazului, inclusiv utilizarea Eculizumab, un inhibitor al complementului, a evidențiat beneficii terapeutice semnificative, în special în îmbunătățirea parametrilor hematologici. În ciuda unui răspuns pozitiv, provocările legate de dozare, monitorizarea eficacității tratamentului și menținerea remisiunii fără recidive subliniază necesitatea unor strategii terapeutice adaptate și a înțelegerii mai profunde a mecanismelor bolii. Acest caz subliniază, de asemenea, importanța abordărilor individualizate și posibilele beneficii ale ajustării dozei pe baza unor parametri clinici și farmacologici specifici, precum și evaluarea continuă a eficacității și siguranței tratamentului, în contextul unui astfel de sindrom variabil și potențial devastator precum SHUa.
Cuvinte cheie: *sindrom hemolitic uremic atipic, Eculizumab.*



Internal Medicine

Clinical Cases

Introduction

Atypical hemolytic uremic syndrome (aHUS) is a rare disorder caused by the overactivation of the alternative complement pathway and is primarily characterized by thrombotic microangiopathy (TMA)[1,2]. TMA describes a group of syndromes with multiple etiologies, both hereditary and acquired, that have a characteristic microvascular pathology causing microangiopathic hemolytic anemia and thrombocytopenia[3]. Patients diagnosed with aHUS often require renal replacement therapy (hemodialysis, continuous or intermittent hemodiafiltration, temporary or permanent). Its estimated prevalence is 1-2 cases/million worldwide.

Approximately 30% of aHUS cases are associated with dysfunctions in the gene (CFH) responsible for producing a blood protein known as factor H. This is the most common genetic mutation associated with aHUS. Factor H is one of the regulatory proteins of the complement system that protects blood vessels from injury. When factor H is deficient or inactive, there is potential for damage to small vessels in the kidneys, with secondary manifestations on red blood cells and platelets[4].

Autoantibodies directed against complement factor H (CFH) are reported in approximately 8 to 10 percent of patients with complement-mediated TMA and may be more frequent in some countries [5,6]. Most people with autoantibodies against CFH appear to have a homozygous deletion of the CFHR1 and/or CFHR3 genes, suggesting that these deletions have a pathogenic role in the development of autoantibodies against factor H[19].

Eculizumab is a recombinant humanized monoclonal antibody, a complement inhibitor, and the first approved treatment for patients with aHUS. It binds with high affinity to C5, inhibiting the cleavage of C5 into C5a and C5b and preventing the generation of the complement terminal complex C5b-9, thus inhibiting complement-mediated TMA[7]. Eculizumab can help manage aHUS symptoms such as anemia (due to hemolysis) and low platelet count (thrombocytopenia) by preventing further destruction of red blood cells and platelets. It was approved for the treatment of aHUS in Romania in March 2021.

This article describes the case of a young patient diagnosed with aHUS in the context of malignant arterial hypertension, who presented with anuria, significant azotemic retention syndrome, and severe anemia, and was initiated on Eculizumab treatment.

Case Report

A 41-year-old patient, known with high blood pressure values for a year, neglected therapeutically, without significant historical antecedents, was transferred to our Clinic on

Parameter	Results	Normal Range - UM
Creatinine	11.05 mg/dl	0.7 – 1.3 mg/dl
Urea	182.7 mg/dl	19 – 49 mg/dl
Calcium	7.9 mg/dl	8.7 – 10.4 mg/dl
K	3.9 mmol/l	3.5 – 5.1 mmol/l
Na	135 mmol/l	132 - 146 mmol/l
CK	302.4 U/l	46 – 171 U/l
CK-MB	14.12 U/l	0 – 24 U/l
LDH	742 U/l	208 – 378 U/L
Direct Bilirubin	0.1 mg/dl	0 – 0.3 mg/dl
Indirect Bilirubin	0.3 mg/dl	0 – 1 mg/dl
C-reactive protein	69.3 mg/l	0 – 5 mg/l
ESR	50 mm/h	2 -15 mm/h
Fibrinogen	698 mg/dl	200 – 400 mg/dl
D-Dimers	5.36 ug/ml	0 – 0.5 ug/ml
Hemoglobin	7.1 g/dl	11.5 – 17 g/dl
Platelets	272 * 10^3 ul	150-400 * 10^3 ul
Serum Iron	24 ug/dl	65 – 175
Ferritin	255 ng/ml	22 – 322 ng/ml
iPTH	323.7 pg/ml	18.5 – 88 pg/ml
Haptoglobin	0.25 g/l	0.3 – 2 g/l
Albumin	3.32 g/dl	3.2 – 5.2 g/dl
Uric acid	4.62 mg/dl	3.7 – 9.2 mg/dl
ANA screen	0.9 Ratio Neg	
Anti ds-DNA screen	8.4 U/ml	0 – 25 U/ml
ANCA	0.1 Ratio Neg	0 – 1 U/ml
Cryoglobulins	Absent	
RNP/Sm	0.7^U/ml neg	
C3	99.3 mg/dl	90 – 180 mg/dl
C4	22.2 mg/dl	10 – 40 mg/dl
Hepatitis B surface antibody	13.92 UI/ml	
Hepatitis B surface antigen	< 0.10	0.1 – 1
Hepatitis C antibody	0.03	0 – 0.8
HIV	0.14	0 – 1
IgA	179 mg/dl	63 – 484
IgG	891 mg/dl	540 – 1822 mg/dl
IgM	78 mg/dl	22 – 240 mg/dl

Table 1. *Biological parameters on admission in our clinic*



March 15, 2022, for a mediocre general condition, anuria of about 4 days, and fatigue. He reports taking NSAIDs at home and 2 episodes of macroscopic hematuria at the beginning of March 2022.

In another hospital unit, in the emergency room, 24 hours ago, the patient was detected with high blood pressure values (systolic blood pressure = 250 mmHg), with significant azotemic retention syndrome (creatinine 25 mg/dl, urea 400 mg/dl). A computed tomography (CT) examination of the chest-abdomen-pelvis with contrast substance was performed, which describes the absence of renal excretion at 5 minutes, without obstruction. The patient underwent a continuous veno-venous hemodiafiltration session prior to transfer.

The objective examination at admission does not reveal significant changes, the patient presents a mediocre general condition, normal weight, pale skin and mucous membranes, blood pressure 150/90 mmHg (in recent treatment initiated with 6 classes of antihypertensives), rhythmic Ventricular Rate (AV) 96/min, urethral catheter present with 100 ml of hyperchromic urine.

Among the paraclinical investigations, we mention the abdominal ultrasound that reveals slightly reduced kidneys, with reduced parenchymal index bilaterally (right kidney with a long axis of 105 mm, parenchymal index (PI) = 17 mm, superior cortical cyst of 34 mm, and left kidney with a long axis of 112 mm, PI = 13 mm, both with attenuation of corticomedullary differentiation, without SPC distension, without calculi, without other modifications). The chest X-ray shows bilateral pleurisy, in small quantity on the left side, and minimal on the right side, which associates passive collapse of the underlying lung parenchyma, and the ophthalmologic examination reveals papillary edema and supports the diagnosis of hypertensive neuro-retinopathy.

We consider renal impairment in the context of malignant arterial hypertension (MAH) neglected therapeutically, taking into account the high blood pressure values, difficult to control therapeutically, > 200mmHg, the ultrasound aspect of the kidneys, and the presence of hypertensive neuro-retinopathy. In this context of MAH, hemolytic anemia (Hemoglobin up to 6.2 g/dl, LDH 750 U/L, Haptoglobin 0.08 g/L), and azotemic retention raised suspicion of aHUS. In this context, tests were collected to evaluate complement fractions.

Since ADAMTS 13 activity is low (43%), but not deficient, so thrombotic thrombocytopenic purpura (TTP) can be excluded. There is a marked activation of the alternative complement pathway (sC5b-9) which, in the context of malignant arterial hypertension, is suggestive of aHUS. We also note the presence of anti-factor H IgG antibodies,

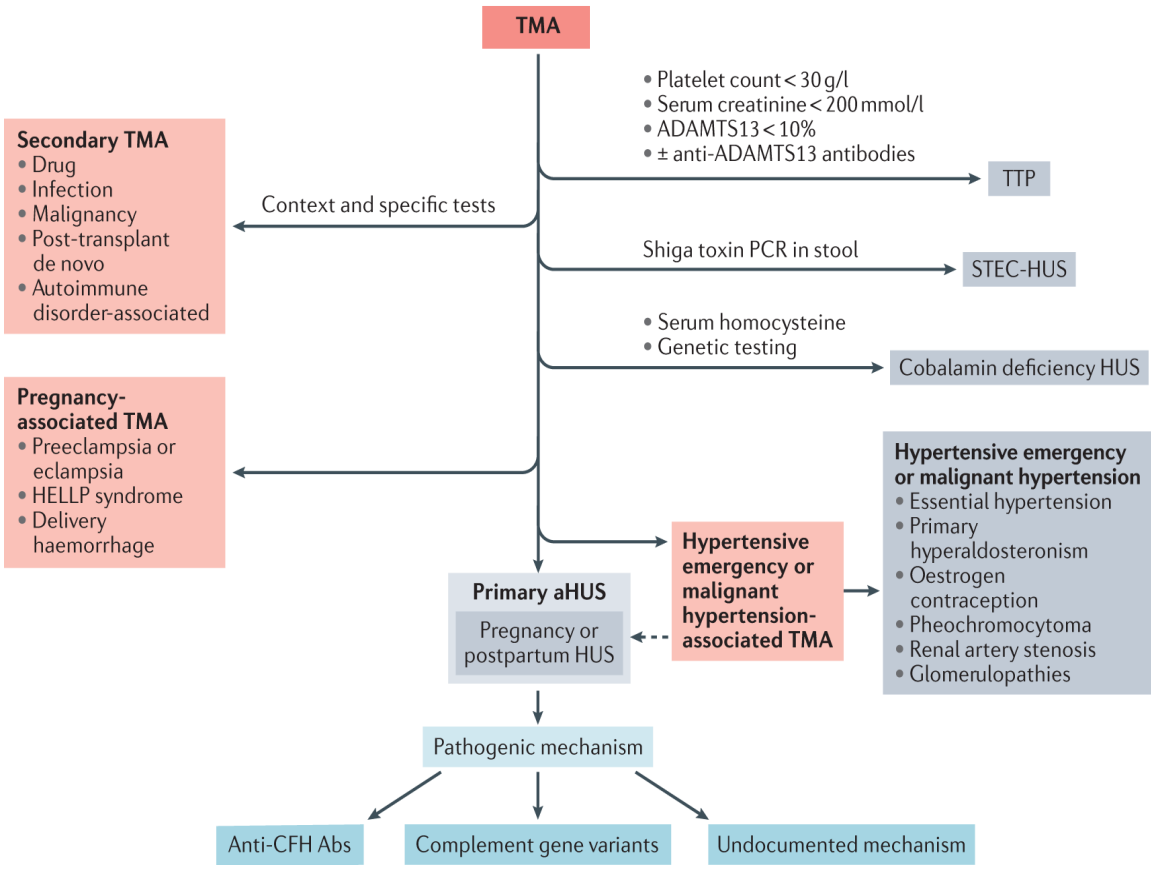

Figure 1. *Fakhouri, F., Frémeaux-Bacchi, V. Thrombotic microangiopathy in aHUS and beyond: clinical clues from complement genetics. Nat Rev Nephrol 17, 543–553 (2021).*

suggestive of complement-mediated thrombotic microangiopathy.

The patient received an initial dose of 900 mg Eculizumab and started maintenance treatment with Eculizumab. Hemoglobin stabilized around 8 g/dl, with a reduction in LDH values to 500 U/L.

Since the patient resumed diuresis, but insufficiently (diuresis 400-700ml) and presented with fluid overload with dyspnea and oxygen therapy needs, we considered it necessary to include him in a chronic hemodialysis program, using a long-life tunneled central venous catheter as a permanent vascular approach in the right jugular vein. During hospitalization, the patient underwent 10 hemodialysis sessions, received 2 units of iso-group, iso-Rh erythrocyte mass (MER), antibiotic treatment (ceftriaxone 1 g/12 hours, 16 days, as prophylactic treatment for meningococcal meningitis until anti meningococcal vaccination, in the context of Eculizumab administration), probiotic, antihypertensive treatment (candesartan, nifedipine, metoprolol, clonidine, alpha-methyldopa, furosemide, nitroglycerin). Anti meningococcal vaccination was performed for serogroups A, C, and B. According to recommendations and studies, the patient remained on chronic Eculizumab treatment of 1200mg every 2 weeks. The patient was enrolled on the waiting list for renal transplant.

Following the treatment with Eculizumab, the evolution shown in Figure 2 was observed.

Discussion

Currently, the standard treatment with eculizumab is 1200 mg every 2 weeks for the entire duration of life[8,9], with the European Medicines Agency (EMA) and the Food and Drug Administration (FDA) drawing attention to the risk of discontinuing the treatment[9-11].

In this case, we can observe that treatment with eculizumab has brought significant benefits in the hematological area by increasing hemoglobin and platelet counts. After 18 months of treatment, the values are as follows: hemoglobin 10.4 mg/dl and platelet count 271,000. Extending the dosing interval or reducing the dose seems not to have had a negative impact on the platelet count, as they always remained within the reference range. However, the hemoglobin value decreased to 8.2 g/dl with only 1200 mg every 4 weeks, returning to normal values (12-13 g/dl) following the protocol (1200 mg every 2 weeks). Although all guidelines specify initiating eculizumab treatment as soon as the diagnosis of atypical hemolytic uremic syndrome (aHUS) is established, the recommended duration of treatment, monitored parameters, dose adjustments based on these parameters, and the continuation of treatment after renal transplantation remain questionable. This is especially due to the high cost of treatment and the risk of adverse effects, particularly the increased risk of infections (meningococcal meningitis and sepsis with Gram-negative bacilli).

Therefore, regarding dose adjustment, monitoring the serum eculizumab level is not opportune. Instead, it has been proposed to monitor the pharmacodynamic effect by measuring the total complement activity expressed as CH50.

Ardissino and colleagues reported that a median dose of 0.75 mg/kg/day of Eculizumab was sufficient to block complement activity for up to 4 weeks[12], while the recommended dose is 1.2 mg/kg/day. Additionally, Gatault and colleagues developed a model to predict the pharmacokinetics and pharmacodynamics of Eculizumab using data from seven patients. Following their model, it might be possible to extend the interval to 4 weeks for patients weighing less than 90 kg and even to 6 weeks for patients with a body weight below 70 kg[13].

Although the above studies have focused on completely blocked complement activity (CH50 < 10%), various studies have reported remissions without relapses in patients treated with Eculizumab at extended intervals and with an incompletely blocked complement system. Therefore, complete complement blockade is not necessary[14]. Consequently, even with incomplete

Parameter	Results	Normal Range
ADAMTS13	43 %	67 – 150 %
Total complement activity, classical pathway	102 CH50/ml	48 – 103 CH50/ml
Total complement activity, alternative pathway	102 %	70 – 125 %
Complement C3	1.2 g/L	0.9 – 1.8 g/L
Complement C4	0.37 g/L	0.15 – 0.55 g/L
Factor H antigen	762 mg/L	250 – 880 mg/L
Complement factor I antigen	112 %	70 – 130 %
Complement factor B antigen	175 %	70 – 130 %
Anti- factor H IgG autoantibody	146 AU/ml	< 100 AU/ml
C1q antigen	106 mg/L	60 -180 mg/L
Anti-C1q IgG autoantibody	45 U/ml	<52 U/ml
C3-Nephritic factor	6.4 %	<10 %
sC5b-9 (terminal complement complex)	451 ng/ml	110 – 252 ng/ml

Table 2. *Complement evaluation (Semmelweis University, Dept of Internal Medicine and hematology, Research Laboratory, Prof. Dr. Zoltan Prohaszka)*

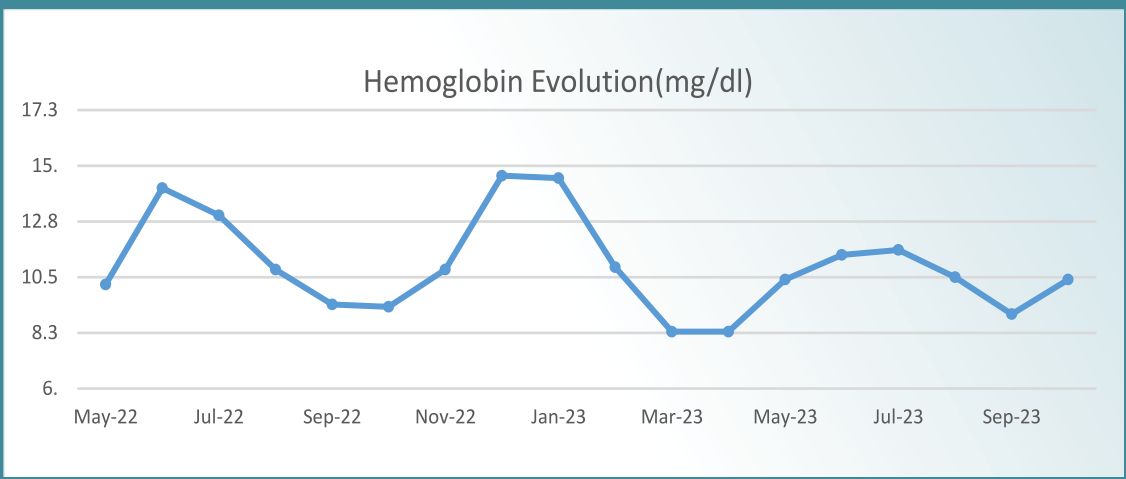

Figure 2. *Hematological evolution under Eculizumab treatment*



complement blockade, remission can be maintained without relapse with lower doses or longer intervals.

Other parameters have also been proposed for monitoring, such as C3, C3d, C5, C5a, soluble C5b-C9, ex vivo testing for endothelial cells, and alternative pathway activity (AP50), but these have yielded inconclusive results[15-18].

Regarding anti-complement therapy, the optimal duration of treatment is not yet known.

Studies suggest that treatment may be discontinued in carefully selected patients after the disease has entered remission, taking into consideration the risk of relapse. Generally, discussions about discontinuing therapy arise once renal function has normalized or stabilized. The likelihood of therapy discontinuation is higher in patients without pathogenic mutations in the CFH, CFI, CFB, MCP, or C3 genes. Patients with such mutations have a higher risk of relapse. For patients with mutations of uncertain significance (VUS) in these genes, the decision to continue therapy is made based on personal or familial history of similar renal diseases. Patients with antibodies against CFH or negative genetic tests have the lowest risk of relapse[19].

A study of atypical hemolytic uremic syndrome (aHUS) registries found that among patients with identified mutations, 8 out of 11 (72%) patients with variations in factor H and 4 out of 8 (50%) patients with variations in membrane cofactor proteins experienced relapses, while none of the 16 patients without detectable mutations relapsed.

However, aggregated data from prospective studies with Eculizumab, including 61 patients, showed that in the case of patients who relapsed or did not after discontinuation of therapy, the frequency of identified complement mutations was essentially equal (58% and 49%, respectively)[18]. Without integration into a validated risk model, the prognostic value of genetic mutations and all other risk factors remains uncertain[20, 21].

Another aspect is that for those who discontinue Eculizumab therapy and experience a relapse, there is limited evidence suggesting that resuming Eculizumab therapy induces a second remission [21,22].

There is no standard approach for monitoring relapses after discontinuation of Eculizumab; an optimal strategy is to monitor hemoglobin, platelets, serum creatinine, and lactate dehydrogenase (LDH) according to the following schedule after drug discontinuation: at 2 and 4 weeks, then monthly for 6 months, and subsequently every 3-4 months[23].

In the case mentioned above, discontinuation of Eculizumab administration is not considered for several reasons. Firstly, based on the trend of hemoglobin levels, it is observed that by extending the treatment interval to 4 weeks, its value decreases to

around ~8 g/dl. Furthermore, the patient is on the waiting list for a kidney transplant. According to recent observational data from the Global aHUS Registry, patients who underwent prophylactic Eculizumab therapy before kidney transplantation had better outcomes[24].

Following KDIGO recommendations, genetic tests have been conducted. Identifying a pathogenic genetic variant in a patient with aHUS confirms the diagnosis and precisely establishes the cause of the disease, facilitating patient management and treatment optimization[25]. Studies have shown that the highest graft failure rates were in patients with CFH mutations - a 71% failure rate at 1 year[26].

According to the study conducted by Kant and colleagues, among the 10 patients treated prophylactically with Eculizumab who continued treatment after kidney transplantation, therapy was discontinued in 3 patients within 6-12 months post-grafting, considering that no mutations were detected. During the subsequent follow-up period, none of the patients developed disease recurrence. With the longest demonstrated follow-up period (a median of 40 months), their study suggests that discontinuing prophylaxis may be possible with minimal risk of recurrence in carefully selected patients without identified complement mutations[27].

Conclusion

Malignant hypertension, recently defined as a hypertensive emergency, with severe organ involvement (brain, heart, kidneys), life-threatening, represents a medical emergency requiring immediate diagnosis and treatment. From a pathogenic perspective, malignant hypertension can induce thrombotic microangiopathy, creating a clinical and biological picture similar to and difficult to differentiate from thrombotic thrombocytopenic purpura (TTP). Currently, the assessment of ADAMTS13 status and complement fractions differentiates atypical hemolytic-uremic syndrome (aHUS), complement-mediated malignant hypertension vs. TTP, allowing for accurate diagnosis and early initiation of treatment with Eculizumab, a recombinant humanized monoclonal antibody, a complement inhibitor. Treatment with Eculizumab represents a novel and valuable therapeutic approach for patients with aHUS, bringing significant benefits in the course of the disease.

However, it comes with challenges, both due to the increased susceptibility to infections and its high cost. Both challenges are exacerbated by the necessity of long-term treatment, including as a prophylactic therapy, particularly in the case of pre-renal transplant.

References

1. Fakhouri F, Zuber J, Fremeaux-Bacchi V, Loirat C. Haemolytic uraemic syndrome. Lancet. 2017;390: 681–96.

2. Campistol JM, Arias M, Ariceta G, Blasco M, Espinosa L, Espinosa M, Grinyo JM, Macia M, Mendizabal S, Praga M, Roman E, Torra R, Valdes F, Vilalta R, Rodriguez de Cordoba S. An update for atypical haemolytic uraemic syndrome: diagnosis and treatment. A consensus document. Nefrologia. 2015;35:421–47.

3. George JN, Nester CM. Syndromes of thrombotic microangiopathy. N Engl J Med. 2014;371(7):654. Atypical Hemolytic Uremic Syndrome, Last updated: February 10, 2020

4. rarediseases.org/rare-diseases/atypical-hemolytic-uremic-syndrome/

5. Puraswani M, Khandelwal P, Saini H, et al. Clinical and Immunological Profile of Anti-factor H Antibody Associated Atypical Hemolytic Uremic Syndrome: A Nationwide Database. Front Immunol 2019; 10:1282.

6. Sinha A, Gulati A, Saini S, et al. Prompt plasma exchanges and immunosuppressive treatment improves the outcomes of anti-factor H autoantibody-associated hemolytic uremic syndrome in children.



Kidney Int 2014; 85:1151.

7. Menne, J., Delmas, Y., Fakhouri, F. et al. Outcomes in patients with atypical hemolytic uremic syndrome treated with eculizumab in a long-term observational study. BMC Nephrol 20, 125 (2019). https://doi.org/10.1186/s12882-019-1314-1 As cited by Wijnsma KL et Al. Eculizumab in atypical hemolytic uremic syndrome: strategies toward restrictive use.

8. Loirat C, Fakhouri F, Ariceta G, Besbas N, Bitzan M, Bjerre A, Coppo R, Emma F, Johnson S, Karpman D, Landau D, Langman CB, Lapeyraque AL, Licht C, Nester C, Pecoraro C, Riedl M, van de Kar NC, Van de Walle J, Vivarelli M, Fremeaux-Bacchi V. An international consensus approach to the management of atypical hemolytic uremic syndrome in children. Pediatr Nephrol. 2016;31:15–39. doi: 10.1007/s00467-015-3076-8

9. Goodship TH, Cook HT, Fakhouri F, Fervenza FC, Fremeaux-Bacchi V, Kavanagh D, Nester CM, Noris M, Pickering MC, Rodriguez de Cordoba S, Roumenina LT, Sethi S, Smith RJ, Conference P. Atypical hemolytic uremic syndrome and C3 glomerulopathy: conclusions from a "kidney disease: improving global outcomes" (KDIGO) controversies conference. Kidney Int. 2017;91:539–551. doi: 10.1016/j.kint.2016.10.005.

10. Food and drug administration (2011) Approval Package for Soliris

11. European Medicines Agency (2017) Summary of product characteristics

12. Ardissino G, Tel F, Sgarbanti M, Cresseri D, Giussani A, Griffini S, Grovetto E, Possenti I, Perrone M, Testa S, Paglialonga F, Messa P, Cugno M (2017) Complement functional tests for monitoring eculizumab treatment in patients with atypical hemolytic uremic syndrome: an update. Pediatr Nephrol. 10.1007/s00467-017-3813-2

13. Gatault P, Brachet G, Ternant D, Degenne D, Recipon G, Barbet C, Gyan E, Gouilleux-Gruart V, Bordes C, Farrell A, Halimi JM, Watier H. Therapeutic drug monitoring of eculizumab: rationale for an individualized dosing schedule. MAbs. 2015;7:1205–1211. doi: 10.1080/19420862. 2015.1086049.

14. Wijnsma KL, Duineveld C, Wetzels JFM, van de Kar NCAJ. Eculizumab in atypical hemolytic uremic syndrome: strategies toward restrictive use. Pediatr Nephrol. 2019 Nov;34(11):2261-2277. doi: 10.1007/s00467-018-4091-3. Epub 2018 Nov 6. Erratum in: Pediatr Nephrol. 2019 Jan 15;: PMID: 30402748; PMCID: PMC6794245

15. Volokhina E, Wijnsma K, van der Molen R, Roeleveld N, van der Velden T, Goertz J, Sweep F, Bruggemann RJ, Wetzels J, van de Kar N, van den Heuvel L. Eculizumab dosing regimen in atypical HUS: possibilities for individualized treatment. Clin Pharmacol Ther. 2017;102: 671–678. doi: 10.1002/cpt.686.

16. Puissant-Lubrano B, Puissochet S, Congy-Jolivet N, Chauveau D, Decramer S, Garnier A, Huart A, Kamar N, Ribes D, Blancher A. Alternative complement pathway hemolytic assays reveal incomplete complement blockade in patients treated with eculizumab. Clin Immunol. 2017;183:1–7. doi: 10.1016/j. clim.2017. 06.007.

17. Wehling C, Amon O, Bommer M, Hoppe B, Kentouche K, Schalk G, Weimer R, Wiesener M, Hohenstein B, Tonshoff B, Buscher R, Fehrenbach H, Gok ON, Kirschfink M. Monitoring of complement activation biomarkers and eculizumab in complement-mediated renal disorders. Clin Exp Immunol. 2017;187:304–315. doi: 10.1111/cei.12890.

18. Noris M, Galbusera M, Gastoldi S, Macor P, Banterla F, Bresin E, Tripodo C, Bettoni S, Donadelli R, Valoti E, Tedesco F, Amore A, Coppo R, Ruggenenti P, Gotti E, Remuzzi G. Dynamics of complement activation in aHUS and how to monitor eculizumab therapy. Blood. 2014;124:1715–1726. doi: 10.1182/blood-2014-02-558296.

19. www.uptodate.com

20. Macia M, et al: Current evidence on the discontinuation of eculizumab in patients with atypical haemolytic uraemic syndrome. Clin Kidney J 2017; 10: 310–319.

21. akhouri F, et al: Pathogenic variants in complement genes and risk of atypical hemolytic uremic syndrome relapse after eculizumab discontinuation. Clin J Am Soc

Nephrol 2017; 12: 50–59.
22. Cugno M, et al: Complement functional tests for monitoring eculizumab treatment in patients with atypical hemolytic uremic syndrome. J Thromb Haemost 2014; 12: 1440–1448.
23. Sven R. Olson, Eric Lu, Emilio Sulpizio, Joseph J. Shatzel, Jose F. Rueda, Thomas G. DeLoughery; When to Stop Eculizumab in Complement-Mediated Thrombotic Microangiopathies. Am J Nephrol 22 August 2018; 48 (2): 96–107.
24. Siedlecki AM, Isbel N, Vande Walle J, James Eggleston J, Cohen DJ. Eculizumab use for kidney transplantation in patients with a diagnosis of atypical hemolytic uremic syndrome. Kidney Int Rep. 2019;4(3):434–46. https://doi.org/10.1016/j.ekir.2018.11.010.
25. Timothy H.J. Goodship1 , H. Terence Cook2 , Fadi Fakhouri3 , Fernando C. Fervenza4 , Ve´ronique Fre´meaux-Bacchi5 , David Kavanagh1 , Carla M. Nester6,7 , Marina Noris8 , Matthew C. Pickering2 , Santiago Rodrı´guez de Co´rdoba9 , Lubka T. Roumenina10,11,12, Sanjeev Sethi13 and Richard J.H. Smith: Atypical hemolytic uremic syndrome and C3 glomerulopathy: conclusions from a "Kidney Disease: Improving Global Outcomes Kidney International (2017) 91, 539–551; http://dx.doi.org/ 10.1016/ j.kint. 2016.10.005
26. Noris M, Caprioli J, Bresin E, et al. Relative role of genetic complement abnormalities in sporadic and familial aHUS and their impact on clinical phenotype. CJASN. 2010;5(10). https://doi.org/ 10.2215/ CJN. 02210310.
27. Kant, S., Bhalla, A., Alasfar, S. et al. Ten-year outcome of Eculizumab in kidney transplant recipients with atypical hemolytic uremic syndrome– a single center experience. BMC Nephrol 21, 189 (2020). https://doi.org/10.1186/s12882-020-01847-0