sciendo

DOI: 10.2478/fv-2023-0026

FOLIA VETERINARIA, 67, 3: 39—48, 2023

PINEALOCYTES AND GLIA CELLS IN THE PINEAL GLAND OF THE AFRICAN STRAW-COLOURED FRUIT BAT (*EIDOLON HELVUM*)

James O. Olopade[1], Olumayowa O. Igado[1], Marvellous A. Adesina[1], Rachael O. Folarin[2], Adedunsola A. Obasa[1]

[1]Department of Veterinary Anatomy, University of Ibadan, Ibadan
[2]Department of Biomedical Laboratory Science, College of Medicine, University of Ibadan, Ibadan
Nigeria

mayowaigado@yahoo.com

ABSTRACT

The mammalian pineal gland is a structure that in recent years has been extensively studied, due to its functions and the hormones it produces. Bats are the only known flying mammals, with the order having a large number of species. This study was carried out to investigate the gross and histological features of the pineal gland of the *Eidolon helvum*, the African fruit bat, using male and female subjects. Eight free flying *E. helvum* (4 males, 4 females) were captured using mist nets. The pineal gland was grossly observed to be very small in size, oval in shape, and covered by the pia mater. Histological examination revealed two populations of pinealocytes – Types I and II – oval structures possessing acidophilic cytoplasm and large, round nuclei. Pinealocytes were seen to appear singly or in clusters, having no particular arrangement. Sexual dimorphism was observed, with the females having less density in population of pinealocytes at the peripheral region of the gland. This was consistent in all subjects examined. Astrocytic appearance was typical with long and slender processes, and perivascular and capsular microglia were observed. The glia cells were observed to be abundant in the parenchyma and around the capsule. There was no sensitivity to NeuN antibody. Results obtained may find application in behavioural and comparative neuroscience.

Keywords: African fruit bat; astrocytes; *Chiroptera;* microglia; neuroanatomy; pineal gland; pinealocytes

INTRODUCTION

Bats, order *Chiroptera*, are the most abundant mammals and they form the biggest mammalian aggregation [15]. Bats are the only actively flying mammalian species with the capacity of echolocation. There are two sub-orders: *Megachiroptera* and *Microchiroptera* [9, 12, 13]. Pteropodids are mostly nocturnal mammals with an alternating circadian and photoperiodic system interphase. The *Eidolon helvum*, a member of the Pteropodidae family, is

not necessarily a nocturnal bat though it feeds at night. It is also called the straw-coloured fruit bat due to the silky yellowish colour of its exterior with black wings and a pale back hair [6, 11]. During the day, they rest and move among the colony. About 15 % of bats have been classified as being endangered or vulnerable by the International Union for Conservation of Nature Red list, due to a declining population [23].

The epithalamus is a subdivision of the diencephalon, located in the region of the posterior commissure that consist of the pineal gland and the habenular nuclei [1]. Embryologically, the pineal gland is an evagination of the diencephalic roof situated between the cerebral hemispheres and it is attached by a stalk to the roof of the third ventricle and bordered bilaterally by the rostral colliculi [1]. Virtually, all vertebrates possess a pineal organ. The pineal gland is associated with biorhythms, acting as an interface between the cyclic and the rhythmic vertebrate body. This results from the secretion of melatonin by the pineal gland. It is composed of cells called pinealocytes and cells of the nervous system called glial cells [14]. The pineal gland is attached to the brain at a region called the habenular nucleus [22]. The habenular comprises a small group of nuclei connecting the forebrain and midbrain within the epithalamus of the brain. It is divided into two asymmetric halves; the medial habenular and the lateral habenular**.** The medial and lateral nuclei are connected to each other, by the habenular commissure [20].

Justification for current research

In spite of the number of growing publications on the anatomy of the *Eidolon helvum* in recent years, careful electronic search at the time of this write-up did not reveal any stating the cell architecture of the pineal gland and the presence of any sexual dimorphism. This study aims to give an anatomical description, both gross and histological, of the pineal gland of the *Eidolon helvum*.

MATERIALS AND METHODS

Capture of experimental animals (bats)

Eight free flying bats (4 males and 4 females) were captured using mist nets set up along the flight path of the bats around known feeding areas between 6 pm and 10 pm. The nets with lengths ranging from 6 to 12 meters and a height of 3 to 6 meters, were tied to poles. The nets were checked every 10 minutes with infrared head lamps. Bats caught were carefully removed before being placed individually in a cloth holding-bag with a draw string closure for immediate transportation to the laboratory for species identification and sacrifice. Eight animals in total (4 males and 4 females) were used because *E. helvum* is classified as Near Threatened on the IUCN Red list [7] and they need to be conserved.

Identification of bats

Bat species were identified using external features. The fur of the African straw-coloured fruit bats has a yellow tinge and nearly always with an orange collar of fine textured hair (varying from very bright to rather indistinct), which usually extends round the back of the neck as well as the throat. They also possess a muzzle that tapers towards the nostrils. The sex of each bat was recorded.

Sacrifice

The bats were anaesthesized using a xylazine-ketamine combination of 10 $mg.kg^{-1}$ and 90 $mg.kg^{-1}$ respectively [2]. After confirming cessation of breathing and loss of response to tactile stimuli, the bats were perfused transcardially first with 0.9 % physiological saline, and next with 10 % buffered formalin (pH 7.4). The whole brain was harvested from the skull with the leptomeninges intact and immediately post-fixed in 10 % neutral buffered formalin for about 5 days. Prior to histological processing, gross structures of the brain were observed and captured. The brain was trimmed just immediately cranial to the pineal gland in the region of the *striae medullaris* and processed for histological staining. Thereafter, serial sections in coronal plane of 5 µm thickness were cut on a microtome, mounted on gelatin treated frosted end slides after floating on warm bath. The slides were oven dried for 1½ hrs and routinely stained with haematoylin and eosin (H&E). The same cutting procedure was repeated using a super frosted slide, oven dried and stained using cresyl violet [8].

Immunohistochemistry

The brains were prepared for immunohistochemistry following the protocol described by Usende et al. [21]. Briefly, the 5 µm thick brain sections were mounted on adhesive glass slides, and baked in an oven set at 60 °C for 1 hour 30 minutes to melt the wax. Deparaffinization of

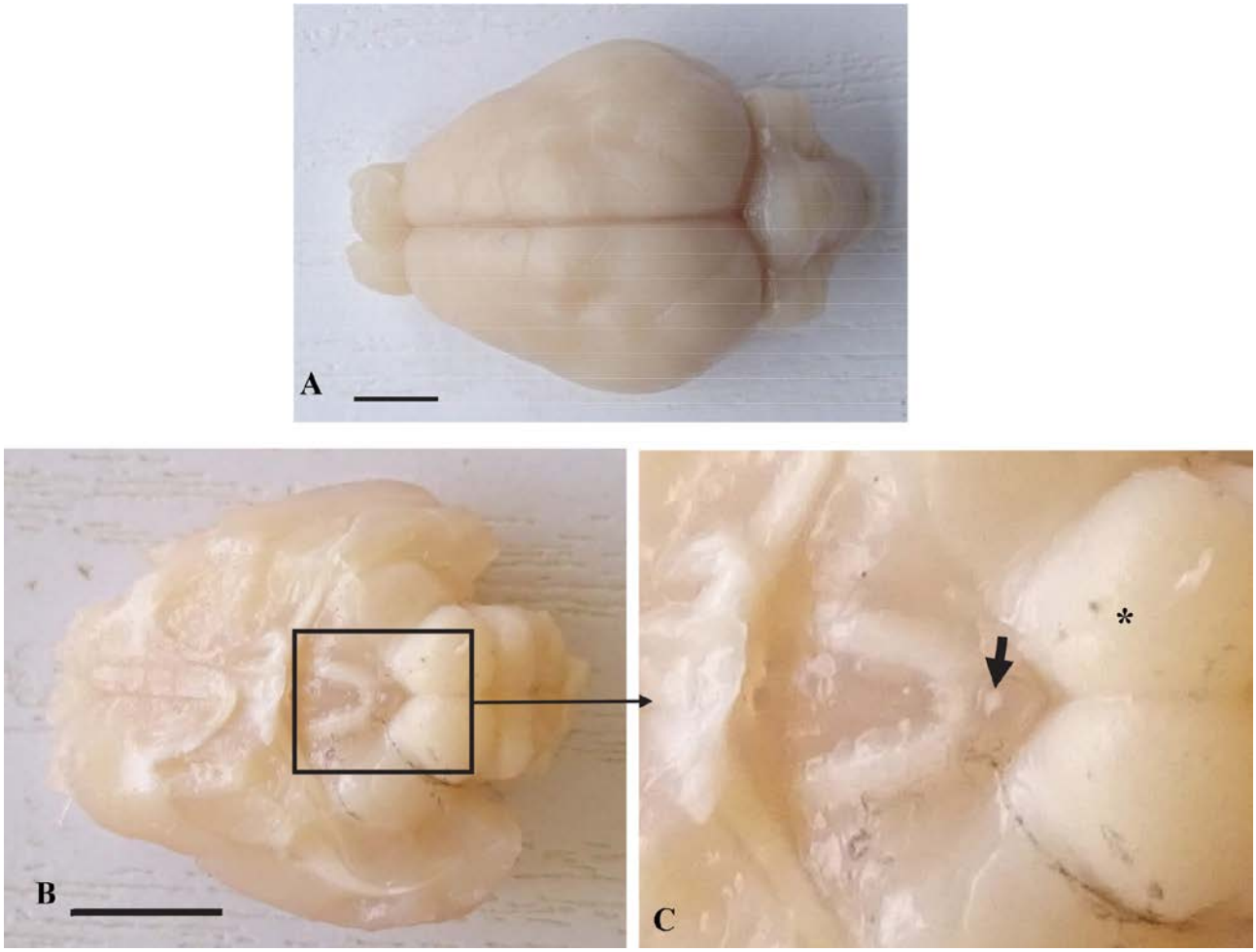

Fig. 1. Brain of the African fruit bat *(Eidolon helvum)*, dorsal view.
In **B** and **C**, part of the cerebrum had been removed to expose the pineal gland and colliculi. **C** is a magnification of boxed area in **B**. The pineal gland is depicted by the black arrow and the rostral colliculi by the asterisk. Scale bar 0.5 cm.

the sections was done in 2 changes of xylene, after which the sections were hydrated in decreasing concentration of alcohol to water. Sections were then rinsed in double distilled water before retrieval of antigen was achieved by incubating the sections in 10 mM citrate buffer at pH of 6.0 for 25 minutes to unmask the hidden antigenic site. In order to reduce non-specific antibody binding and to hinder endogenous peroxidase activities, sections were treated with 30 % H_2O_2/methanol. Sections were subsequently blocked by incubating in 2 % PBS milk while on a rocker for 60 minutes. Consecutive sections were immune-labeled with the following antibodies: rabbit anti-IBA 44 1 antibody (dilution 1:1000, Wako Pure Chemical Industries Ltd., Japan) for microglial cells, rabbit anti-glial fibrillary acidic protein (GFAP) (1: 1000; Dako, Denmark), to visualize astrocytes; rabbit anti-NeuN polyclonal antibody (dilution 1:500, EMD Millipore, USA) to visualize neurons. The antibodies were diluted in 1 % PBS milk and 0.1 % Triton X detergent (to facilitate quick penetration of antibody) and the samples underwent incubation over night at 40 °C. HRP-conjugated secondary antibodies were subsequently used following manufacturer's protocol (dilution 1:200, Abcam Inc, USA) to detect the bound antibody. The end product of entire reaction was improved with 3, 3'- diaminobenzidine a chromogen (1:25 dilution, Victor Laboratories, USA) for 5 minutes. Subsequently, sections were dehydrated in solutions of graded alcohol concentration, and alcohol removed by passing through two changes of xylene (5 minutes each), then mounted wet in permount (toluene based mountant, Atom Scientific, Manchester), cover slipped and allowed to dry. Microscopic examination was carried out using LEICA DM 500 microscope.

Pinealocytes observed were classified into dark and light based on appearance according to previous reports [4, 16–18].

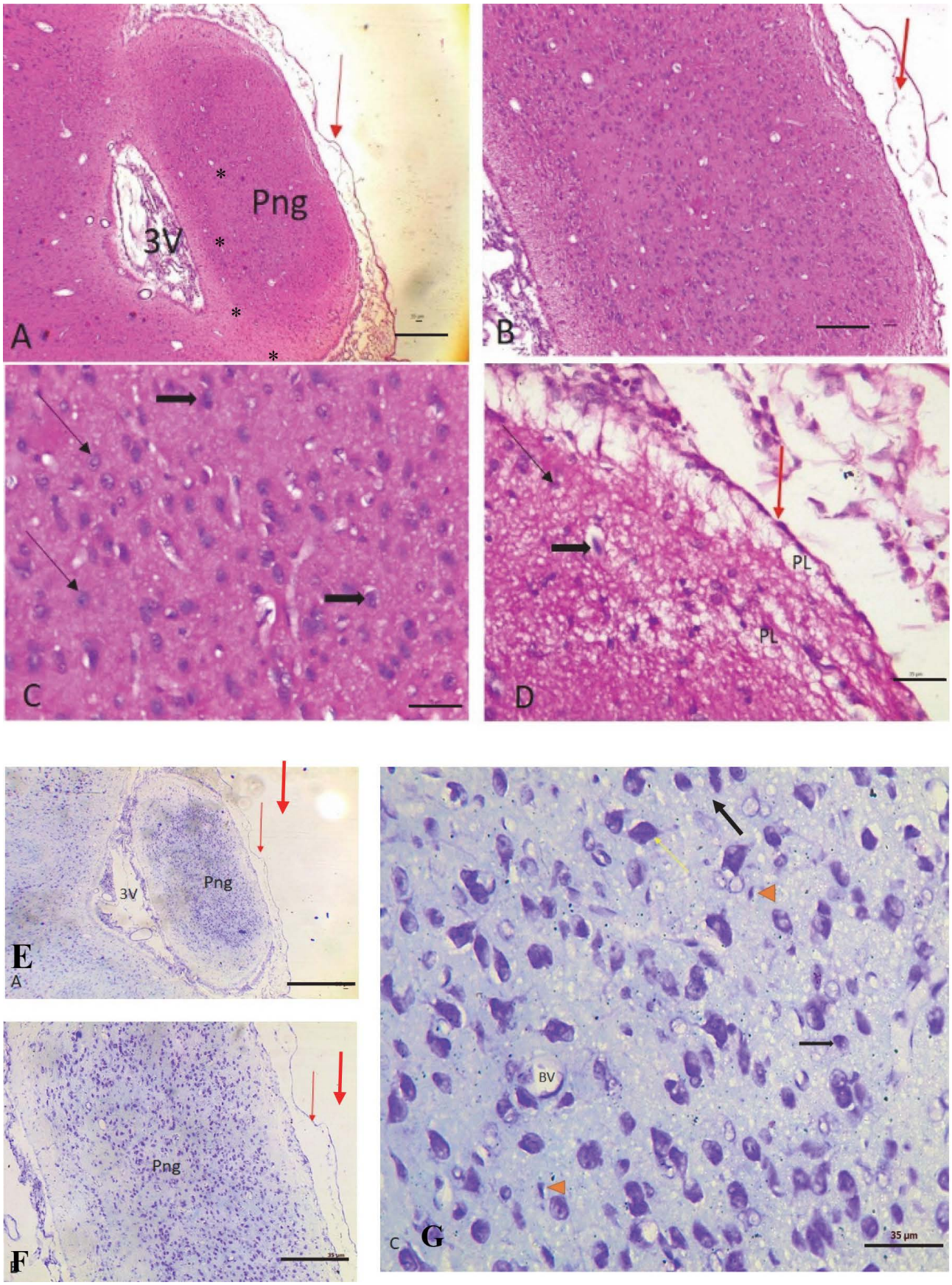

Fig. 2. Photomicrograph of the pineal gland of the female fruit bat, H & E (A – D), Cresyl violet (E – G).
A and **E** – Entire coronal section of pineal gland (Png) seen above the third ventricle (3V); **B** and **F** – Gland parenchyma showing pia capsule (red arrow); **C**, **D** and **G** – Pineal parenchyma showing the dark pinealocytes (long black arrows) and light pinealocytes (short black arrows). **F** – shows an astrocyte (arrow heads). The asterisks (*) in A is used to trace the condensation of cells, not seen in the male bat. Scale bar – 385 µm (**A** and **E**), 150 µm (**B** and **F**), 20 µm (**C** and **D**), 35 µm (**G**).

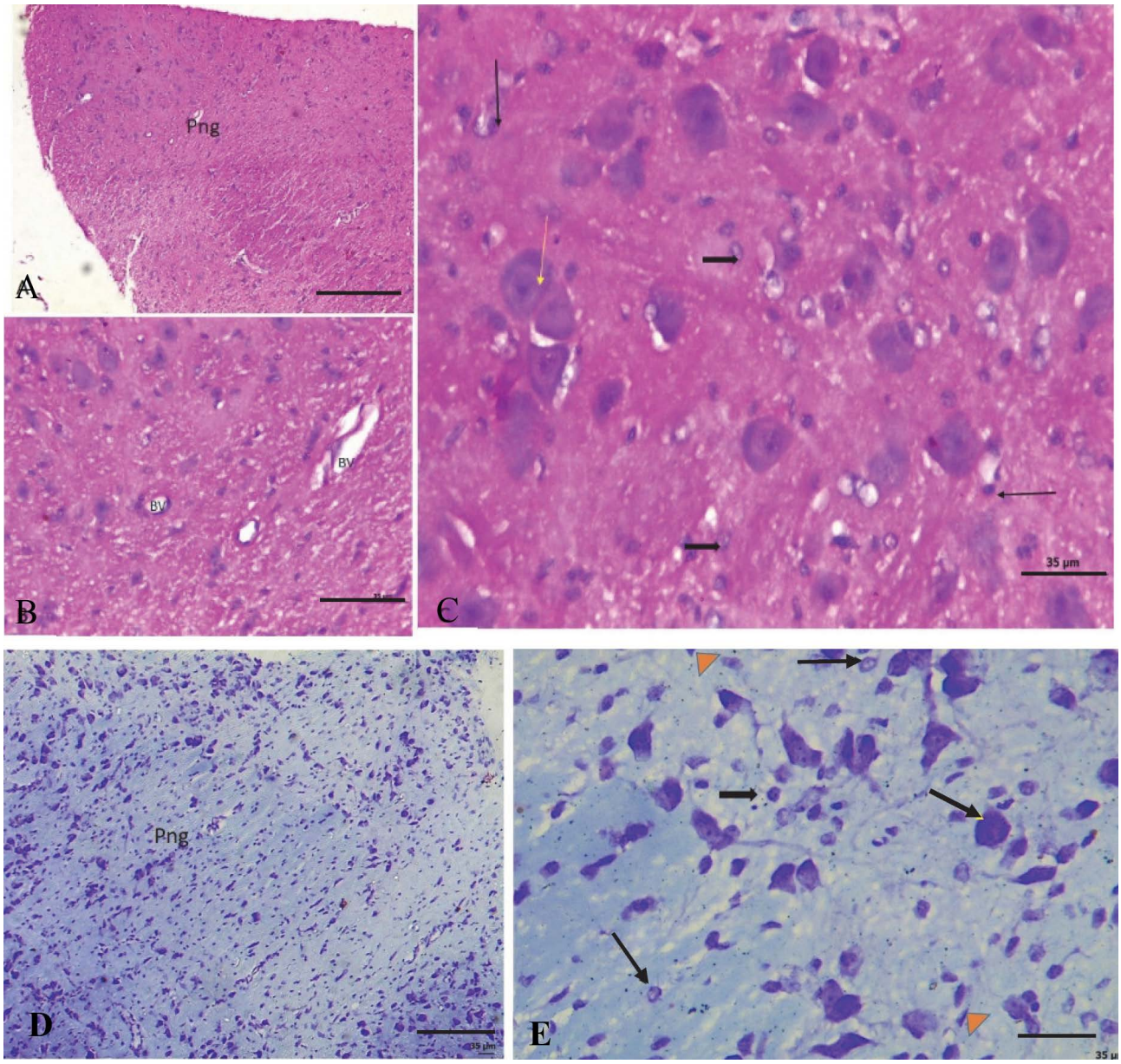

Fig. 3. Photomicrograph of the pineal gland of the male fruit bat, H & E (A – C), Cresyl violet (D and E).
A – Entire coronal section of pineal gland (*Png*) seen above the third ventricle (3V); **B** and **D** – Gland parenchyma, blood vessels (BV) are seen in **B**; **C** and **D** – Pineal parenchyma showing the dark pinealocytes (long black arrow), light pinealocytes (short black arrows) and astrocytes (arrow heads). Scale bar – 150 µm (**A** and **D**), 60 µm (**B**), 35 µm (**C** and **E**).

Ethical considerations

Ethical approval for this study was obtained from the Animal Care and Use Research Ethics Committee, of the University of Ibadan, Nigeria, with ethical code UI-ACUREC/App/2016/015. All bats were humanely handled.

RESULTS

The pineal gland of the fruit bat was observed to be very small, being a single rounded body about 2.1 mm in size and spherical in shape. It was situated immediately cranial to the rostral colliculi, along the midline; part of the cerebrum had to be removed to reveal the pineal. It had a creamy white colour after perfusion (Fig. 1). It should however be noted that the animals were perfused post-euthanasia, prior to dissection. This may probably affect the colour, but to little degree.

H and E and cresyl violet stains

Histological staining with H and E and cresyl violet revealed the pineal gland to be surrounded by a thick fibrous connective tissue capsule of pia matter (Figs. 2 and 4). The

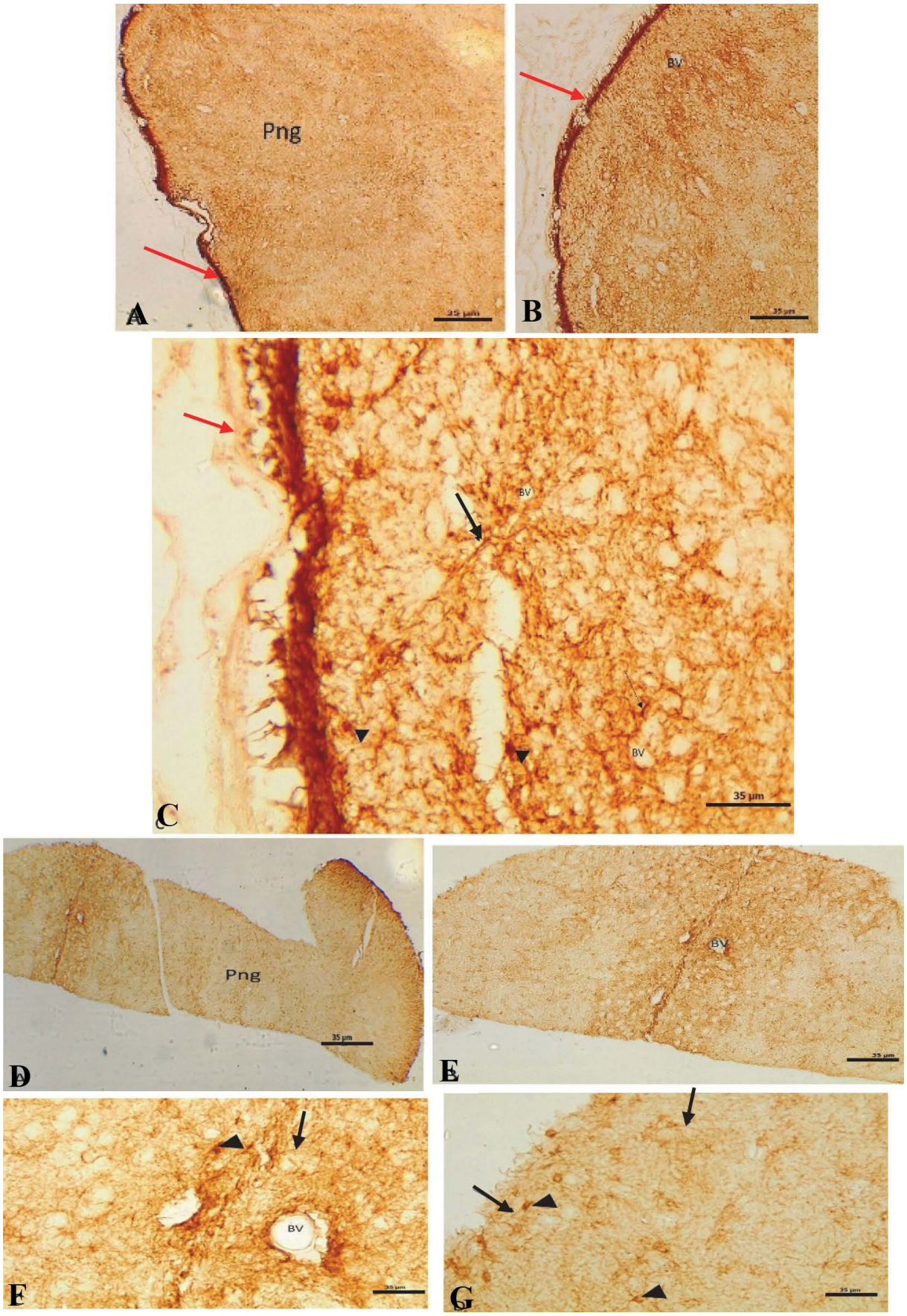

Fig. 4. Photomicrograph of the pineal gland of the female (A – C) and male (D – G) fruit bat showing immunoreactivity to GFAP. **A** and **D** – entire coronal section of pineal gland (Png) and pia capsule (red arrows); **B** and **E** – Gland parenchyma showing blood vessel (BV); **C**, **F** and **G** – Pineal parenchyma showing astrocytic cells (arrow heads) with their long and slender processes (long black arrow). Scale bar – 105 µm (**A** and **B**), 35 µm (**C**, **F** and **G**), 70 µm (**D**), 140 µm (**E**).

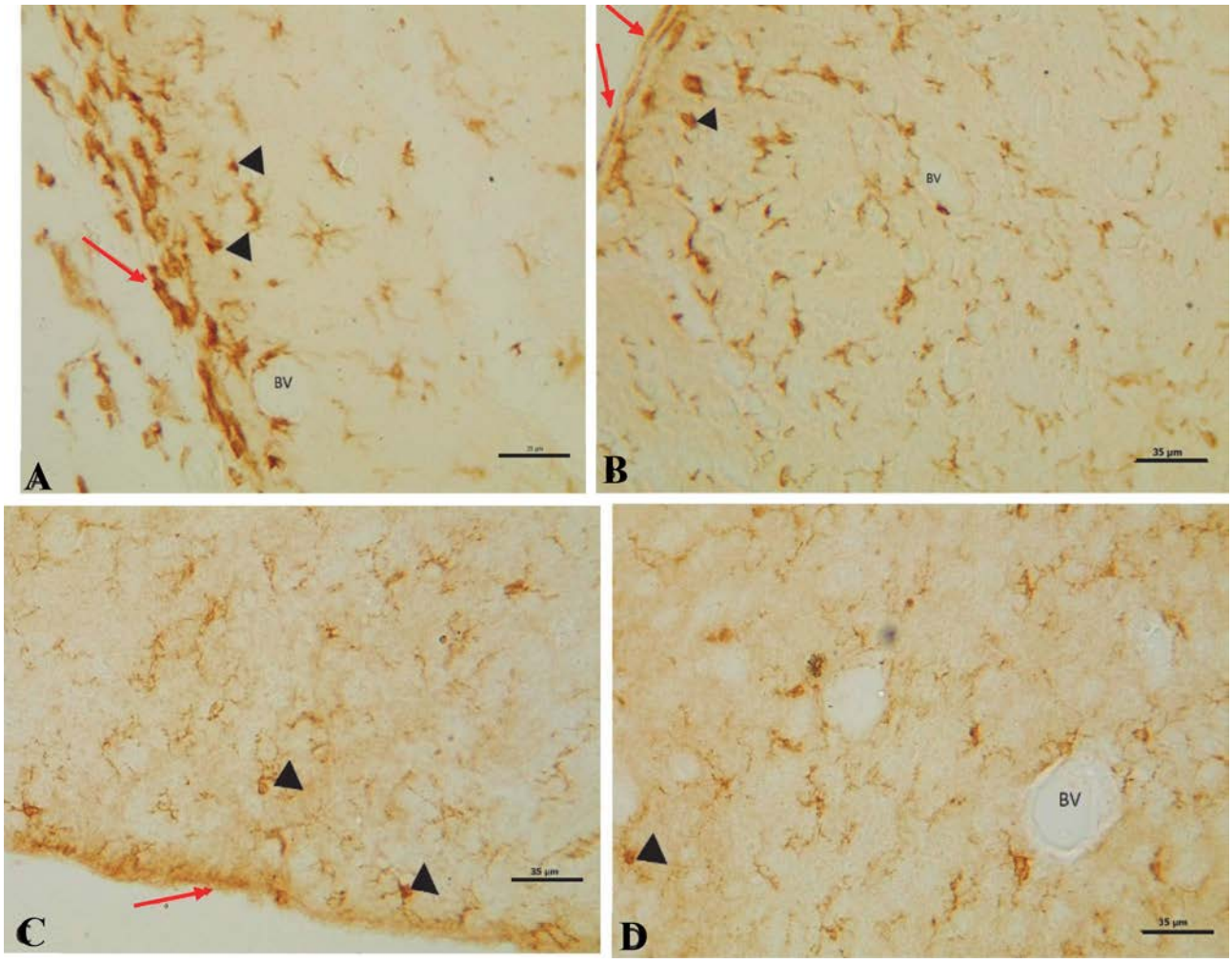

Fig. 5. Photomicrograph of the pineal gland of the female (A and B) and male (C and D) fruit bat showing immunoreactivity to IBA1.
A – Gland parenchyma showing expression of perivascular microglia around the blood vessel (BV); **B**, **C** and **D** – Pineal showing microglia expression in parenchyma (arrow heads) and pia capsule (red arrows). Scale bar – 35 µm for all micrographs.

pinealocytes appeared as round to oval shaped cells with a clear, abundant and acidophilic cytoplasm, and a large round nucleus (Figs. 2 and 3). Two categories of pinealocytes were observed: Type I being the light pinealocytes (possessing a lightly stained cellular content), and Type II being the dark pinealocytes (possessing a dark stained cellular content). The female bat pineal appeared less dense (pinealocyte-wise) at the periphery than within the parenchyma, a feature not observed in the male pineal (Figs. 2 and 3). In addition, „immediately inward" to the periphery, there was a line of condensation of cells (Fig. 2A) which was not seen in the males (Figure 3A). The arrangements of the pinealocytes did not follow a particular pattern. The blood supply of the gland occurred principally via the trabeculae of the connective tissue, where the majority of blood vessels were found (Fig. 3).

Immunohistochemical examination

Glial fibrillary acidic protein (GFAP): The pineal was densely populated with astrocytes, in both the male and the female, having the characteristic appearance, with the long and slender processes being distinct within the parenchyma, below the pia capsule and around the blood vessels (Fig. 4).

Iba1: Iba1 immunoreactivity in the pineal gland of the African fruit bat showed the expression of perivascular microglia round the blood vessel and capsular microglia in the pial capsule of the pineal gland (Fig. 5).

NeuN: The pinealocytes in the AGCR pineal gland had no immunoreactivity to NeuN antibody (Fig. 6).



Fig. 6. Photomicrograph of the pineal gland of African fruit bat showing immunonegativity to NeuN antibody staining. BV indicates blood vessel.
Scale bar – 35 µm.

DISCUSSION

The *Chiroptera* (bats) are one of the most widely distributed and diverse group of mammals, with well over a thousand species. They are the only flying mammals, and also have a very wide range of feeding habits, roosting and social behaviours, and varied reproductive strategies [5]. They are seasonal breeders, roosting under varied conditions, from broad daylight, to total darkness, depending on the species [4]. These are some of the characteristics that make studying the pineal gland in the *Eidolon helvum* interesting.

Documented reports show varied sizes and gross appearance of the pineal in diverse bat species. This study showed the shape of the pineal gland in the *Eidolon helvum* to be spherical in shape, contrary to what was described in the *Rhinopoma microphyllum*, as oval, thin and antero-posteriorly flattened [3], whereas, in some species, the pineal was classified as being rudimentary (*Lonchophylla thomasi* and *Carollia perspicillata*), in some, could not be located (*Rhinonycteris aurantius* and *Triaenops persicus*), and so, were speculated to be either absent, or to consist of cell clusters which are diffusely arranged, making gross identification impossible [4]. Interestingly, some other Microchiroptera (*Peropteryx macrotis, Rhinolophus trifoliatus, Pipistrellus imbricatus, Tadarida mops*) examined showed relatively large pineal glands, superficially located and visible from the dorsal aspect of the brain, without the removal of any structure [4], contrary to this study where the cerebrum had to be partially removed to expose the pineal. However, grossly, the pineal gland observed in this study is generally consistent with the report of Bhatnagar et al. [4] that the gland is either round, conical or oval and is closely related to the 3rd ventricle. Therefore, the pineal gland of *E. helvum* can be classified as type A according to the Vollrath [24]. This was also consistent with a study of 191 bats with 47 Pteropodids where the pineal gland was either a Type A or Type AB [3].

Histologically, the parenchyma did not show a clear-cut 'dorsal-ventral' demarcation of cellular arrangement, as clearly defined in some other bats by Bhatnagar et al. [4], but nonetheless, there was a difference in cellular arrangement, with the periphery being less dense. In addition, our study revealed some sexual dimorphism with the cellular arrangement observed.

The pinealocytes are the major cellular component of the mammalian pineal gland, comprising about 90 % of all the cells, with glial cells also reported to occur in varying numbers [10]. Two types of pinealocytes are documented to be present in the pineal gland. The two types of pinealocytes observed were consistent with previous reports [17, 18]. The pinealocytes in bats reportedly present singly or in form of irregular cords or clusters [4]. However, observations from this study highlighted pinealocyte presenting more singly and with few clusters.

As of the time of writing this article, careful electronic search using Google Scholar and Pubmed (NIH) did not reveal any previous descriptive study on the bat brain using GFAP and/or IBA1 staining. Articles describing the glia cells used electron microscopy.

Astrocytic glia cells have a range of functions that indicate that they are involved in practically everything the brain does, varying from normal to pathological functions. Some of these functions include regulation of synaptic activity, synaptogenesis, neurogenesis, homeostasis, energy provision, ammonium detoxification, to mention just a few [19].

Previous reports assessing the glial cells in bats (pipistrelle bat) described glial cells as few and dispersed [18]. This description could not be said to be the same in this study, as the astrocytes and microglia were observed to be abundant in the capsular region and the parenchyma. The presence of these glia cells was observed in all the pineal glands harvested in this study. These bats were captured as free-ranging bats, travelling over quite long distances,

and exposed to the elements. It is understandable to have an appreciable presence of glia cells in the brain regions.

The absence of immunoreactivity to the anti-NeuN antibody, which specifically identifies the DNA-binding, neuron-specific protein NeuN, will need further investigation, as neurons are known to definitely be present in the pineal gland.

CONCLUSIONS

The pineal gland is associated with the circadian rhythm, which makes it an interesting study in nocturnal animals like the bat. In free-ranging migratory bats, elucidation of the histoarchitecture of the pineal may help to better understand the nocturnal habits of these species. In conclusion, this study highlights the presence of the two pinealocytes (light and dark) in the African straw-coloured bat, and the distribution of two types of glia cells – the astrocytes and the microglia. Further research will shed more light on the characteristics of the cells identified, highlight the presence of other cells in the pineal gland, and also give better understanding to the reason for the sexual dimorphism observed in the arrangement of the pinealocytes.

ACKNOWLEDGEMENTS

The authors gratefully acknowledge the support and partial funding of this study by the Cambridge Alborada and Humboldt Linkage grants to JOO.

Conflict of interest

The authors declare there are no conflicts of interest.

REFERENCES

1. **Afifi, A. K., Bergman, R. A., 2005:** *Functional Neuroanatomy: Text and Atlas*. 2nd edn., Lange Medical Books, McGraw Hill, 494 pp.
2. **Aina, O. O., Olude, M. A., Olopade, F. E., Balkema-Buschmann, A., Groschup, M. H., Ulrich, R., Olopade, J. O., 2020:** A possible case of renal oxalate deposit reported in an African fruit bat (*Epomops franqueti*). *Int. J. Vet. Sci. Med.,* 8, 1, 56–58, DOI: 10.1080/23144599.2020.1807816.
3. **Bhatnagar, K. P., 1994:** Skeletal muscle in the pineal gland of the bat, *Rhinopoma microphyllum*: An ultrastructural investigation. *J. Anat.,* 184, 171–176.
4. **Bhatnagar, K. P., Frahm, H. D., Stephan, H., 1986.** The pineal organ of bats: A comparative morphological and volumetric investigation. *J. Anat.,* 147, 143–161.
5. **Danmaigoro, A., Onu, J. E., Sonfada, M. L., Umaru, M. A., Oyelowo, F. O., 2014:** Histology and histometric anatomy of the male reproductive system of bat (*Eidolon helvum*). *J. Histol.,* 2014, 1–6, Article ID 8347356. DOI: 10.1155/2014/358158.
6. **Freeman, P. W., 1998:** Form, function, and evolution in skulls and teeth of bats. *Pap. Nat. Resour.,* 1–19.
7. **GBIF Secretariat, 2022:** *Eidolon helvum* (Kerr, 1792). Available at https://www.gbif.org >species.
8. **Igado, O. O., Andrioli, A., Azeez, I. A., Aina, O. O., Glaser, J., Stopper, H., Holzgrabe, U., Bentivoglio, M., Olopade, J. O., 2020:** Ameliorative effect of mimo2 (a novel compound from *Moringa oleifera* leaves) against vanadium-induced neurotoxicity. *IBRO Reports* 9, , 164–182, DOI: 10.1016/j.ibror.2019.09.043.
9. **Igado, O. O., Omobowale, T. O., Ajadi, R. A., Nottidge, H. O., 2015:** Gross morphometric studies on the tongue, buccal cavity and hard palate of the fruit bat (*Eidolon helvum*). *J. Vet. Med. Ser. C Anat. Histol. Embryol.,* 44, 4, 283–287, DOI: 10.1111/ahe.12138.
10. **Karasek, M., Reiter, R. J., 1992:** Morphofunctional aspects of the mammalian pineal gland. *Microsc. Res. Tech.,* 21, , 136–57.
11. **Kerr, R., 1792:** The animal kingdom. Class I. Mammalia. Creech, W., Edinburg. In *Eidolon helvum*. *Mammalian Species*, 312, 1–5.
12. **Kunz, T. H., 1982:** *Ecology of Bats.* Plenum Publishing Corporation, New York. 425 pp.
13. **Kunz, T. H., Torrez, E. B. De., Bauer, D., Lobova, T., Fleming, T. H., 2011:** Ecosystem services provided by bats. *Ann. N. Y. Acad. Sci.,* 1223, 1–38, DOI: 10.1111/j.1749-6632.2011.06004.x.
14. **Macchi, M. M., Bruce, J. N., 2004:** Human pineal physiology and functional significance of melatonin. *Front. Neuroendocrinol.,* 25, 177–195. DOI: 10.1016/j.yfrne.2004.08.001.
15. **Nowak, R. M., Walker, E. P., 1994:** *Walker's Bats of the World.* Johns Hopkins University Press, Baltimore, London. 288 pp.

16. **Pevet, P.**, **1977:** On the presence of different populations of pinealocytes in the mammalian pineal gland. *J. Neural Transm.,* 40, 289–304.
17. **Pevet, P., Kappers, J. A., Voûte, A. M.**, **1977:** The pineal gland of nocturnal mammals I. The pinealocytes of the bat (*Nyctalus noctula,* Schreber). *J. Neural Transm.,* 40, 47–68.
18. **Pevet, P., Racey, P. A.**, **1981:** The pineal gland of nocturnal mammals II. The ultrastructure of the pineal gland in the pipistrelle bat (*Pipistrellus pipistrellus* L.): Presence of two populations of pinealocytes. *Cell Tissue Res.,* 216, 253–271.
19. **Ransom, B., Behar, T., Nedergaard, M.**, **2003:** New roles for astrocytes (stars at last). *Trends Neurosci.*, 520–522. DOI: 10.1016/j.tins.2003.08.006.
20. **Stephenson-Jones, M., Floros, O., Robertson, B., Grillner, S.**, **2012:** Evolutionary conservation of the habenular nuclei and their circuitry controlling the dopamine and 5-hydroxytryptophan (5-HT) systems. *PNAS,* 109, 3, 164–173. DOI: 10.1073/pnas.1119348109.
21. **Usende, I. L., Emikpe, B. O., Olopade, J. O.**, **2017:** Heavy metal pollutants in selected organs of African giant rats from three agro-ecological zones of Nigeria: Evidence for their role as an environmental specimen bank. *Environ. Sci. Pollut. Res.,* 24, 28, 22570–22578. DOI: 10.1007/s11356-017-9904-6.
22. **Velasquez, K. M., Molfese, D. L., Salas, R.**, **2014:** The role of the habenula in drug addiction. *Front. Hum. Neurosci.,* 8, March, 1–10. DOI: 10.3389/fnhum.2014.00174.
23. **Voigt, C. C., Kingston, T.**, **2016:** Bats in the anthropocene. In **Voigt, C. C., Kingston, T.**, **(Eds.)**: *Bats in the Anthropocene: Conservation of Bats in a Changing World.* Springer International Publishing, AG Switzerland. 601 pp.
24. **Vollrath, L.**, **1981:** *The Pineal Organ*. Berlin/Heidelberg, Springer Verlag. 668 pp.

Received July 5, 2023
Accepted August 23, 2023