

Reproducibility of facial soft tissue landmarks on facial images captured on a 3D camera

Siti Adibah Othman,* Roshahida Ahmad,† Amir Feisal Merican† and Marhazlinda Jamaludin‡

Department of Paediatric Dentistry and Orthodontics, and Clinical Craniofacial Dentistry Research Group, Faculty of Dentistry, University of Malaya,* Bioinformatics and Biocomputing Division, Institute of Biological Sciences, Faculty of Science, University of Malaya, and Centre of Research for Computational Science and Informatics for Biology, Bioindustry, Environment, Agriculture and Healthcare (CRYSTAL)† and Dental Research and Training Unit, Faculty of Dentistry, University of Malaya,‡ Malaysia

Objective: Fast and non-invasive systems of the three-dimensional (3D) technology are a recent trend in orthodontics. The reproducibility of facial landmarks is important so that 3D facial measurements are accurate and may be applied clinically. The aim of this study is to evaluate the reproducibility of facial soft tissue landmarks using a non-invasive stereo-photogrammetry 3D camera.

Material and methods: Twenty-four soft tissue landmarks on 3D facial images captured using a VECTRA-3D dual module camera system for full face imaging (Canfield Scientific Inc, Fairfield, NJ, USA) were viewed and analysed using Mirror software on 30 adult subjects (15 males and 15 females, in the age range of 20–25 years). The landmarks were identified, recorded and measured twice on each 3D facial image by one examiner after a 2-week interval. Intra-class correlations and paired *t*-test or Wilcoxon Rank test were performed for each landmark to assess intra-examiner reproducibility.

Results: Intra-class correlation coefficients for all 24 landmarks ranged from 0.68 to 0.97, indicating moderate to high reliability and reproducibility of all facial soft tissue landmarks. Paired *t*-tests and Wilcoxon Rank test also revealed that there were no significant differences in all 24 facial soft tissue landmarks measurements ($p = 0.17 - 0.99$).

Conclusion: The results indicated that the reproducibility of identification of landmarks by one operator on facial images captured using a VECTRA-3D camera was acceptable. This device may be useful in treatment planning and may provide accurate information in making clinical decisions. However, it is suggested that further studies on inter-examiner reproducibility should be undertaken.

(Aust Orthod J 2013; 29: 58-65)

Received for publication: September 2012

Accepted: March 2013

Siti Adibah Othman: sitiadibah@um.edu.my; Roshahida Ahmad: roshahida@siswa.um.edu.my; Amir Feisal Merican: merican@um.edu.my; Marhazlinda Jamaludin: marhazlinda@um.edu.my

Introduction

The development of photogrammetry occurred over a century ago, when Aime Laussedat conducted a photographic survey of a small village in Paris. A subsequent course in photographic surveying for rapid reconnaissance was announced, along with the extension of the photographic technique to surveys of buildings and machinery. Photographic surveying expanded to aerial photography and medicine,¹ which

primarily related to the measurement of shape and size of body parts. Thomann and Rivett² conducted an orthodontic investigation into the use of standardised photogrammetric procedures to evaluate facial soft tissue morphology. Several methods are available to facilitate soft tissue evaluation using fast and non-invasive techniques to replace conventional anthropometry. An advanced technology developed to assist orthodontists, maxillofacial surgeons and other surgeons of the head and neck, is a three-dimensional

(3D) surface imaging system.³

The evolution of 3D imaging started in the 1970s after the importance of imaging in analysing craniofacial growth, in recording facial morphology, and in identifying the characteristics of genetic abnormalities, was recognised.^{4,5} It is also necessary and vital that accurate information is gathered in clinical decision making.⁶⁻⁸ Therefore, several types of 3D surface acquisition methods have been developed to fulfill the requirements of imaging for medical treatment. These may be classified into systems related to stereo-photogrammetry, laser scanning, structured light, video imaging, radiation sources, MRI and ultrasound.⁹

The most popular medical 3D surface acquisition system is stereo-photogrammetry,¹⁰ which is fast, non-invasive, produces accurate 3D images and is user-friendly.^{8,11} However, an important focus in craniofacial measurement is the identification of landmarks on scanned images to ensure accuracy and usefulness in identifying facial morphology.¹¹ For this reason, reproducibility studies have been established to determine and ensure captured landmark accuracy.^{8,10,15,16,18,19} The reproducibility of facial landmarks on 3D images has been verified by several studies, most of which have reported acceptable accuracy of facial landmark identification.^{10,12-19}

A VECTRA-3D dual module system for full-face imaging (Canfield Scientific Inc, Fairfield, NJ, USA) is a 3D camera system that may be used to capture facial images in 3D. The reproducibility of this device has not been tested. Therefore, the purpose of the present study was to assess the reproducibility of the VECTRA-3D stereo-photogrammetry acquisition system in capturing various soft tissue landmarks. Information on the reproducibility of the best and worst landmarks used on the 3D facial images was investigated.

Materials and methods

Thirty facial images of Semai people, 15 males and 15 females aged 20 to 25 years, were captured during a research visit to an aboriginal settlement in the west of the Peninsular Malaysia. Ethical approval for this study was obtained from the Research Committee of the Faculty of Dentistry, University of Malaya. Verbal and written consent was also obtained from the participants.



Figure 1. The VECTRA-3D dual module camera system for full-face imaging.

All 3D facial scans were captured using the VECTRA-3D dual module camera system for full-face imaging (Canfield Scientific Inc, Fairfield, NJ, USA) (Figure 1). The VECTRA-3D consisted of six fixed cameras, with two pods connected by a central bracket and mounted onto a tripod. Three high-resolution digital cameras and a speckle texture flash projector were housed in each camera pod. The cameras were calibrated before image capture to ensure image consistency and magnification. Consistency was determined by the measurement of the width of the image alar-base, and subsequent comparison and standardisation with actual size. The calibration procedure facilitated the determination of the position, orientation and imaging characteristics of the cameras.

The subjects were seated 95 cm in front of the camera on a self-adjustable stool. A feature of the Vectra-3D is the incorporation of a live video facility by which the subject's head position was viewed. The live video allowed the determination and accuracy of subject position while ensuring that the subject sat in a natural state. The participants were also instructed to keep their muscles of facial expression relaxed as their images were captured over a capture time of two milliseconds per image. The scanned images were displayed and analysed using the 3D Mirror Software.

Twenty-four landmarks were selected, based on the classic points defined by Farkas²⁰ as the most commonly used in 3D facial imaging studies (Figure 2).¹⁴ One operator identified and manually placed the landmarks on each of the 30 3D facial images and repeated the process after a two week interval. The data obtained from the marked images were entered into a spreadsheet with x , y and z coordinates. Based on

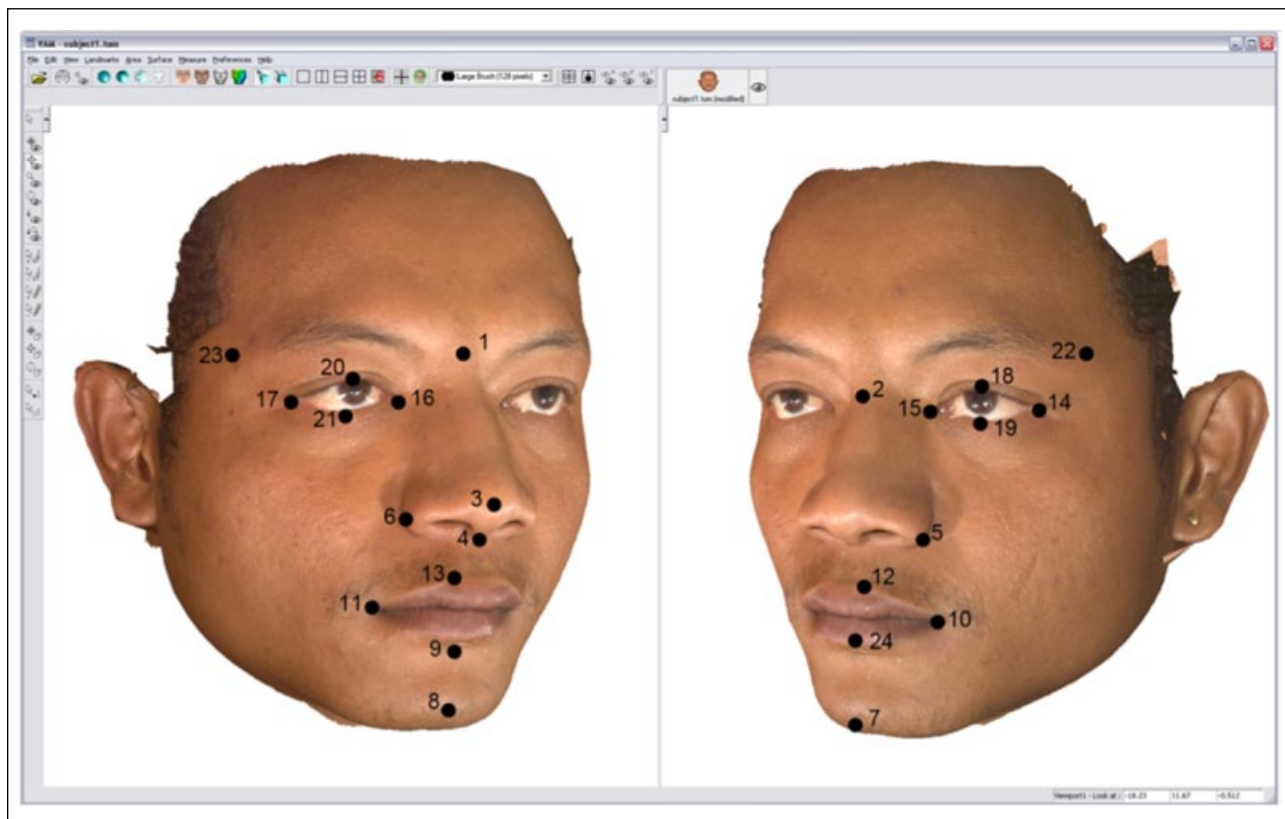


Figure 2. The distribution of facial soft tissue landmarks as superimposed on 3D facial image of a normal subject. These images were captured using the VECTRA-3D system.

Label	Landmarks	Description	Label	Landmarks	Description
1	Glabella (g)	Most prominent midline point between the eyebrows	14	Exocanthion (ex)/L	Point at the left outer commissure of the eye fissure
2	Nasion (n)	Point in the midline of both the nasal and the nasofrontal suture	15	Endocanthion (en)/L	Point at the left inner commissure of the eye fissure
3	Pronasale (prn)	Most protruded point of the apex nasi	16	Endocanthion (en)/R	Point at the right inner commissure of the eye fissure
4	Subnasale (sn)	Midpoint of the angle at the columella base	17	Exocanthion (ex)/R	Point at the right outer commissure of the eye fissure
5	Alare (al)/L	Most lateral point on left alar contour	18	Palpebrale superius (ps)/L	Highest point in the midportion of the free margin of left upper eyelid
6	Alare (al)/R	Most lateral point on right alar contour	19	Palpebrale inferius (pi)/L	Highest point in the midportion of the free margin of left lower eyelid
7	Gnathion (gn)	Lowest median landmark on the lower border of the mandible	20	Palpebrale superius (ps)/R	Highest point in the midportion of the free margin of right upper eyelid
8	Pogonion (pg)	Most anterior midpoint of the chin	21	Palpebrale inferius (pi)/R	Highest point in the midportion of the free margin of right lower eyelid
9	Sublabiale (sl)	Lower border of the lower lip	22	Frontotemporale (ft)/L	Point on left side of the forehead
10	Cheilion (ch)/L	Point located at left labial commissure	23	Frontotemporale (ft)/R	Point on right side of the forehead
11	Cheilion (ch)/R	Point located at right labial commissure	24	Labiale inferius (li)	Midpoint of the lower vermilion line
12	Crista philtri (cph)/L	Point on left elevated margin of the philtrum just above the vermilion line			
13	Crista philtri (cph)/R	Point on right elevated margin of the philtrum just above the vermilion line			

Table I. ICC, mean difference and *p* value to indicate the reproducibility of each landmark.

Label	Landmarks (Repeated measurement N = 30)	ICC	Mean difference (mm)	<i>p</i> value
1	Glabella	0.87	0.23	0.28 b
2	Nasion	0.97	0.10	0.59 a
3	Pronasale	0.96	0.33	0.17 a
4	Subnasale	0.94	0.00	0.99 a
5	Alare / left	0.93	0.27	0.22 a
6	Alare / right	0.90	0.11	0.63 a
7	Gnathion	0.95	0.03	0.93 a
8	Pogonion	0.88	0.29	0.54 b
9	Sublabiale	0.89	0.19	0.62 a
10	Cheilion / left	0.87	0.07	0.79 a
11	Cheilion / right	0.81	0.15	0.67 a
12	Crista philtri / left	0.94	0.13	0.60 a
13	Crista philtri / right	0.93	0.12	0.70 b
14	Exocanthion / left	0.82	0.08	0.63 b
15	Endocanthion / left	0.84	0.36	0.24 a
16	Endocanthion / right	0.81	0.24	0.19 a
17	Exocanthion / right	0.85	0.30	0.45 b
18	Palpebrale superius / left	0.84	0.02	0.92 a
19	Palpebrale inferius / left	0.79	0.04	0.84 a
20	Palpebrale superius / right	0.90	0.08	0.75 a
21	Palpebrale inferius / right	0.68	0.25	0.37 b
22	Frontotemporale / left	0.86	0.72	0.17 a
23	Frontotemporale / right	0.96	0.12	0.72 b
24	Labiale inferius	0.82	0.05	0.80 a

a = Paired *t*-test was performed

b = Wilcoxon Rank test was performed

Level of significance at *p* < 0.05

the spatial coordinates recorded, the distance between three points of the (x_1, y_1, z_1) and (x_2, y_2, z_2) may be computed using the distance formula expressed by the following equation:

$$D = \sqrt{\Delta x^2 + \Delta y^2 + \Delta z^2}$$

where *D* is total distance, Δx is the difference in the *x*-axis, Δy is the difference in the *y*-axis and Δz is the difference in the *z*-axis.

Statistical analysis

The intra-class correlation coefficient test (ICC) was used to determine the reproducibility of the two readings for each of the 24 landmarks on the

30 subjects. To further support the reproducibility of repeated measurement using VECTRA-3D, either a paired *t*-test or a Wilcoxon Rank test was performed for each landmark, based on the normality of the distribution. The statistical tests assisted the determination of significant difference between the first and the second measurements. *P* values less than 0.05 were considered significant. All measurements were analysed using Statistical Package for the Social Sciences (SPSS) version 17.0.

Results

Table I shows the results obtained for intra-examiner reproducibility assessments for the total sample (30

Table II. The distribution of landmark identification using the VECTRA-3D system.

Label	Landmarks (Repeated measurement N = 30)	Mean (SD) mm	Median (IQR) mm
1	Glabella		20.34 (3.91)
2	Nasion	10.70 (3.43)	
3	Pronasale		40.21 (5.41)
4	Subnasale	44.01 (3.04)	
5	Alare / left	42.99 (2.87)	
6	Alare / right	43.68 (2.78)	
7	Gnathion	104.27 (5.01)	
8	Pogonion	93.15 (4.60)	
9	Sublabiale	81.22 (4.19)	
10	Cheilion / left		69.13 (3.47)
11	Cheilion / right		70.48 (2.68)
12	Crista philtri / left	56.62 (3.78)	
13	Crista philtri / right		56.04 (6.51)
14	Exocanthion / left	48.20 (2.71)	
15	Endocanthion / left	49.73 (2.94)	
16	Endocanthion / right		17.05 (2.41)
17	Exocanthion / right		18.14 (3.03)
18	Palpebrale superius / left		33.41 (3.37)
19	Palpebrale inferius / left		34.51(2.20)
20	Palpebrale superius / right	32.73 (2.19)	
21	Palpebrale inferius / right		33.33 (3.02)
22	Frontotemporale / left		57.58 (6.16)
23	Frontotemporale / right		60.22(4.13)
24	Labiale inferius	75.96 (3.76)	

subjects). ICC for all 24 landmarks ranged from 0.68 to 0.97 and indicated moderate to high reliability and reproducibility of all soft tissue landmarks. Additionally, paired *t*-tests and Wilcoxon Rank tests also revealed that there were no significant differences in the identification of all 24 landmarks ($p = 0.17 - 0.99$). Descriptive analysis in Table II shows the distribution of landmark positions on 3D images produced by VECTRA-3D.

Discussion

Non-invasive 3D technology systems have rapidly been developed in dentistry over the last decade.²¹ The use of 3D technology in orthodontics has been directed at pre- and post-treatment assessment of dentoskeletal relationships and facial aesthetics,

auditing orthodontic outcome with regard to soft tissue as well as hard tissues, 3D treatment planning, and 3D soft- and hard-tissue predictions.²¹ This technology may also enable an accurate and reliable assessment of growth as a result of facial change and treatment.¹⁶ Other predicted applications of using 3D technology in orthodontics are the production of 3D-fabricated custom archwires, archiving 3D facial, skeletal, and dental records for in-treatment planning, research and medico-legal purposes.²² Brown and Abbott²³ also suggested that, when extended by morphologic quantification and analysis, 3D imaging provided surgeons, orthodontists, and others dealing with the craniofacial structures, the opportunity to develop new approaches to diagnosis and patient management.

It is important to ensure that the reproducibility of

facial landmarks captured with any 3D technology is accurate and can be applied clinically. Houston²⁴ suggested that if any study using measurements was to be of value, it was imperative that an error analysis was undertaken and reported, and the discipline of undertaking an error analysis should improve the quality of results. Therefore, the present study investigated the reproducibility of various soft tissue landmarks on 3D facial images captured with the VECTRA-3D facial scanner which were analysed using the 3D Mirror software.

The VECTRA-3D facial scanner proved to be quick to use and user-friendly. The images produced by the fixed camera system were considered of good quality even though there were areas of facial surface incompletely captured. This may be a result of subject positioning, or 'noise' on the images, particularly around the eyes and mouth. Therefore, a fixed subject to camera distance and careful subject head position are important to reduce these problems. The Mirror software provided no uniformity of x-axis, y-axis, and z-axis position for analysing the captured images, which posed difficulties during the placement of landmarks. For this reason, the 3D image needs to be positioned according to standardised natural head position so that errors of measurements and calculations between images are avoided. Natural head position has been shown to be clinically reproducible.^{25,26}

Based on the results of the present study, 8 out of the 24 landmarks have an ICC of more than 0.90 (nasion, pronasale, subnasale, left alera, gnathion, right and left crista philtris and right frontotemporale), 14 landmarks between 0.80 and 0.90 (glabella, right alera, pogonian, sublabiale, right and left cheilions, right and left exocanthions, right and left endocanthions, right palpebrale superius, left palpebrale inferius, left frontotemporale and labiale inferius), 1 landmark between 0.70 and 0.80 (left palpebrale inferius) and 1 landmark between 0.60 and 0.70 (right palpebrale inferius). Robert and Richmond²⁷ suggested that an ICC of less than 0.40 was considered low, between 0.40 and 0.75 acceptable, and greater than 0.75 was good. If these guidelines were applied, a low value was only present for the right palberale inferius (ICC = 0.68) defined as the highest point in the midportion of the free margin of the right lower eyelid. However, this value was still within an acceptable range. This finding might be attributed to the area around the eye being ill-defined which may have lead to imprecise

reproducibility of measurements at the time of point identification. The paired *t*-tests and Wilcoxon Rank test also revealed that there were no significant differences in the 24 facial soft tissue landmarks measurements ($p = 0.17 - 0.99$).

Toma et al.,¹⁹ in their study on reproducibility of facial soft tissue landmarks on 3D laser-scanned facial images, also found that palpebrale was the least reproducible landmark on the face. However, it was also found that the superior rather than the inferior part of palpebrale was more affected. It was concluded that the poor reproducibility was due to the difficulty in identifying upper eyelid borders, which, in some images, were affected by computerised processing of the 3D facial images. This resulted in poor mesh production in this area of the face.

The present study concurred with the findings of Toma et al.¹⁹ in that the left palpebrale superius was the second least reproducible landmark (ICC = 0.79). Because of its complex geometry, poor coordinate reproducibility was associated with the eyes, and capture was difficult using a laser-based acquisition system which may affect the computerised mesh processing.¹⁹ This reason may explain the inability to reproduce the landmarks of right and left palpebrale inferius consistently.

In agreement with the findings of McCance et al.^{12,28,29} and Hajeer et al.,¹⁴ the present study determined that the reproducibility of nasion was greatest. McCance et al.,^{12,28,29} in several studies using landmarks to match pre- and post-operative scans, found that 5 landmarks including the left and right medial and lateral canthi and soft tissue nasion, had a high degree of reproducibility. An additional study by Hajeer et al.¹⁴ which investigated landmark identification reproducibility, listed 7 stable points that proved to be highly reliable over time. Nasion was identified as one of the points and suggested as a stable point for superimposition. However, Gwilliam et al.¹⁰ and Toma et al.¹⁹ found that the reproducibility of nasion was relatively poor, based on measurement in the y-axis. The difficulty of placing nasion accurately with the patient in a natural head position in lateral profile was suggested as the likely reason.^{10,19} Hence, good clinical knowledge of natural head position and good manipulation skills in order to move the images to the correct position were required. Failing to achieve this may mean that nasion is placed too high or too low vertically (y-axis).¹⁰

Within limitations and based on the results of the present study, the VECTRA-3D facial scanner was established as a reliable system for recording and measuring facial soft tissue morphology. The VECTRA-3D facial scanner had the advantages of being user-friendly, relatively lightweight, robust and required little time for image acquisition. The images may be captured in any location, typified by the non-clinical setting (aboriginal settlement) required for the present study. However, reproducibility of 3D facial soft tissue landmarks was highly dependent on landmark identification and soft tissue placement, which was carried out during image analysis. The placement or positioning of landmarks could vary between individuals and may only be efficiently performed by experienced operators who are familiar with soft tissue landmarks.³⁰ Additionally, familiarity with the software application used to analyse the images was crucial in order to improve landmark reproducibility.

Conclusions

The reproducibility of identification of landmarks by one operator on facial images captured using the VECTRA-3D camera was acceptable. However, it is suggested that a further study on inter-examiner reproducibility should be undertaken.

Right palpebrale inferius was the least reproducible landmark, while nasion was the most reproducible point.

Acknowledgments

We would like to thank the research team of Aboriginal Studies in Peninsular Malaysia, Faculty of Dentistry, University of Malaya. This work was supported by the University of Malaya Research Grant (RG063/09AFR).

Corresponding author

Associate Professor Dr Siti Adibah Othman
Department of Paediatric Dentistry and Orthodontics
Faculty of Dentistry
University of Malaya
50603 Kuala Lumpur
Malaysia

Email: sitiadibah@um.edu.my

References

- McNeil GT. X-Ray Stereo Photogrammetry. *Photogram Eng* 1966;32:993-1004.
- Von Thomann J, Rivett LJ. Applications of photogrammetry to orthodontics. *Aust Orthod J* 1982;7:162-7.
- Ayoub AF, Siebert P, Moos KF, Wray D, Urquhart C, Niblett TB. A vision-based three-dimensional capture system for maxillofacial assessment and surgical planning. *Br J Oral Maxillofac Surg* 1998;36:353-7.
- Brewster L, Trivedi S, Tuy H, Udupa J. Interactive surgical planning. *IEEE Comp Graphics Applic* 1984;4:31-40.
- Moss JP, Grindrod SR, Linney AD, Arridge SR, James D. A computer system for the interactive planning and prediction of maxillofacial surgery. *Am J Orthod Dentofacial Orthop* 1988;94:469-75.
- Krimmel M, Kluba S, Bacher M, Dietz K, Reinert S. Digital surface photogrammetry for anthropometric analysis of the cleft infant face. *Cleft Palate Craniofac J* 2006;43:350-5.
- Hammond P, Hutton TJ, Allanson JE, Campbell LE, Hennekam R, Holden S et al. 3D analysis of facial morphology. *Am J Med Genet Part A* 2004;126:339-48.
- Winder RJ, Darvann TA, McKnight W, Magee JD, Ramsay-Baggs P. Technical validation of the Di3D stereophotogrammetry surface imaging system. *Br J Oral Maxillofac Surg* 2008;46:33-7.
- Kau CH, Richmond S, Incrapera A, English J, Xia JJ. Three-dimensional surface acquisition systems for the study of facial morphology and their application to maxillofacial surgery. *Int J Med Robot* 2007;3:97-110.
- Gwilliam JR, Cunningham SJ, Hutton T. Reproducibility of soft tissue landmarks on three-dimensional facial scans. *Eur J Orthod* 2006;28:408-15.
- Toma AM, Zhurov A, Playle R, Richmond S. A three-dimensional look for facial differences between males and females in a British-Caucasian sample aged 15½ years old. *Orthod Craniofac Res* 2008;11:180-5.
- McCance AM, Moss JP, Fright WR, James DR, Linney AD. A three-dimensional analysis of bone and soft tissue to bone ratio of movements in 17 Skeletal II patients following orthognathic surgery. *Eur J Orthod* 1993;15:97-106.
- Coward TJ, Watson RM, Scott BJJ. Laser scanning for the identification of repeatable landmarks of the ears and face. *Br J Plast Surg* 1997;50:308-14.
- Hajeer MY, Ayoub AF, Millett DT, Bock M, Siebert JP. Three-dimensional imaging in orthognathic surgery: the clinical application of a new method. *Int J Adult Orthod Orthog Surg* 2002;17:318-30.
- Kusnoto B, Evans CA. Reliability of a 3D surface laser scanner for orthodontic applications. *Am J Orthod Dentofacial Orthop* 2002;122:342-8.
- Kau CH, Richmond S, Zhurov AI, Knox J, Chestnutt I, Hartles F et al. Reliability of measuring facial morphology with a 3-dimensional laser scanning system. *Am J Orthod Dentofacial Orthop* 2005;128:424-30.
- Baik HS, Lee HJ, Lee KJ. A proposal for soft tissue landmarks for craniofacial analysis using 3-dimensional laser scans imaging. *World J Orthod* 2006;7:7-14.
- Muramatsu A, Nawa H, Kimura M, Yoshida K, Maeda M, Katsumata A et al. Reproducibility of maxillofacial anatomic landmarks on 3-dimensional computed tomographic images determined with the 95% confidence ellipse method. *Angle Orthod* 2008;78:396-402.
- Toma AM, Zhurov A, Playle R, Ong E, Richmond S. Reproducibility of facial soft tissue landmarks on 3D laser-scanned facial images. *Orthod Craniofac Res* 2009;12:33-42.
- Farkas LG. *Anthropometry of the head and face*, 2nd edn. Raven Press, New York; 1994:20-6.
- Gor T, Kau CH, English JD, Lee RP, Borbely P. Three-dimensional comparison of facial morphology in white populations in Budapest,

- Hungary, and Houston, Texas. *Am J Orthod Dentofacial Orthop* 2010;137:424-32.
22. Hajeer MY, Millett DT, Ayoub AF, Siebert JP. Application of 3D imaging in orthodontics: part 1. *J Orthod* 2004;31:62-70.
 23. Brown T, Abbott AH. Computer-assisted location of reference points in three dimensions for radiographic cephalometry. *Am J Orthod Dentofacial Orthop* 1989;95:490-8.
 24. Houston WJ. The analysis of errors in orthodontic measurements. *Am J Orthod* 1983;83:382-90.
 25. Solow B, Tallgren A. Natural head position in standing subjects. *Acta Odontol Scand* 1971;29:591-607.
 26. Chiu CS, Clark RK. Reproducibility of natural head position. *J Dent* 1991;19:130-1.
 27. Roberts CT, Richmond S. The design and analysis of reliability studies for the use of epidemiology and audit indices in orthodontics. *Br J Orthod* 1997;24:139-47.
 28. McCance AM, Moss JP, Fright WR, James DR, Linney AD. A three-dimensional analysis of soft and hard tissue changes following bimaxillary orthognathic surgery in Skeletal III patients. *Br J Oral Maxillofac Surg* 1992;30:305-12.
 29. McCance AM, Moss JP, Fright WR, Linney AD. Three-dimensional analysis techniques-Part 3: color-coded system for three-dimensional measurement of bone and ratio of soft tissue to bone: the analysis. *Cleft Palate Craniofac J* 1997;34:52-7.
 30. Miller L, Morris DO, Berry E. Visualizing three-dimensional facial soft tissue changes following orthognathic surgery. *Eur J Orthod* 2007;29:14-20.